

The Mayer - von Rokitansky - Küster - Hauser syndrome (uterus bipartitus solidus rudimentarius cum vagina solida): the development of gynecology through the history of a name

G. GHIRARDINI (*) - L. W. POPP (**)

Summary: A summary of the original descriptions of the Authors who gave the name to the syndrome characterized by absence of uterus and vagina is presented. Through these original descriptions a complete view of the development in gynecology over the last 150 years is offered.

Key words: Gynecology; History; Müllerian anomalies; Vaginal agenesis.

INTRODUCTION

The Mayer-von Rokitansky-Küster-Hauser syndrome (MRKHs) is a known picture important for the understanding of the embryological development of the female genital system⁽¹⁾, fascinating for the therapeutic approach^(2, 3) and of interest from the historical point of view.

Although already known by Avicenna and Albucassis^(2, 4) and first described in contemporary medical literature by Co-

lumbus in 1562⁽⁵⁾, congenital absence of the uterus and vagina became a distinctly known syndrome during the last 150 years. Its name is the summary of the development of our knowledges on this subject and of medical ideas in the last century.

Here we report a brief review of the original descriptions of Mayer, von Rokitansky, Küster and Hauser^(4, 6, 7, 8).

Mayer (1829)

In the paper on "Uterus duplications and their types"⁽⁶⁾, he described as a fourth type of uterus duplication the so-called "uterus bipartitus", presenting a case of an unmarried woman who had died at 53 years. The observations were made at autopsy. The woman showed normal secondary sex characteristics.

Received 20-4-1994 from the

(*) Divisione di Ostetricia e Ginecologia

Ospedale Franchini

Montecchio Emilia (RE), Italy

(**) Klinik Dr. Guth

Hamburg (Germany)

Revised manuscript accepted for publication 6-7-1994.

All rights reserved — No part of this publication may be reproduced or transmitted in any form or by any means, electronic or mechanical, including photocopy, recording, nor any information storage and retrieval system without written permission from the copyright owner.

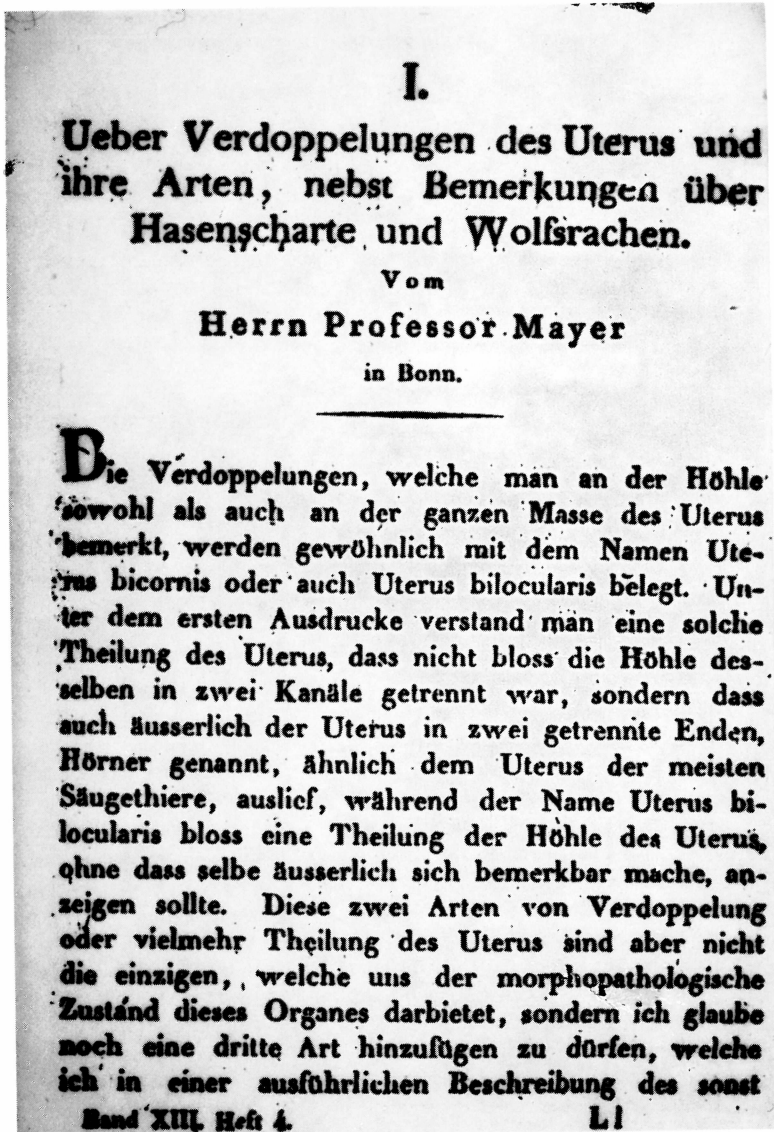


Fig. 1.

The urethral opening was dilated, whereas the vagina was blind ended and very short (one inch). Ovaries and tubes were normal. At a distance of one inch from the right ovary and 1/2 inch from the left two buds were present, the right a little

bigger than the left. The course of the round ligaments was normal. The parenchyma of these two buds was the same as the uterus. Two fibrous ligaments, started from the two buds running between the peritoneal sheets to the vagina (Fig. 1).

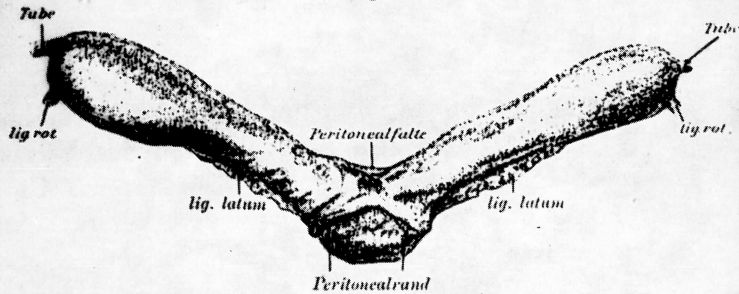
Bett und am 19. Tage die Klinik mit derber, schmaler Bauchnarbe ohne Beschwerden.

Nachrichten über ihr weiteres Befinden haben wir nicht erhalten.

Das Präparat.

Das durch die Operation gewonnene Präparat wurde zwecks genauer Untersuchung sogleich in Formalin fixiert; nach diesem fixierten Objekte wurde die Zeichnung, Fig. 3, angefertigt.

Fig. 3.



Es besteht aus zwei gut unterscheidbaren Abschnitten, einem Mittelstück und zwei in stumpfem Winkel von diesem nach beiden Seiten abgehenden, walzenförmigen, fleischigen Gebilden, welche nach dem äußeren Drittel zu eine kolbige Anschwellung aufweisen.

Die Stümpfe der Ligamenta rotunda und der Tuben sind ohne weiteres erkennbar, aus Gründen der Anschaulichkeit etwas länger gezeichnet, als sie in Wirklichkeit am Präparate sich darstellen, da sie hier durch Klemmen gequetscht sind.

Das Peritoneum überzieht beide Hörner und läßt nur an einer schmalen seitlichen Partie einen Bezirk frei; zwischen beiden Hörnern kurz vor ihrer Vereinigung erhebt es sich zu einer schmalen, etwa 2—3 mm hohen Falte (Folge des Anfassens mit Klemmen?).

Das gemeinsame Mittelstück liegt im Gegensatze dazu zum großen Teil extraperitoneal.

Die Stelle, an welcher das Peritoneum abgetrennt wurde, ist in der Abbildung deutlich erkennbar.

In kurzen Abständen wurden senkrecht zur Längsachse Quer-

Fig. 2.

Rokitansky (1838)

In his paper (7) on uterus duplications he maintained the classification proposed by Mayer. A new case of "uterus bipartitus" like that of Mayer is reported. Rokitansky described the sexual organs of an

unmarried woman (Magdalena Fischer), who had died at 60 years of gastric cancer 10 years previously.

On 30th July 1828 dissection was performed and the genital organs, now under consideration were kept in the Pathology Museum.

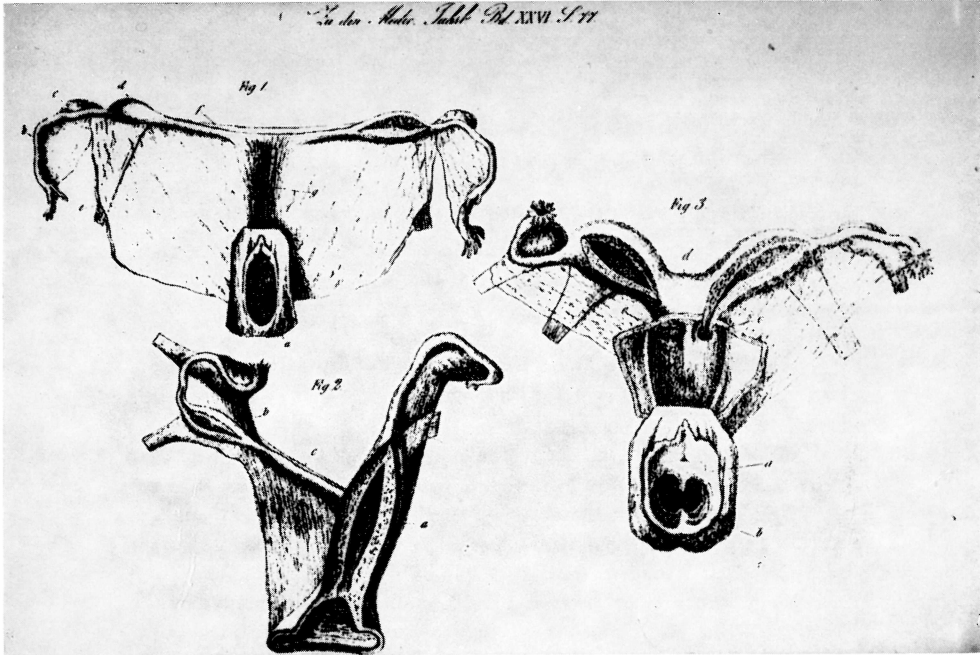


Fig. 3.

The vagina was a dimple of about 1 inch. Ovaries and tubes were normal. Two buds of uterine tissue were present between bladder and rectum. Uterus and vagina were absent. In their place a fibrous bundle was present (Figs. 2, 3).

Küster (1910)

In the paper⁽⁸⁾ "Uterus bipartitus solidus rudimentarius cum vagina solida" Küster first describe a case in a living woman and reviewed the literature. He first considered the symptoms and the problem of surgical therapy. The surgical therapy proposed was limited to the removal of the uterine rudiments with conservation of the ovaries. Surgical therapy of the vaginal absence was not considered. The literature review focussed on the removal of symptoms due to pain at ovulation (Fig. 4).

Hauser (1962)

With the paper⁽⁴⁾ "Das Mayer-Rokitansky-Küster-Hauser-Syndrom. Uterus bipartitus solidus rudimentarius cum vagina solida" published in 1962, Hauser presented a personal review of 21 cases and completed the definition of the syndrome. The paper gives an accurate historical analysis and an accurate definition of the syndrome. Hauser discusses ethiopathogenesis and symptomatology and all the possible clinical aspects: the patient's history, secondary sex characteristics, anatomy of the internal genitals, extragenital symptoms, psychological and sexual aspects. The analysis of the endocrinological picture is also discussed, as well as the possibility of borderline or atypical pictures. The discussion ends with the problem of differential diagnosis and therapy. A complete view of the syndrome is offered.

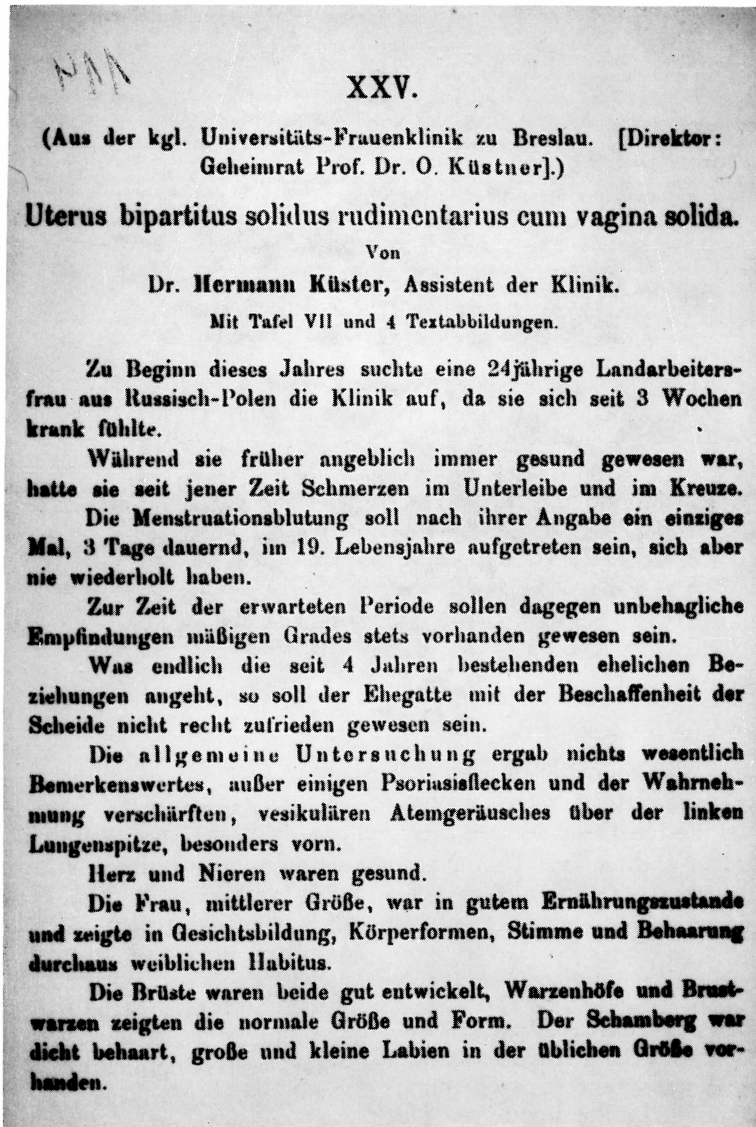


Fig. 4.

Some years later, in 1970, Vecchietti⁽²⁾ in his book on the syndrome, first proposed to add the name of Hauser to the other authors who had given the name to this syndrome.

COMMENT

Through the original descriptions of the authors on overview is given of the development of medical thought and of our knowledge in the last 150 years.

From the first descriptions at autopsy, considering these patients as a matter of curiosity, the interest shifted to the frequency and the symptoms of the syndrome. Thereafter the possible therapeutical approach was developed, up to the surgical approach developed by Vecchietti (2), and more recently, to the laparoscopic surgery (3). This syndrome has gained increasing attention during the past 150 years and the interest continues, both because of its minimal invasive therapy and for the understanding it gives of the embryology of all the müllerian anomalies.

REFERENCES

- 1) Ghirardini G., Tridenti G., Vadora E., La Sala G.B.: "Human reproduction and a D.D.D. (Determination, Differentiation, Development) pathogenetical classification of genital anomalies in phenotypic females". *Acta Europ. Fert.*, 1990, 21, 257.
- 2) Vecchietti G., Ardillo L.: "La sindrome di Rokitansky-Küster-Hauser. Fisiopatologia e clinica dell'aplasia vaginale con corni uterini rudimentali". Soc. Ed. Universo, Roma, 1970.
- 3) Popp L.W., Ghirardini G.: "Creation of a neovagina by pelviscopy". *J. Laparoendosc. Sur.*, 1992, 2, 165.
- 4) Hauser G.A., Schreiner W.E.: "Das Mayer-Rokitansky-Küster Syndrom. Uterus bipartitus solidus rudimentarius cum vagina solida". *Schweiz. Med. Wochenschr.*, 1961, 12, 381.
- 5) Ghirardini G.: "First description of vaginal agenesis". *Am. J. Obst. Gyn.*, 1979, 133, 232.
- 6) Mayer: "Ueber Verdoppelungen des Uterus und ihrer Arten, nebst Bemerkungen über Hasenscharten und Wolfsrachen". *Journal der Chirurgie und Augen-Heilkunde*, 1829, 13, 525.
- 7) von Rokitansky K.: "Ueber die sogenannten Verdoppelungen des Uterus". *Medizinische Jahrbücher des kaiserl. koenigl. oesterreichischen Staates*, 1838, 26, 39.
- 8) Küster H.: "Uterus bipartitus solidus rudimentarius cum vagina solida". *Z. Geburtsh. Gynaek*, 1910, 67, 692.

Address reprint requests to:

G. GHIRARDINI

Ospedale Franchini

42027 Montecchio Emilia (RE), (Italy)