

# Continuous transabdominal drainage of ascites for management of hyperreactio luteinalis with massive ascites

H. Chae<sup>1,\*</sup>

<sup>1</sup>Department of Obstetrics and Gynecology, Research Institute of Clinical Medicine, Chonbuk National University Hospital, Jeonju (Republic of Korea)

## Summary

Hyperreactio luteinalis (HL) is a rare benign condition complicating spontaneous pregnancy, characterized by bilateral enlarged multicystic ovaries associated with high human chorionic gonadotropin (hCG) levels and a hyperandrogenic state. We describe a case of HL presenting with massive ascites at 11 weeks' gestational age. Continuous transabdominal drainage of ascites was performed over 43 days, and a total of 30 liters of ascitic fluid was drained. The patient's condition improved substantially and she had an uneventful pregnancy course. This case report suggests that continuous transabdominal drainage of ascites for management of HL with massive ascites is safe and efficacious.

**Key words:** Hyperreactio luteinalis; Ascites; Transabdominal drainage.

## Introduction

Hyperreactio luteinalis (HL) is a rare condition during spontaneous pregnancy, characterized by multicystic ovarian enlargement associated with high levels of human chorionic gonadotropin and hyperandrogenic state [1-3]. HL is mostly observed in cases with high levels of hCG such as gestational trophoblastic disease, hydrops fetalis, and multiple pregnancies, whereas few cases occur in normal singleton pregnancy [4]. The etiology of this condition is unclear, but it is believed to be caused by increased hCG levels leading to excessive stimulation of the ovaries or by exaggerated ovarian sensitivity to hCG [5]. Although, typically self-limited, enlarged multicystic ovaries associated with HL often require unnecessary surgery because of the symptoms caused by the swelling, concerns about ovarian malignancy, or a combination of these reasons. We report a rare case of HL complicated by massive ascites treated by continuous catheter drainage.

## Case Report

A 32-year-old woman (gravida 1, parity 1) was referred to our department for bilaterally enlarged ovarian masses and ascites at 11 weeks' gestational age. She had previously undergone caesarean section at 36 weeks, due to pre-eclampsia, and delivered a female infant weighing 2,680 g. In this first pregnancy, she also had bilaterally enlarged ovaries measuring 8 cm in diameter.

In the current pregnancy, she presented with severe abdominal discomfort, abdominal distension, and dyspnea. Ultrasound scanning showed an 11-week singleton pregnancy with bilaterally enlarged multicystic ovarian masses, measuring 15.8 × 11.8 cm on the right side and 10.1 ×

8.58 cm on the left side, with ascites (Figure 1). She had conceived both pregnancies spontaneously without fertility treatments.

Laboratory tests revealed normal values of serum electrolytes, white blood cell count, hemoglobin, hematocrit, creatinine, liver enzymes, albumin concentration, but elevated levels of hCG (> 100,000 mIU/mL), Cancer Antigen 125 (2,185 U/mL), and alpha-feto-protein (8.9 ng/mL). Endocrine evaluation showed normal thyroid function (TSH 3.61 mIU/mL, Free T4 16.5 pmol/L), but elevated testosterone, free testosterone, estradiol progesterone levels.

Magnetic resonance imaging (MRI) performed to exclude malignancy showed multiple-thin-walled cysts in bilateral ovaries with ascites. The ascitic fluid was cytologically negative for malignant cells.

After extensive counseling with a gynecologic oncologist, a diagnosis of HL (hyperreactio luteinalis) was made based on a history of previous bilateral enlarged ovaries in the first pregnancy, laboratory, and radiological findings.

The patient had undergone abdominal paracentesis of 9,000 mL before admission. On admission, her blood pressure was 140/90 mmHg with a pulse of 90 beats/min. There was an absence of proteinuria. Conservative management was initiated. The patient's body weight, abdominal girth measurements, fluid input/output, serum electrolytes, renal functions, and ultrasonography were monitored on a daily basis. Laboratory analysis revealed continued normal values of hemoglobin, hematocrit, blood cell counts, liver enzymes, and albumin concentration, but elevated hCG, testosterone, and free testosterone levels. The serial measurements of endocrine parameters performed during her hospital stay are shown in Table 1.

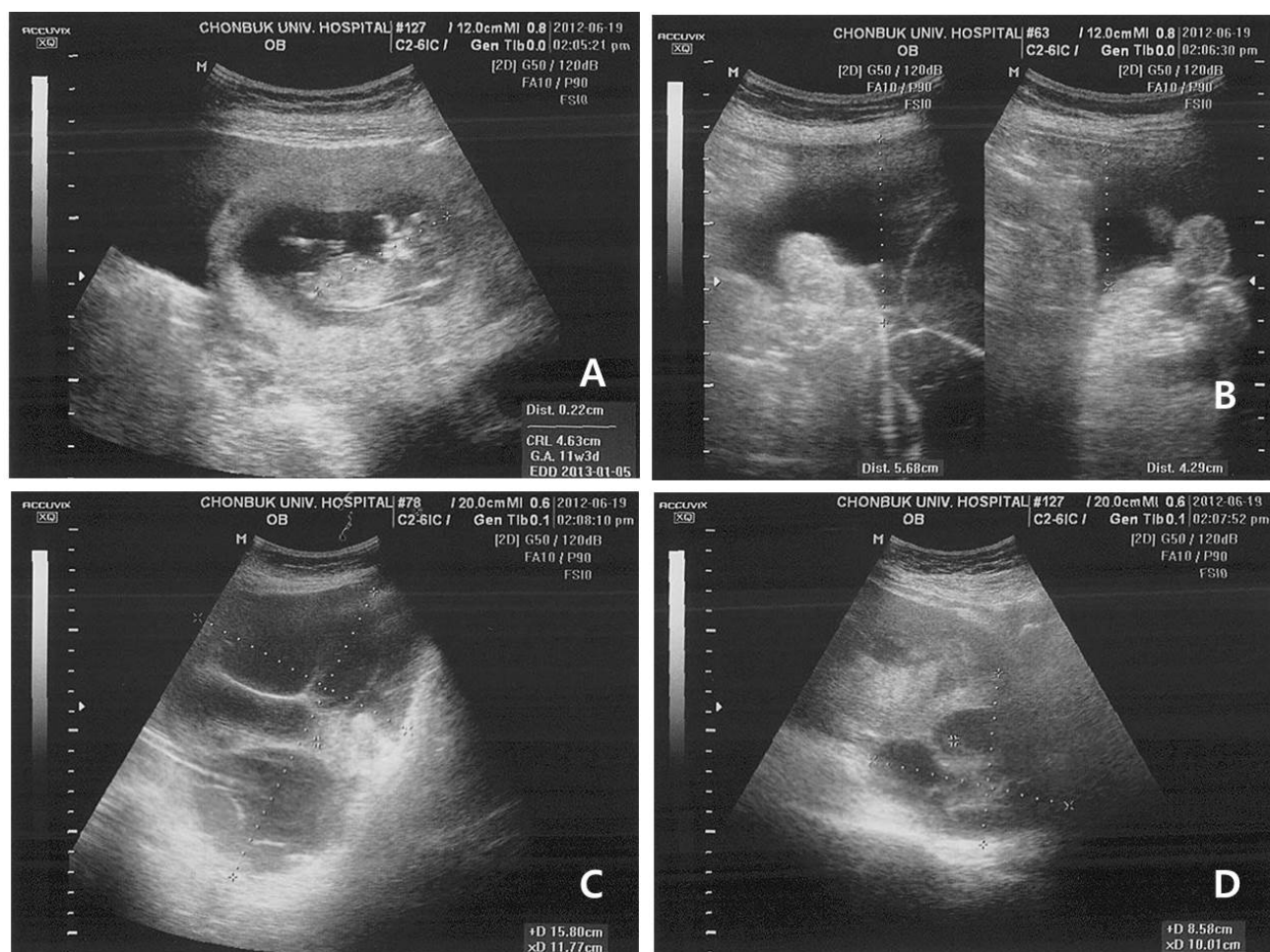


Figure 1. — Ultrasonographic findings of hyperreactio luteinalis. (A) uterus containing an 11-week fetus (B) the presence of free fluid in the paracolic gutters (C) enlarged right ovary (D) enlarged left ovary.

The patient was offered management using the pigtail catheter instead of paracentesis to relieve symptoms. Average fluid drained was 1,000-1,500 mL/day. The ascites significantly decreased at 17 weeks of gestation and the drainage catheter was removed 43 days after drainage. In total, 30 liters of ascites were drained. She was discharged at 18 weeks of gestation in a stable condition. The remaining pregnancy course was normal. Her follow up ultrasound scan showed normal development of the fetus and still showed bilateral enlarged ovaries. Both ovarian volumes decreased slowly. Ultrasound at 30 weeks of gestation revealed the largest cyst of the right ovary measuring 18.2 cm and complete resolution of the cysts of the left ovary. She delivered at another hospital and 2 months after the delivery, she was again seen at our department. She had undergone an elective cesarean section at 36 weeks of gestation and delivered a female neonate weighing 3,100 g. The neonate had showed no signs of virilization.

## Discussion

HL is typically a benign, self-limiting condition. Therefore, except in cases with acute complication (i.e., ovarian

torsion, acute abdominal pain, hemoperitoneum), observation is sufficient since most cases of HL will resolve spontaneously after pregnancy [4-7]. However, the diagnosis of HL is difficult because of its rarity and the suspicion of malignancy and so unnecessary surgical intervention is still frequently performed.

Most of these patients are asymptomatic, and HL is usually noted incidentally at a third trimester ultrasound or during caesarean section [6]. Symptomatic patients may present with maternal virilization, abdominal pain due to ovarian torsion or hemorrhage, and occasionally with ascites (24% of cases) [7]. In some rare cases, HL has been associated with hyperthyroidism, preeclampsia or hemolysis, elevated liver enzymes and low platelets (HELLP) [8].

The differential diagnosis of HL includes ovarian malignancy and ovarian hyperstimulation syndrome (OHSS). HL is characterized by large adnexal masses that consist of multiple thin-walled small theca lutein cysts with a characteristic 'spoke wheel' on ultrasound [7]. MRI may be performed as an additional tool to rule out malignancy, as in our case, but it often adds no information to the data drawn from ultrasound examination [9].

Table 1. — The serial measurements of endocrine parameters during mid-pregnancy in a patient with *Hyperreactio luteinalis*.

Hormone	Normal value	11 week	14 week	16 week	18 week
hCG (mIU/mL)	< 10	> 100,000	> 100,000	83,087.00	60,484.10
Testosterone (ng/mL)	0.08-0.86	5.10	4.31	11.20	8.72
Free testosterone (pg/mL)	0.06-2.57	2.93	4.73	7.10	7.44
Sex hormone binding globulin (nmol/L)	16-120	819	825	702	742

As with our patient, several features of HL, including enlarged multilobulated ovarian cysts, pain, and ascites are also compatible with OHSS which is a complication of ovulation induction. HL can be distinguished from OHSS by occurring in spontaneously conceived pregnancy. Unlike OHSS, which is seen in the first trimester, HL can be seen at any time during pregnancy [6]. Most cases (54%) of HL are noted in the third trimester, with 16% in the peripartum period, and 16% in the first trimester [1, 10]. HL is less acute, has a more uneventful course, and has less severe fluid shifts than OHSS [1, 6]. In contrast, OHSS is associated with more severe symptoms involving acute fluid imbalance, such as massive ascites and hemoconcentration, that impair the natural course of pregnancy [11]. Patients with HL usually present with milder, ascites.

The natural history of HL is resolution post-partum with ovarian volume and androgen concentrations returning to normal by 3 months' post-partum in the majority of cases, and the mainstay of treatment is conservative [8]. Exacerbation of symptoms or the suspicion of malignancy in HL can lead to unnecessary cystectomy or oophorectomy. In addition, it has been proposed that excessive production or release of hCG could lead to adverse pregnancy outcomes, secondary to abnormal placental development, such as pre-eclampsia [7]. Therefore, timely diagnosis minimized the risk of oophorectomy and alerts clinicians to the associated risk of placental insufficiency. Furthermore, knowing that the high androgen levels characteristic of HL will inhibit lactogenesis is important, in order to enlist the assistance of lactation consultants and to implement nipple stimulation strategies to support women who are keen to breastfeed [6].

This patient had presented with dyspnea and marked abdominal distension. Clearly, this patient had driven symptomatic relief from continuous percutaneous drainage despite the progressive growth of the masses. In her previous pregnancy, she had conceived naturally and denied using medication for ovulation induction. At that time, she developed pre-eclampsia and bilateral ovarian enlargement was noted during caesarean section. This information was based only on the patient's own report, which are not always reliable, but this information helped us to select a conservative approach. The patient had not developed pre-eclampsia despite the high hCG level. In addition, recurrence of HL in subsequent pregnancies is rare [3, 8], but in this case recurrent HL was suspected.

In conclusion, we report a case of HL occurred in the early first trimester with symptomatic massive ascites. This case report demonstrates that continuous transabdominal drainage of ascites is efficacious and safe in the management for patient of HL presenting with massive ascites.

### Ethics Approval and Consent to Participate

This study was approved by the Ethics Committee of Chonbuk National University Hospital (file number-2020-06-014). Due to the retrospective design of the study an informed consent is not applicable.

### Acknowledgments

Thank numerous individuals participated in this study.

### Conflict of Interest

The author declares no conflict of interest.

Submitted: March 19, 2020

Accepted: June 01, 2020

Published: December 15, 2020

### References

- [1] Suzuki S.: "Comparison between spontaneous ovarian hyperstimulation syndrome and hyperreactio luteinalis". *Arch. Gynecol. Obstet.*, 2004, 269, 227-229.
- [2] Bradshaw K.D., Santos-Ramos R., Rawlins S.C., Macdonald P.C., Parker C.R.: "Endocrine studies in a pregnancy complicated by ovarian theca lutein cysts and hyperreactio luteinalis". *Obstet. Gynecol.*, 1986, 67, 66S-69S.
- [3] Muechler E.K., Fichter J., Zongrone J.: "Human chorionic gonadotropin, estriol and testosterone changes in two pregnancies with hyperreactio luteinalis". *Am. J. Obstet. Gynecol.*, 1987, 157, 1126-1128.
- [4] Abbas A.M., Talaat E., Gamal E., Michael A., Hanna S., Ali M.N.: "An unusual case of asymptomatic hyperreactio luteinalis present at cesarean section of a spontaneous singleton pregnancy". *Mid. East Fertil. Society J.*, 2017, 22, 160-162.
- [5] Haq A.N.: "Hyperreactio luteinalis associated with pregnancy induced hypertension". *J. Coll. Physicians. Surg. Pak.*, 2010, 20, 137.
- [6] Malinowski A.K., Sen J., Sermer M.: "Hyperreactio luteinalis: maternal and fetal effects". *J. Obstet. Gynaecol. Can.*, 2015, 37, 715-723.
- [7] Cavoretto P., Giorgione V., Sigismondi C., Mangili G., Serafini A., Dallagiovanna C., et al.: "Hyperreactio luteinalis: timely diagnosis minimized the risk of oophorectomy and alerts clinicians to the associated risk of placental insufficiency". *Eur. J. Obstet. Gynecol. Reprod. Biol.*, 2014, 176, 10-16.

- [8] Phelan N., Conway G.S.: "Management of ovarian disease in pregnancy". *Best Pract. Res. Clin. Endocrinol. Metab.*, 2011, 25, 985-992.
- [9] Foulk R.A., Martin M.C., Jerkins G.L., Laros R.K.: "Hyperreactio luteinalis differentiated from severe ovarian hyperstimulation syndrome in a spontaneously conceived pregnancy". *Am. J. Obstet. Gynecol.*, 1997, 176, 1300-1304.
- [10] Van Holsbeke C., Amant F., Veldman J., De Boodt A., Moeman P., Timmerman D.: "Hyperreactio luteinalis is a spontaneously conceived singleton pregnancy". *Ultrasound. Obstet. Gynecol.*, 2009, 33, 371-373.
- [11] Abe T., Ono S., Igarashi M., Akira S., Watanabe A., Takeshita T.: "Conservative management of hyperreactio luteinalis: a case report". *J. Nippon Med. Sch.*, 2011, 78, 241-245.

Corresponding Author:

HEESUK CHAE, M.D.

Department of Obstetrics and Gynecology, Research Institute of Clinical Medicine,

Chonbuk National University Hospital,

20, Geonji-ro, Deokjin-gu,

Jeonju-si, Jeollabuk-do, 561-712 (Republic of Korea)

e-mail: [hschae@jbnu.ac.kr](mailto:hschae@jbnu.ac.kr)