

The accuracy of pulmonary ultrasound in the diagnosis and monitoring of community-acquired pneumonia in women of childbearing age

Jun Wang^{1,*}, Xiao-Dong Zhao², Gang Wang³, Wei-Ming Li¹, Hua Guo¹, Jia-Mei Gou⁴, Guo-Juan Feng², Jing Rao²

¹Department of Respiration, The Sixth People's Hospital of Chengdu, 6100051 Chengdu, China

²Department of Ultrasonography, Jiangyou People's Hospital, 621700 Jiangyou, China

³Medical Service Center of Sichuan Province, 6100051 Chengdu, China

⁴Department of Ultrasonography, The Sixth People's Hospital of Chengdu, 610051 Chengdu, China

*Correspondence: wjz21648@21cn.com (Jun Wang)

DOI: [10.31083/j.ceog.2021.02.2163](https://doi.org/10.31083/j.ceog.2021.02.2163)

This is an open access article under the CC BY 4.0 license (<https://creativecommons.org/licenses/by/4.0/>).

Submitted: 26 May 2020 Revised: 20 October 2020 Accepted: 28 October 2020 Published: 15 April 2021

Objective: To evaluate the accuracy of pulmonary ultrasound in the diagnosis of community-acquired pneumonia (CAP) in women of childbearing age. **Methods:** From June 2014 to July 2018, a total of 275 suspected CAP patients (20–45 years old) were enrolled, including 87 pregnant women and 188 non-pregnant women. All subjects underwent lung ultrasonography at admission, and non-pregnant women also underwent chest X-ray and pulmonary CT examination. CT-positive patients were treated with 7–10 days of anti-infective treatment, and the results of chest X-ray, lung ultrasound, and chest CT were reviewed. Lung consolidation with pneumonia morphological features was evaluated and compared with CT. **Results:** Of the 188 non-pregnant patients, 48 were diagnosed with CAP. Pulmonary ultrasonography, chest X-ray and lung CT diagnosis of CAP were almost identical (kappa coefficient was 0.691, 0.578, respectively). After 48 days of anti-infective treatment in 48 non-pregnant women, the sensitivity, specificity and positive release ratio of pulmonary ultrasound for pneumonia were 10.923 and 13. Among the 87 pregnant women with suspected CAP, 32 were positive in pulmonary ultrasonography, 7 were positive in pulmonary ultrasound after 7–10 days of treatment, and pregnant women with CAP were admitted to the hospital and treated with ultrasound. There was no statistical difference in ultrasound. **Conclusion:** Pulmonary ultrasound can be used as the primary means of diagnosing CAP in women of childbearing age.

Keywords

Pulmonary ultrasound; Community-acquired pneumonia; Women of childbearing age

1. Introduction

Community-acquired pneumonia (CAP) is a common pulmonary infection in women of childbearing age [1]. Especially in pregnant women, CAP not only affects the body of pregnant women, but also affects the fetus [2, 3]. According to the diagnosis guidelines for CAP by the American Thoracic Society, patients can be diagnosed with CAP through clinical manifestations, pulmonary signs, and laboratory examinations. Among them, imaging examination is indispensable

in the diagnosis of CAP. However, there is certain radiation whether it is chest CT or chest radio-graph. It has been reported that it is not recommended for pregnant women to have a larger chest radiograph and chest CT examination [4–6].

Therefore, in the diagnosis of pregnant women with CAP, whether there is a convenient, non-radiative, sensitive and specific imaging examination is particularly important. Color Doppler ultrasound is a convenient and non-radiative influential examination method. Some studies have shown that lung ultrasound is particularly sensitive to pathological changes, including gas, water, consolidation, etc. The ultrasound imaging changes of CAP are mainly pleural rupture and local pleural effusion [4, 7–9]. Community-acquired pneumonia has acoustic characteristics without echo or uneven echo [5, 6, 10–13]. The most typical sign is the bronchial aeration sign. Whether the application of pulmonary ultrasound to CAP diagnosis of pregnant women is better than or consistent with chest X-ray and chest CT examination, can it be used as an alternative to chest X-ray and chest CT diagnosis of CAP in pregnant women? So we designed the following study to explore the accuracy of pulmonary ultrasound in the diagnosis of CAP in women of childbearing age, especially in pregnant women.

2. Materials and methods

This study is an observational study of prospective cross-sectional design with women with suspected CAP in the childbearing age (20–45 years) who were treated in Jiangyou people's Hospital. The study was approved by the Ethic Committee of Jiangyou People's Hospital (No. RM097646). Patients signed a paper-based informed consent before participating in the study. This study strictly enforces the Standards for the Reporting of Diagnostic Accuracy Studies statement [12].

3. Research subjects

Patients aged 20–45 years who were clinically suspected of CAP were included in the study. The diagnosis of patients with suspected CAP includes clinical symptoms and typical signs (auscultation may be wet rales or bronchial breath sounds). The five suspected clinical symptoms of pneumonia included fever, cough, expectoration, chest pain, and dyspnea.

Suspected CAP women of childbearing age were grouped according to pregnancy or not, and they were divided into pregnant women group and non-pregnant women group. On the day of the visit (Day 0), a medical history of all suspected CAP patients, including concomitant diseases and risk factors, was recorded. The clinical symptoms of pneumonia in the suspected patients were evaluated on day 0 and day 7–10 after treatment, and the results of the examinations obtained at that time (mainly auscultation of the lungs) were recorded. All patients with suspected CAP in childbearing age underwent pulmonary ultrasonography on day 0. Non-pregnant women with suspected CAP should also undergo chest X-ray and chest CT examination on the same day. Non-pregnant women with suspected CAP of CT positive test and pregnant women with LUS positive test were given anti-infective treatment for 7–10 days. And then the non-pregnant women diagnosed with CAP, chest X-ray, LUS and chest CT examination and pregnant women with CAP suspected patients were reviewed their LUS. The pregnant patients were diagnosed by ultrasonic examination and sputum culture, and the discharge diagnosis in the discharge medical record was taken as the gold standard.

Exclusion criteria: hospital-acquired pneumonia; confirmed CAP or other disease; interval between lung ultrasound and chest radio-graph or low-dose lung CT over 24 h; sonographers learned chest and chest CT in advance results.

4. Pulmonary ultrasound

Lung ultrasound is performed by a sonographer who has been trained in lung ultrasound for more than two years, and it is done immediately after the patient is admitted to the hospital. At the time of ultrasonography, chest X-ray and chest CT findings were not returned or the sonographer was not informed of chest X-ray and chest CT findings. The ultrasonic instrument used a 3.5–5 MHz convex array probe and a 7.5 MHz linear probe. When the patient took the sitting position to collect the image of the back, the supine position was taken to collect the image of the chest. All lung ultrasound examinations were performed by an experienced sonographer for a systematic examination of all intercostal spaces.

Pulmonary ultrasound assessed the number, location, volume, and presence and absence of pleural fluid. The incidence of necrosis, the incidence of bronchial aeration, and the incidence of pleural effusion were recorded on the day of the visit and on day 7–10.

5. Chest radiography

All patients underwent a posterior anterior or lateral chest radio-graph on the day of the visit, and the test was performed as much as possible on day 7–10. Radiologists were invited to read the film and the ultrasound results of the lungs are blinded.

6. Lung CT

All suspected patients required low-dose CT: chest CT plain scan, 20–40 mA, 120 kV, layer thickness 4 mm (multi-slice spiral CT, effective dose control at 0.4 mSv); or 50 mA, 120 kV, layer thickness 5 mm (linear CT; effective emission control at 1.2 mSv). Radiologists read the film and blinded the lungs and chest radio-graphs. Pulmonary ultrasound diagnosis of pneumonia based on: lung consolidation sign, dynamic bronchial inflation signs and pleural rupture sign. Pneumonia is diagnosed by more than one item.

7. Statistical analysis

The diagnostic value of pulmonary ultrasound and chest radio-graphs were evaluated by calculating sensitivity, specificity, positive predictive value, negative predictive value and likelihood ratio. If the ultrasound and chest radio-graphs were significantly different in sensitivity and specificity, the expansion was evaluated by the McNemar test. The characteristics of the lungs in pregnant and non-maternal lungs were compared and the K values were calculated to evaluate the consistency of pulmonary ultrasound, chest X-ray and chest CT findings. All of the above calculations were done using SPSS statistical software (version 17.0).

8. Results

Between June 2014 and July 2018, a total of 331 patients were enrolled. A total of 36 patients were excluded, 8 of which were due to refusal to enroll, and 28 were due to incomplete data, loss of blindness, and loss of follow-up. The remaining 275 patients were examined and treated according to doctor's advice. There were 188 non-pregnant women with suspected CAP who underwent chest X-ray, pulmonary ultrasound and chest CT on the day of admission. Among them, 165 were chest radio-graphs, 23 were chest radio-graphs, 74 were color ultrasound positive, 114 were color ultrasound negative and 140 were chest CT negative. 48 cases of chest CT positive, chest CT positive patients after treatment for 7–10 days, chest X-ray, color Doppler ultrasound and CT, including 44 cases of chest radio-graphs, 4 cases of positive. There were 33 cases of lung ultrasound negative, 15 cases of positive line, 12 cases of chest CT, and 36 cases of positive. 87 pregnant women with CAP suspected patients underwent lung color Doppler ultrasound examination on the day of admission, including 32 cases were positive and 55 cases were negative. Those who were positive were treated with color Doppler ultrasound after 7–10 days of anti-infective treatment, and 7 cases were positive and 25 cases were negative (Fig. 1).

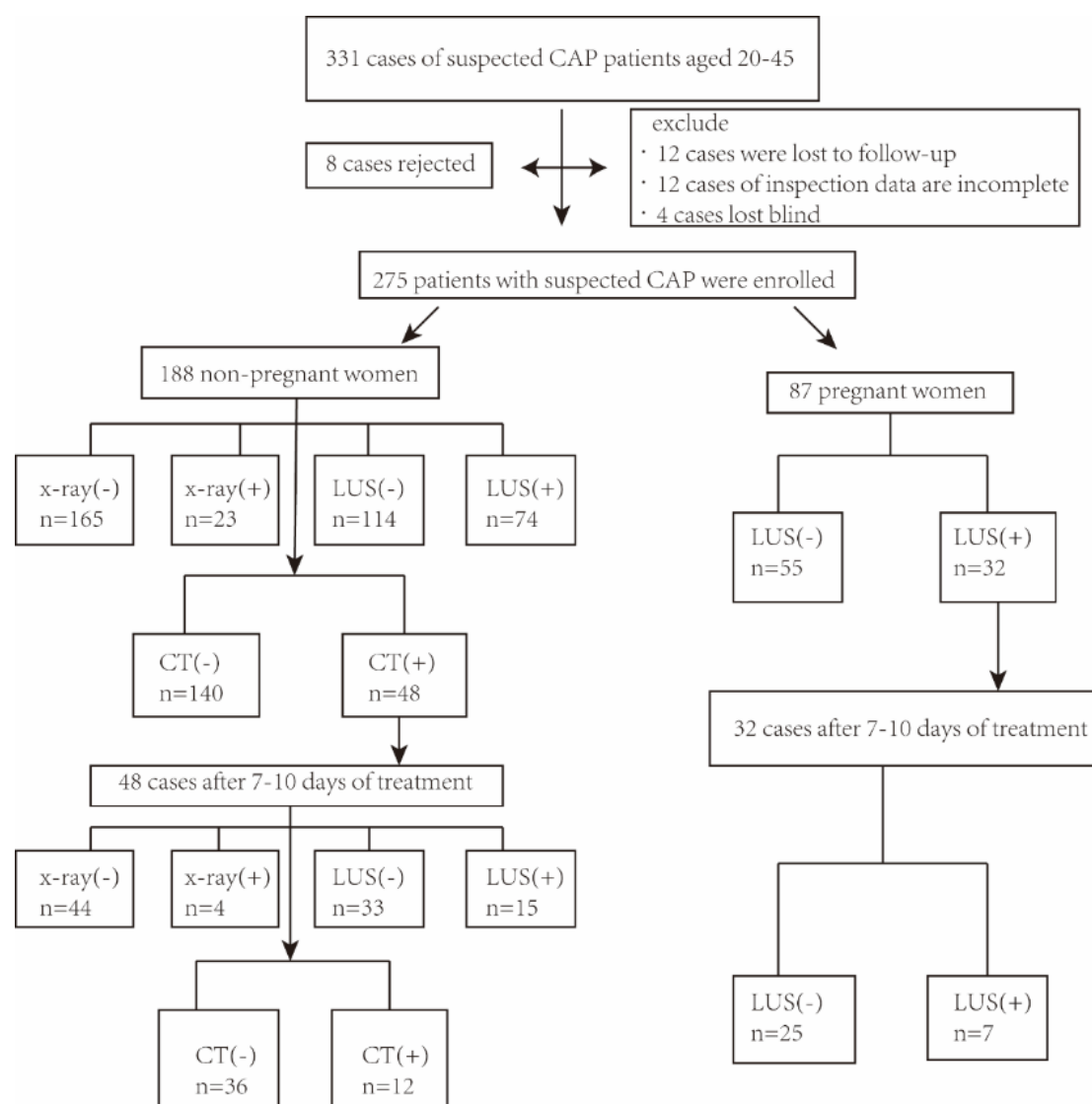


Fig. 1. Treated with color Doppler ultrasound after 7–10 days of anti-infective treatment.

9. General characteristics of patients

The age of the patients was 20–45 years. The general characteristics of patients are shown in Table 1.

10. Main results

Chest CT was used as the standard for the diagnosis of CAP. At the time of initial diagnosis, 188 cases of suspected CAP were found in non-pregnant women, 74 cases were positive in lung ultrasound, and 114 cases were negative. The accuracy of pulmonary ultrasound in the diagnosis of community-acquired pneumonia was 87.9%. The sensitivity of pulmonary ultrasound to community-acquired pneumonia was 100%, the specificity was 84.34%, the positive likelihood ratio was 6.39, and the positive predictive value was 0.65. The predicted value is 1. Patients diagnosed with CAP were examined for lung color Doppler ultrasound and chest CT after 7–10 days of anti-infective treatment. The patient's lung ultrasound was positive in 15 cases and negative in 33

cases. The accuracy of pulmonary ultrasound in the diagnosis of community-acquired pneumonia was 94.12%, and the sensitivity of pulmonary ultrasound to community-acquired pneumonia was 100% and the specificity was 92.31%. The positive likelihood ratio was 13, and the positive predictive value was 0.8 and the negative predictive value was 1.

Compared with pulmonary ultrasound, 23 cases of pneumonia were diagnosed by chest radiography at the time of initial diagnosis, and no abnormalities were found in 165 suspected patients. The accuracy of chest radiography in the diagnosis of community-acquired pneumonia was 88.26%. The sensitivity of chest radiography for community-acquired pneumonia was 65.75%, specificity was 100%, negative likelihood ratio was 2.92, positive predictive value was 1, and negative predictive value was 0.85. Patients diagnosed with CAP were treated with chest X-ray and chest CT after 7–10 days of anti-infective treatment. The patient's chest radiograph was positive in 4 cases and negative in 44 cases. The accu-

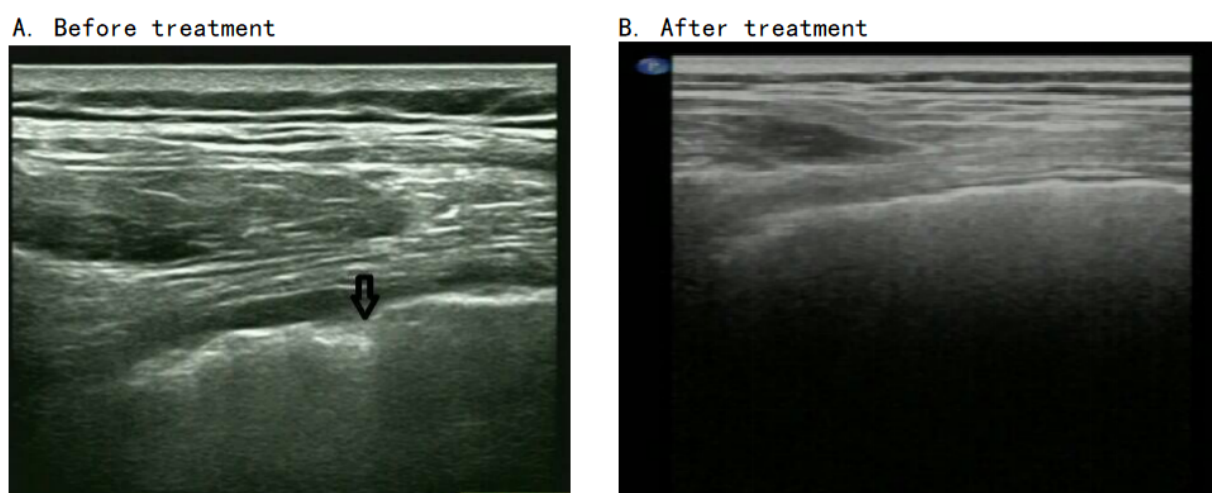


Fig. 2. Images before and after treatment. (A) Before treatment. (B) After treatment.

Table 1. General characteristics of patients.

Characteristic	Non pregnant woman (n = 188)	Pregnant woman (n = 87)
Age, y	28	27
Inpatients	48 (25.53%)	32 (36.78%)
Symptoms		
Cough	172 (91.49%)	78 (89.66%)
Purulent sputum	46 (24.47%)	23 (26.44%)
Dyspnea	2 (1.07%)	1 (1.15%)
Thoracic pain	21 (11.17%)	9 (10.34%)
Fever	32 (17.02%)	16 (18.39%)
Signs		
Wet rales	40 (21.28%)	21 (24.13%)
Comorbidity and risk factors		
COPD	2 (1.06%)	0
Cardiac failure	0	0
Smoking	4 (2.13%)	0
Alcoholism	0	0

racy of chest radiography for community-acquired pneumonia was 85.71%, and the sensitivity of chest radiography for community-acquired pneumonia was 60% and specificity was 100%. The negative likelihood ratio was 2.5, the positive predictive value was 1, and the negative predictive value was 0.82 (Table 2).

Table 2. Diagnostic accuracy of pulmonary ultrasound and chest radio-graph with chest CT as the gold standard.

Classification		Sensitivity	Specificity	PPV	NPV	PLR	NLR
0 day	LUS	1	0.843	0.649	1	6.385	-
	X-ray	0.658	1	1	0.848	-	2.92
7–10 day	LUS	1	0.923	0.8	1	13	-
	X-ray	0.6	1	1	0.818	-	2.5

Chest CT in 188 patients were analyzed. In the 188 suspected patients, the sensitivity of lung ultrasound (100%) was higher than that of chest radio-graphs (65.75%), and the specificity of chest radio-graph was better than that of lung ultrasound (ultrasound: 84.33%; Chest X-ray: 100%).

Compared with chest X-ray results, 25 patients who were diagnosed by pulmonary ultrasound were missed by chest radiography at the time of initial diagnosis, and 26 patients who were excluded by chest X-ray were misdiagnosed by lung ultrasound. Calculate the k value as 0.691, 0.578. Ultrasound, chest radio-graph, and chest CT were reviewed in 48 patients diagnosed with CAP by chest CT. A total of 37 patients with consistent results were found in 33 patients: none of the 33 patients had abnormalities detected; 4 patients had abnormal signs. At the time of the follow-up, 8 patients diagnosed by pulmonary ultrasound were missed by the chest radio-graph, and 3 patients who were excluded by chest X-ray were misdiagnosed by lung ultrasound. Calculate the k value as 0.895, 0.425.

Table 3. The median value of Non-pregnant women's lung lesions in the long axis and short axis.

Days	Long axis	Short axis
LUS (0 day)	24.5 mm	24 mm
LUS (7–10 days later)	9.5 mm	5.5 mm

At the time of initial diagnosis, 87 patients with suspected CAP in pregnant women had 32 cases of pulmonary ultrasound positive and 55 cases of negative (Fig. 2). Suspected patients with ultrasound-positive CAP were examined for lung color Doppler ultrasound after 7–10 days of anti-infective treatment. The patient's lung ultrasound was positive in 7 cases and negative in 25 cases. In the case of non-pregnant women (87 pregnant women), at least 1 positive consolidation was found in the lung ultrasound. There are positive

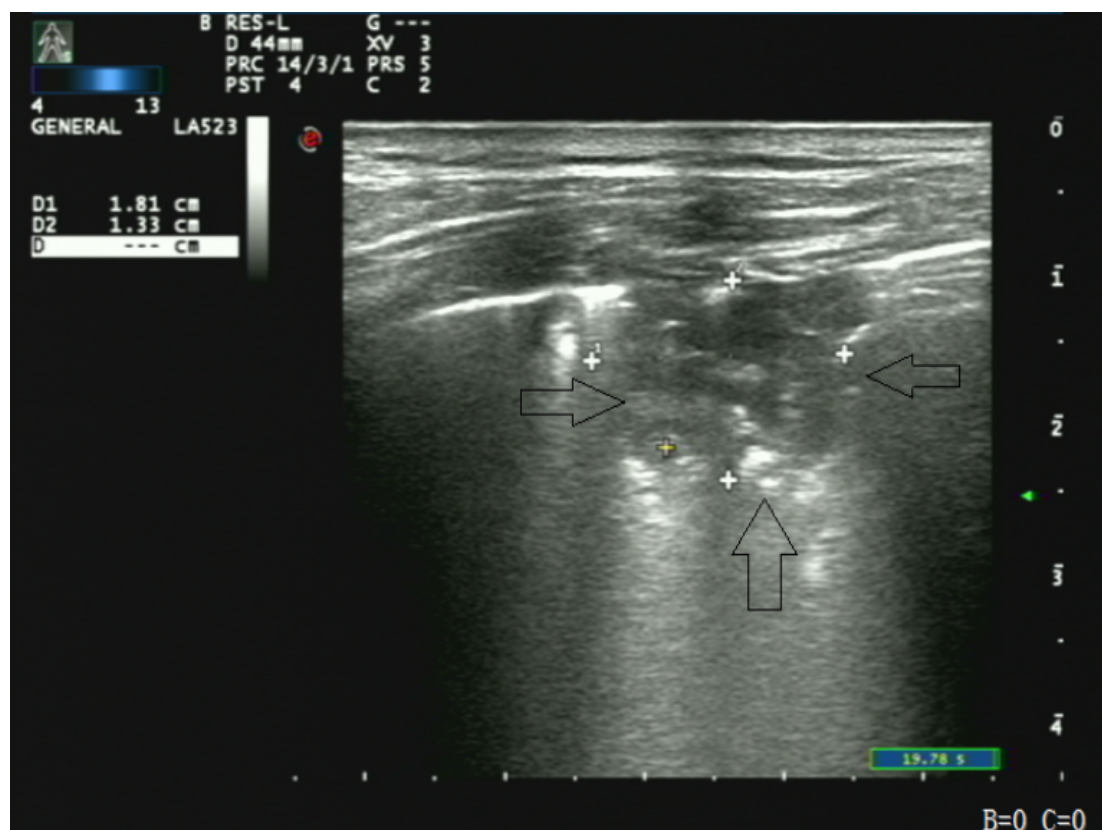


Fig. 3. Images of lung consolidation and bronchial aeration.

findings on the chest radio-graph, and there are also positive findings on chest CT. Pulmonary ultrasound in patients (3.1%) showed false positive results. The patient's lung ultrasound showed a false negative result. The median area of lesion surface area in non-pregnant patients was 5.88 cm [2], and the median depth was 2 cm. There is a bronchial aeration sign in only 20.21% patients (Fig. 3). There is a bronchial filling sign. What is the median area of lesion surface area in pregnant women 5.76 cm [2]. There is a bronchial aeration sign in only 20.21% patients (Fig. 2). There is a bronchial filling sign. After anti-infective treatment in CAP or LUS+ pregnant woman, the median number of symptoms and signs were diagnosed at the time of initial diagnosis. It can also be confirmed by pulmonary ultrasonography (Table 3). On the 7th–10th day after anti-infection, the proportion of non-patients with bronchial aeration sign from the time of initial diagnosis 20.21% reduced to 14.58%, pregnant women from the time of initial diagnosis 24.14% reduced to 6.25%, non-pregnant lung lesion area from 5.88 cm [2] reduced to 0.52 cm [2]; the area of lung lesions in pregnant women from 5.76 cm [2] reduced to 0.55 cm [2]. All of the above lung ultrasound test data are recorded (Table 4).

In pregnant women and non-pregnant women, a total of lung areas in pregnant women showed positive lung consolidation results in the lungs. On average, each patient had a lung area, and non-pregnant women had a total of lung areas. Ultrasound in the lungs showed positive lung consoli-

Table 4. The median value of pregnant women's lung lesions lung lesions in the long axis and short axis.

Days	Long axis	Short axis
LUS (0 day)	24 mm	24 mm
LUS (7–10 days later)	8.5 mm	6.5 mm

dation results, with an average of one lung area per patient. The diagnostic accuracy and diagnostic value of pulmonary ultrasound in different lung regions were shown in Fig. 4 and Table 5. The characteristics of pregnant women and non-pregnant women in different lung areas were shown in Table 6.

11. Discussion

Clinical diagnosis of community-acquired pneumonia often requires chest X-ray or chest CT to diagnose, and chest CT is the gold standard for the diagnosis of community-acquired pneumonia. However, both chest X-ray and chest CT have radiation exposure and cannot be used for the diagnosis of community-acquired pneumonia in pregnant women. Ultrasound in the lungs is non-radiative, easy to operate, non-invasive, and many studies have shown that the ultrasound imaging of gas and liquid in lung ultrasound is very accurate. Researchers have also evaluated lung-acquired ultrasound in children and adults with community-acquired pneumonia and found that pulmonary ultrasound is consis-

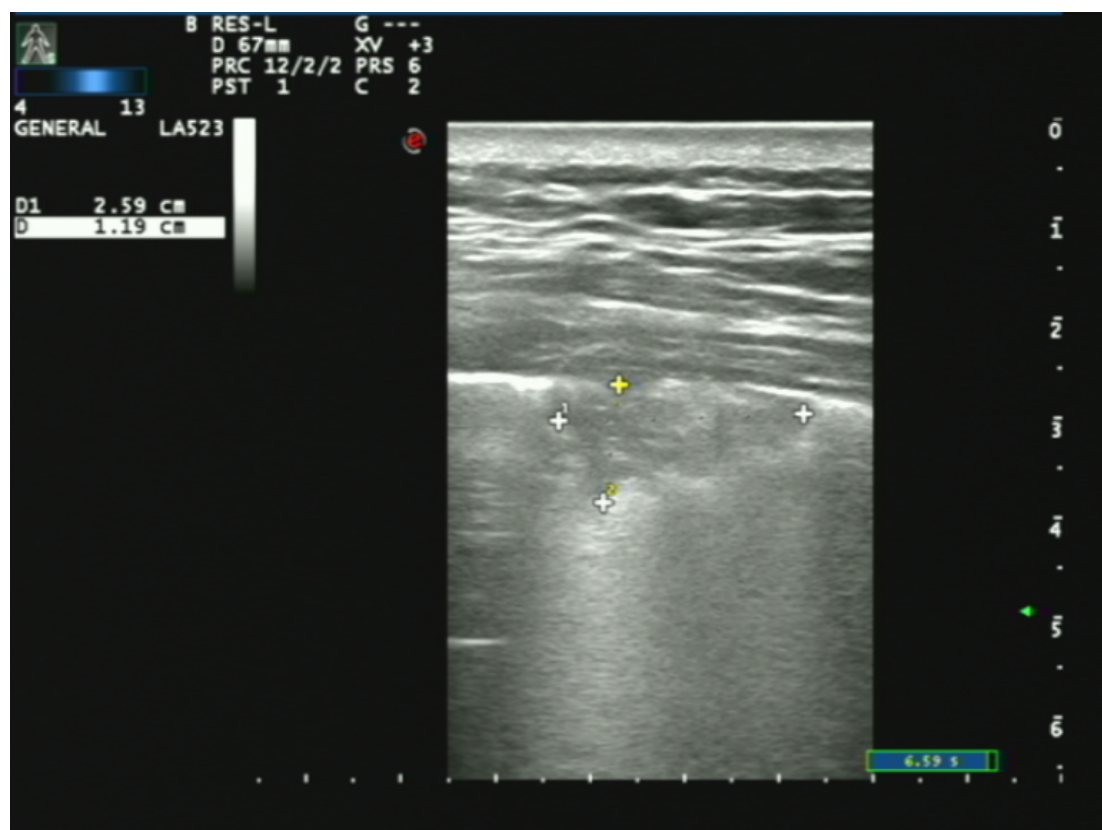


Fig. 4. Image reviewed after half a month.

tent with chest radiography in the diagnosis of community-acquired pneumonia [9]. However, there have been no reports on the use of pulmonary ultrasound in community-acquired pneumonia in pregnant women. When diagnosing a disease, the vast majority use a likelihood ratio greater than 10 or less than 0.01 to confirm or exclude [13]. In our study, we divided suspected CAP women of childbearing age into two groups, the pregnant group and the non-pregnant group. Sensitivity was determined by calculating sensitivity, specificity, positive likelihood ratio, negative release ratio, positive predictive value, and negative predictive value for lung ultrasound in women with non-pregnant women of childbearing age. Studies have shown that the sensitivity of lung ultrasound is significantly higher than that of chest radio-graphs. The specificity of chest radio-graphs is superior to that of lung ultrasound. The positive likelihood ratio at the initial referral is 6.39, 13 respectively. It is suggested that pulmonary ultrasound is superior to the initial diagnosis in the prognosis of CAP in non-pregnant women of childbearing age. At the time of initial diagnosis, 25 patients diagnosed by pulmonary ultrasound were missed by chest radio-graphs, and 26 patients who were excluded by chest X-ray were misdiagnosed by lung ultrasound. Forty-eight patients who were diagnosed with CAP by chest CT were examined with ultrasound. The chest radio-graph and chest CT were consistent with 37 patients, and 33 patients were not detected abnormally; 4 patients were found to have abnormal signs in

8 cases. Patients diagnosed by pulmonary ultrasound were missed by chest radio-graphs, and 3 patients who were excluded by chest X-ray were misdiagnosed by lung ultrasound.

Pulmonary ultrasound can also be used as a means of detecting CAP consolidation in women of childbearing age. Reissig A *et al.* found that the mean volume of lung consolidation in the lungs after 10 days of follow-up was 41.31 cm² and 11.84 cm², respectively [13]. Caiulo *et al.* reviewed the lung consolidation size reduction and even complete remission in 91.6% of patients with pulmonary ultrasound after 3–6 days. It can be speculated that the rate of decline in lung consolidation size (or volume calculation) can be used to assess efficacy. We also explored CAP consolidation in women of childbearing age, non-pregnant group on day 1, 7–10. The median short axis of the long axis is 24.5, 24, 9.5, 5.5. On the first day of the pregnant women group, the median short axis of the 7–10 days long axis was 24, 24, 8.5, 6.5. There was no significant difference between the pregnant women group and the non-pregnant women group. Compared with adult CAP, there was no significant difference in the volumetric variation of the pregnant women group.

Ho found bronchial aeration in 93.7% of children with socially acquired pneumonia. The results of bronchial aeration in adults with CAP in Reissig A. were 70%–97%. We found that only 24.14% of newly diagnosed pregnant women with bronchoacoacia, and Iuri *et al.* revealed that 10/28 (36.3%) of the children hospitalized for emergency pneumonia were

Table 5. Diagnostic accuracy of pulmonary ultrasound and chest radio-graphs with chest CT as the gold standard.

Partition	Sensitivity	Specificity	PPV	NPV	PLR	NLR
Anterior and posterior upper chest of LUS	1	0.954	0.714	1	22	-
Anterior and posterior lower chest of LUS	1	0.959	0.781	1	24.29	-
Right upper chest of LUS	1	0.974	0.167	1	38.4	-
Left lower chest of LUS	1	0.969	0.25	1	32	-
Lung upper lobe of X-ray	0.4	1	1	0.938	-	1.667
Lung middle lobe of X-ray	0.333	1	1	0.979	-	1.5
Lung low lobe of X-ray	0.710	1	1	0.949	-	3.444

Note: LUS, pulmonary ultrasound; PPV, positive predictive value; NPV, negative predictive value; PLR, positive likelihood ratio; NLR, negative likelihood ratio.

Table 6. The characteristics of ultrasound in different lung regions of pregnant women and non-pregnant women.

Clinical, sonographic, and laboratory finding	Non pregnant woman		Pregnant woman	
	Day 0 (n = 188)	Days 7–10 (n = 48)	Day 0 (n = 87)	Days 7–10 (n = 32)
Patients with LUS-detected lesions	74 (39.36%)	15 (31.25%)	32 (36.78%)	7 (21.88%)
Location of pneumonic lesions				
On right side	26 (13.83%)	6 (12.5%)	13 (14.94%)	2 (6.25%)
On left side	31 (16.49%)	7 (14.58%)	14 (16.09%)	3 (9.38%)
On both sides	17 (9.04%)	2 (4.17%)	4 (4.60%)	1 (3.13%)
Further sonographical features				
Positive air bronchogram	38 (20.21%)	7 (14.58%)	21 (24.14%)	2 (6.25%)
Pleural rupture	29 (15.43%)	6 (12.5%)	8 (9.20%)	3 (9.38%)
Local B line	4 (2.13%)	0	1 (1.15%)	0
Evidence of pleural effusion				
On left side	16 (8.51%)	3 (6.25%)	9 (10.34%)	2 (6.25%)
On right side	13 (6.91%)	2 (4.17%)	6 (6.90%)	1 (3.13%)
On both sides	19 (10.11%)	5 (10.42%)	13 (14.94%)	3 (9.38%)

found to have bronchial aeration [14]. These differences may indicate a consolidation of the lung, and the bronchial aeration sign is a multivariate.

In our experiments, we found that a total of 35 lungs in pregnant women showed positive lung consolidation results in the lungs, with an average of 1.09 lungs per patient. A total of 91 lungs in non-pregnant pregnant women showed positive lungs in the lungs. The results of consolidation showed an average of 1.23 lungs per patient. Reissig A, *et al.* found that adult CAP areas showed positive lung consolidation results in lung ultrasound, on average per patient. In the lung area, pregnant women's CAP is compared with adult CAP.

Moreover, pleural rupture is one of the criteria for pneumonia. Pleural effusion is only a concomitant manifestation, not a standard. It has been reported that more than three B lines can be used as signs of pneumonia. We found that the error of the results was large, and the B line was not taken as the standard. It is also possible that more than three b-lines are not included, resulting in the decrease of specificity of our results.

12. Conclusions

This study calculated the sensitivity, specificity, positive predictive value, negative predictive value, negative release ratio, and positive release ratio of CAP in patients with childbearing age, and compared with the value of the chest X-

ray. These results indicated that pulmonary ultrasound can be used as the primary means of diagnosing CAP in women of childbearing age. In summary, pulmonary color Doppler ultrasound can be used as an effective and convenient imaging method for diagnosing CAP, and it is an important means of diagnosis and treatment for CAP diagnosis in pregnant women.

Abbreviations

CAP, Community-acquired pneumonia; LUS, Lung ultrasound.

Author contributions

JW, XZ and GW: conceptualization, investigation, analysis. WL, HG and JG: investigation, analysis. GF and JR: manuscript preparation.

Ethics approval and consent to participate

All subjects gave their informed consent for inclusion before they participated in the study. The study was conducted in accordance with the Declaration of Helsinki, and the protocol was approved by the Ethics Committee of Jiangyou People's Hospital (approval number No. RM097646).

Acknowledgment

Thanks to all the peer reviewers for their opinions and suggestions.

Funding

This research received no external funding.

Conflict of interest

The authors declare no conflict of interest.

References

- [1] Bertolini G, Rossi C, Crespi D, Finazzi S, Morandotti M, Rossi S, *et al.* Is influenza a(H1N1) pneumonia more severe than other community-acquired pneumonias? Results of the GiViTI survey of 155 Italian ICUs. *Intensive Care Medicine.* 2011; 37: 1746–1755.
- [2] Buonsenso D, Raffaelli F, Tamburrini E, Biasucci DG, Salvi S, Smargiassi A, *et al.* Clinical role of lung ultrasound for diagnosis and monitoring of COVID-19 pneumonia in pregnant women. *Ultrasound in Obstetrics & Gynecology.* 2020; 56: 106–109.
- [3] Inchingolo R, Smargiassi A, Moro F, Buonsenso D, Salvi S, Del Giacomio P, *et al.* The diagnosis of pneumonia in a pregnant woman with coronavirus disease 2019 using maternal lung ultrasound. *American Journal of Obstetrics and Gynecology.* 2020; 223: 9–11.
- [4] Liu J, Wang Y, Fu W, Yang C, Huang J. Diagnosis of neonatal transient tachypnea and its differentiation from respiratory distress syndrome using lung ultrasound. *Medicine.* 2015; 93: e197.
- [5] Miao Y, Yu J, Ao Y, Zheng Z, Gong X, Leung KKM. Diagnostic values of 3 methods for evaluating meniscal healing status after meniscal repair. *The American Journal of Sports Medicine.* 2011; 39: 735–742.
- [6] Nazerian P, Volpicelli G, Vanni S, Gigli C, Betti L, Bartolucci M, *et al.* Accuracy of lung ultrasound for the diagnosis of consolidations when compared to chest computed tomography. *The American Journal of Emergency Medicine.* 2015; 33: 620–625.
- [7] Habib SF, Mukhtar AM, Abdelreheem HM, Khorshied MM, El sayed R, Hafez MH, *et al.* Diagnostic values of CD64, C-reactive protein and procalcitonin in ventilator-associated pneumonia in adult trauma patients: a pilot study. *Clinical Chemistry and Laboratory Medicine (CCLM).* 2016; 54: 889–895.
- [8] Jeong S, Park Y, Cho Y, Kim YR, Kim H. Diagnostic values of urine CYFRA21-1, NMP22, UBC, and FDP for the detection of bladder cancer. *Clinica Chimica Acta.* 2012; 414: 93–100.
- [9] Karlovsek MZ. Diagnostic values of combined glucose and lactate values in cerebrospinal fluid and vitreous humour—our experiences. *Forensic Science International.* 2004; 146: S19–S23.
- [10] Pagano A, Numis FG, Visone G, Pirozzi C, Masarone M, Olibet M, *et al.* Lung ultrasound for diagnosis of pneumonia in emergency department. *Internal and Emergency Medicine.* 2015; 10: 851–854.
- [11] Peters PJ, Westheimer E, Cohen S, Hightow-Weidman LB, Moss N, Tsoi B, *et al.* Screening yield of HIV antigen/antibody combination and pooled HIV RNA testing for acute HIV infection in a high-prevalence population. *Journal of the American Medical Association.* 2016; 315: 682–690.
- [12] Reali F, Sferrazza Papa GF, Carlucci P, Fracasso P, Di Marco F, Mandelli M, *et al.* Can lung ultrasound replace chest radiography for the diagnosis of pneumonia in hospitalized children? *Respiration.* 2015; 88: 112–115.
- [13] Reissig A, Copetti R, Mathis G, Mempel C, Schuler A, Zechner P, *et al.* Lung ultrasound in the diagnosis and follow-up of community-acquired pneumonia. *Chest.* 2012; 142: 965–972.
- [14] Shah VP, Tunik MG, Tsung JW. Prospective evaluation of point-of-care ultrasonography for the diagnosis of pneumonia in children and young adults. *JAMA Pediatrics.* 2013; 167: 119–125.