

Can high transverse skin incision (Modified Maylard) be a new alternative in placenta accreta spectrum management with cesarean hysterectomy?

Eren Akbaba^{1,*} ¹Department of Obstetrics and Gynecology, Faculty of Medicine, Muğla Sıtkı Koçman University, 48000 Menteşe/Muğla, Turkey*Correspondence: erenakbaba@mu.edu.tr (Eren Akbaba)DOI: [10.31083/j.ceog.2021.03.2541](https://doi.org/10.31083/j.ceog.2021.03.2541)This is an open access article under the CC BY 4.0 license (<https://creativecommons.org/licenses/by/4.0/>).

Submitted: 21 February 2021 Revised: 15 March 2021 Accepted: 26 March 2021 Published: 15 June 2021

Background: Assess optimal surgical management of cases with placenta accreta spectrum (PAS) disorder. **Methods:** This was a retrospective study conducted between January 2012 and November 2020. Two alternative types of incision were performed in patients diagnosed with PAS. (1) A high transverse skin incision, 12–14 cm in length, was performed through the skin 5–8 cm above the pubic symphysis. (2) A vertical skin incision was made from the xiphoid process to the pubic symphysis, passing around the umbilicus. We compared intraoperative and postoperative outcomes of both types of incisions in patients undergoing cesarean hysterectomy. The aesthetic appearance of the scar was assessed using the scar cosmesis assessment and rating (SCAR) scale. **Results:** Forty-four placenta accreta spectrum patients were evaluated. No differences were observed between the skin incision groups regarding exploration and surgical manipulation. Lengths of hospitalization and operative times were less in patients undergoing high transverse skin incision compared to vertical incision (5.5 ± 1.1 , 8.0 ± 1.1 , $p = 0.03$; respectively). Wound site complications were lower in high transverse skin incision patients. Patients in the high transverse incision group had significantly better SCAR scores than patients in the vertical incision group (3.3 ± 0.9 vs 11.4 ± 1.8 ; $p < 0.001$) and a significantly higher proportion in the high transverse incision group were very satisfied or satisfied with the cosmetic aspects of the scar ($p = 0.001$). **Conclusion:** The high transverse incision method in women with PAS is a better method of skin incision giving reduced operative and hospitalisation times and improved cosmetic outcomes.

Keywords

Placenta accreta spectrum disorder; High transverse incision; Vertical incision; Cesarean hysterectomy

1. Introduction

Placenta accreta spectrum (PAS) disorders are defined as a condition in which the placental villi reach the myometrium by invading the decidua basalis layer [1]. PAS is classified according to the degree of invasion of the trophoblastic tissue into maternal decidua and uterine myometrium: accreta, increta, and percreta. Placenta percreta is the condition in which the placental villi invade the uterine serosa and in advanced cases adjacent organs and especially the urinary bladder [2]. The placenta does not spontaneously separate from the layer

of decidua in patients with PAS and separation of the placenta can cause life-threatening massive haemorrhage [3]. The incidence of PAS has increased from 0.8 per 1000 deliveries in the 1980s to 3 per 1000 deliveries in the last decade. The most important antenatal risk factor for PAS is the number of previous caesarean sections [4]. In the presence of a low-lying placenta (placenta previa) and three previous caesarean sections, a woman would have a 61% risk of PAS [5]. Mortality rates of up to 6.7% have been reported to be associated with PAS [6]. The diagnostic positive predictive value for PAS disorder by assessing previous caesarean sections of patients and concomitant use of ultrasound has been reported to be 90.9% [7]. While organ preserving surgery can be performed in selected cases with a diagnosis of PAS, elective caesarean hysterectomy is preferred in those patients with a high risk for mortality [8]. The choice of skin incision is mainly dependent on the area that needs to be exposed, the elective or emergency nature of the operation, and the surgeon's personal preference. However, the type of incision may have a profound influence on the occurrence of postoperative wound complications [9]. Major incision types commonly used in obstetrical surgery are the Pfannenstiel incision, a vertical incision, and a Maylard incision (Fig. 1). The more commonly preferred skin incision method in surgery of cases with PAS is a vertical incision [10]. This preference aims to reach the uterine fundus and pelvic retroperitoneal natural spaces more easily. There are few studies comparing Pfannenstiel incision, Maylard incision, and vertical incision in cases with PAS in the literature [11]. The current study aims to assess the optimal surgical management of cases with PAS by comparing the perioperative and postoperative outcomes of patients undergoing high transverse skin incision (sparing the rectus abdominis muscle) with those patients undergoing vertical incision.

2. Method

This retrospective study was performed in the Department of Obstetrics and Gynaecology of Muğla Sıtkı Koçman University Faculty of Medicine, Turkey. The study was ap-

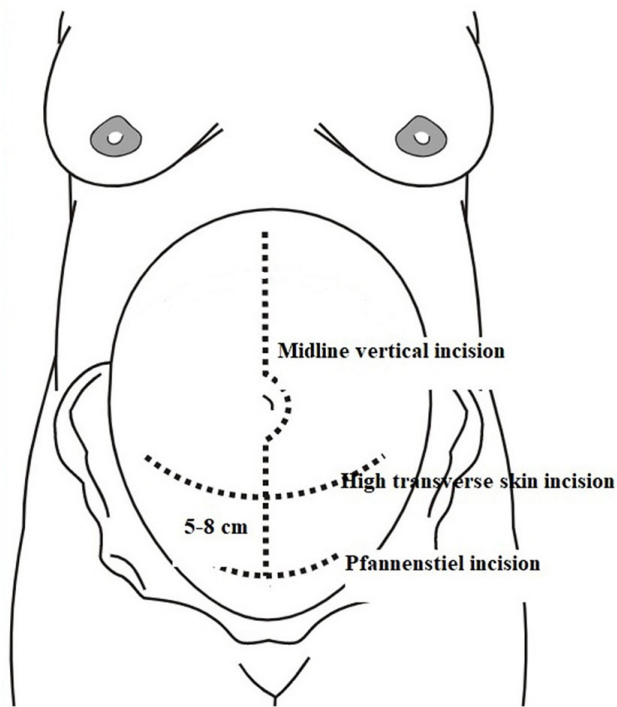


Fig. 1. Types of incision. High transverse skin incision, 12–14 cm in length, was performed through the skin 5–8 cm above the pubic symphysis. Vertical incision ran from the xiphoid process to the pubic symphysis, passing around the umbilicus.

proved by the Ethics Committee of Muğla Sıtkı Koçman University Faculty of Medicine on November 11th, 2020, No: 13/I. Written informed consent was obtained from all participants.

2.1 Case selection and sampling

Sixty-eight patients undergoing uterus sparing surgery or caesarean hysterectomy in an emergency or elective situation with a prediagnosis of PAS and between January 2012 and November 2020 were retrospectively evaluated. All cases were operated on by a single surgeon (EA). Twenty-four patients who underwent uterine sparing surgery were excluded from the study. Forty-four patients who underwent a caesarean hysterectomy and with histopathological diagnosis of PAS were included in the study. The histopathological results of all patients undergoing caesarean section were confirmed as placenta percreta.

2.2 Surgical technique

Two types of incision were performed in patients diagnosed with PAS.

2.2.1 High transverse skin incision (Modified Maylard), n = 24 (54.5%)

A transverse skin incision 12–14 cm in length was performed through the skin 5–8 cm above the pubic symphysis through to the anterior rectus sheath. The fascial sheath was then incised transversely to the lateral borders of the rectus muscles. The rectus muscle was teased away from

the transversalis fascia by the use of gentle finger dissection. Beginning laterally, the transversalis fascia and peritoneum were divided transversely by using curved Mayo scissors. After reaching the abdomen, the gravid uterus could be pulled out of the abdomen in all cases including the ones in which the placenta reached the umbilicus. The infant was delivered by performing a vertical hysterotomy in the uterine fundus in cases undergoing hysterectomy (Figs. 2,3). A midline transverse hysterotomy was performed in patients undergoing organ-preserving surgery (segmental resection).

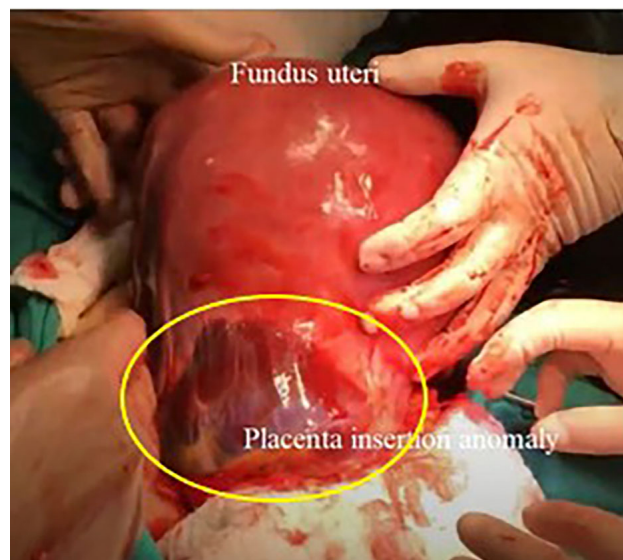

Fig. 2. Appearance after removal of the gravid uterus out of the abdomen at the high transverse incision.

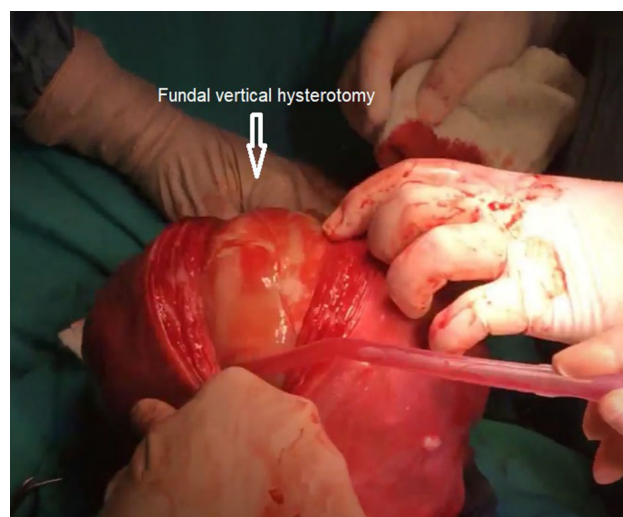


Fig. 3. In the patients with a high transverse skin incision, the gravid uterus could be pulled out of the abdomen, and a fundal vertical hysterotomy was performed for delivery of the infant.

2.2.2 Vertical incision, n = 20 (45.5%)

Ran anywhere from the xiphoid process to the pubic symphysis, passing around the umbilicus. Before reaching the abdominal cavity, the incision would cut through the skin, subcutaneous tissue, and fascia, the linea alba, and transversalis fascia, and the peritoneum.

In the beginning, we performed a vertical skin incision in PAS patients. Since we obtained better clinical outcomes in the patients in whom we performed a high transverse incision, we later preferred a high transverse incision. Our preference for skin incision in the caesarean section of PAS patients was independent of placental location or body mass index (BMI) (kg/m²).

Demographic and clinical characteristics of patients were gathered from the electronic medical records, preoperative notes, imaging results, intraoperative and postoperative notes. Age, parity, previous history of caesarean section, previous history of uterine surgery, BMI of the patient, location of the placenta, and presence of placenta previa were recorded as demographic characteristics. The type of incision, type of anaesthesia, and operative time was obtained from operation notes. Lengths of hospitalization and surgical site complications were recorded from postoperative notes of patients. Patients were later reached through phone numbers recorded in their files. This study evaluated the cosmetic appearance of the scar by using the scar cosmesis assessment and rating (SCAR) scale [12, 13]. This scale documents scar spread, erythema, dyspigmentation, suture marks, hypertrophy, overall impression and patient items, including questions addressing itch and pain. The scale ranges from 0 to 15, where 0 indicates the best possible scar outcome; 15, the worst possible scar outcome. Simultaneously, the patient's satisfaction with the appearance of the scars (very satisfied, satisfied, unsatisfied, or very unsatisfied) was also recorded.

2.3 Statistical analysis

The data was analysed using Statistical Package for Social Science (SPSS) 20.0 for Windows (SPSS Inc., Chicago, IL, USA). Shapiro-Wilk and Kolmogorov-Smirnov tests were used to evaluate the conformity of the data to a normal distribution. Continuous data were presented as mean \pm standard deviation and categorical data as number and percentage. The student *t*-test was used for the intergroup comparisons of parameters with normal distribution and the Mann Whitney U test was used for the intergroup comparisons of parameters without normal distribution. The chi-Square test was used for comparison of qualitative data. A *p*-value of < 0.05 was considered to be statistically significant.

3. Results

The high transverse skin incision was performed in 24 patients and the vertical incision was performed in 20 patients. Demographic data are presented in Table 1. There was no statistically significant difference between patients undergoing a high transverse skin incision or a vertical incision regarding demographic characteristics (maternal age, BMI, gra-

Table 1. Demographic data.

Demographics	High transverse incision	Vertical incision	<i>p</i>
	n = 24 (54.5%)	n = 20 (45.5%)	
Maternal age (years)	32.54 \pm 4.4	32 \pm 4.1	0.87
BMI (kg/m ²)	29.4 \pm 3.4	30.5 \pm 4.1	0.29
Gravidity (n)	3.3 \pm 1.1	2.9 \pm 0.9	0.16
Prior caesarean (n)	2.1 \pm 0.7	1.9 \pm 0.7	0.23

Body, mass index (BMI). *p* value < 0.05 . Values were given as mean \pm standard deviation (range) or number (%).

vidity, number of previous caesarean deliveries) (*p* > 0.05).

Mean operative time was determined to be 101.5 \pm 8.2 minutes in the high transverse skin incision group, and 129.8 \pm 7.7 minutes in the vertical incision group (*p* = 0.04). While regional anaesthesia was used in 14 of 24 patients undergoing high transverse skin incision, regional anaesthesia was used only in 1 of 20 patients undergoing vertical incision (*p* = 0.12). The average length of hospitalization was 5.5 days in patients with a high transverse skin incision, and about 8 days in patients with a vertical incision. The length of hospitalization was significantly lower in the group with a high transverse skin incision (*p* = 0.03) (Table 2). No statistical difference was determined between the amount of erythrocyte suspension transfused to patients undergoing a high transverse incision and patients undergoing a vertical skin incision (*p* = 0.16). The gestational age at which delivery was performed and baby birth weights were similar in the transverse and vertical incision groups.

Abscess, seroma, and dehiscence were assessed as wound site complications. While skin complications were seen more often in the vertical incision, no statistically significant difference was determined (*p* > 0.05) (Table 3).

Patients in the high transverse incision group had significantly better SCAR scores than the vertical incision group (3.3 \pm 0.9 vs 11.4 \pm 1.8; *p* < 0.001) (Table 4), and a significantly higher proportion was very satisfied or satisfied with the cosmetic aspects of the scar.

4. Discussion

The best surgical method has not been clearly defined in the management of PAS [12]. While complications such as haemorrhage and uterine rupture can develop in very early pregnancy for some cases with a diagnosis of PAS, other cases can reach advanced gestational ages [13]. Surgical management of cases with PAS may vary from patient to patient. While uterus-sparing surgery can be performed in some cases, caesarean hysterectomy has to be performed in many cases [14]. Most surgeons prefer a vertical incision in deliveries of patients with PAS. There is no clear evidence regarding the benefit of the routine use of a vertical midline incision in patients antenatally diagnosed with abnormally invasive placenta [11]. There is a very limited number of studies comparing abdominal incision types in the surgery of PAS patients [15]. Sometimes, a vertical incision below the um-

Table 2. Intraoperative and postoperative outcomes.

	High transverse incision	Vertical incision	<i>p</i>
	n = 24 (54.5%)	n = 20 (45.5%)	
Operative time (minutes)	101.5 ± 8.2	129.8 ± 7.7	0.04
Length of hospitalization (days)	5.5 ± 1.1	8.0 ± 1.1	0.03
Blood transfusions (units)	2.71 ± 1.33	2.35 ± 1.46	0.16
Regional anaesthesia (n, %)	14 (58.3)	1 (5)	0.001
Gestational age at surgery (weeks)	34.4 ± 3.5	34.3 ± 3.7	0.96
Birth weight (gr)	2235 ± 404	2096 ± 286	0.19

p value < 0.05. Values were given as mean ± standard deviation (range) or number (%).

Table 3. Wound complications.

Wound complications	High transverse incision	Vertical incision	<i>p</i>
	n = 24 (54.5%)	n = 20 (45.5%)	
Abscess	1	3	0.21
Seroma	1	4	0.20
Dehiscence	0	3	0.23

p value < 0.05. Values were given as mean ± standard deviation (range) or number (%).

Table 4. Postsurgery SCAR assessments from patients who underwent high transverse incision or vertical incision during caesarean hysterectomy.

Outcome	High transverse Incision	Vertical incision	<i>p</i>
	n = 24 (54.5%)	n = 20 (45.5%)	
SCAR score	3.3 ± 0.9	11.4 ± 1.8	<0.001
Satisfaction with scar			0.01
Very satisfied	15 (62.5%)	3 (15%)	
Satisfied	6 (25.0%)	4 (20%)	
Unsatisfied	2 (8.3%)	4 (20%)	
Very unsatisfied	1 (4.1%)	9 (45%)	

SCAR scale, Scar Cosmesis Assessment and Rating scale; SD, standard deviation.

bilicus is extended above the umbilicus. We tried to define an alternative method of skin incision with aim of being able to perform less invasive surgery in these patients and to report our experiences. The primary purpose for the preference of vertical incision is to be able to reach the uterine fundus and pelvic spaces easily. Since it is more difficult to reach the afore-mentioned areas with the Pfannenstiell incision, this method of incision is preferred by very few surgeons in cases with PAS [15]. In our study, with the high transverse skin incision, the uterus could be removed out of the abdomen easily before delivery of the foetus in cases undergoing both uterine sparing surgery and caesarean hysterectomy (Fig. 2). The uterine fundus, pelvic spaces, vascular structures, and other spaces in the lower abdomen were easily reached. With the high transverse skin incision, it was not difficult to visualize the pelvic ureter in the upper abdomen. Also, it is possible to transition from the high transverse incision to the Maylard incision for a wider viewing angle and better visualization of the surgical field. However, we did not require a transition

to the Maylard incision in any patient.

Most of the time, the amount of haemorrhage, damage to surrounding organs (particularly the urinary bladder and ureter), and the length of hospitalization in cases with PAS is determined by the extent of placental invasion of other organs and vascular structures, not by the type of incision. While the total operative time is determined by the degree of how complicated the case is, closure of the abdominal wall is easier and shorter with the transverse incision compared to the vertical incision. In this study, the total operative time was determined to be shorter with the high transverse incision compared to the vertical incision. Additionally, the length of hospitalization in cases with a high transverse incision was shorter than in cases with a vertical incision. Regional anaesthesia is preferred in caesarean delivery since foetal and maternal risks can be reduced and it is also more comfortable in terms of postpartum maternal analgesia [16]. Due to the higher risk of massive haemorrhage, the possibility of prolongation of operative time, and the extension of the incision above the umbilicus in the vertical incision, general anaesthesia is more commonly used during surgeries of patients with PAS [17]. In our study, regional anaesthesia could be used in patients undergoing high transverse skin incision. While Grantcharov *et al.* [18] reported that the possibility of dehiscence was higher with vertical incision compared to transverse incision, Seiler *et al.* [19] reported that there was no difference between the two types of incision. In our study, dehiscence was encountered more in patients undergoing vertical incision, but the difference was not statistically significant. Seiler *et al.* [19] reported that the possibility of abscess, seroma, and other infection was higher at the incision site with vertical incision compared to transverse incision. In our study, while skin complications were more common in the group with a vertical incision, no statistically significant difference was determined between the groups.

While Palatnik *et al.* [20] did not obtain better obstetrical and perinatal outcomes in patients undergoing caesarean delivery with a vertical incision compared to a transverse incision, their analysis showed that a vertical incision was associated with worse maternal outcomes and skin complications. In the study performed by Halm [21], evaluating 123 patients, the authors reported that 82% of patients with transverse incision and 65% of patients with vertical incision were satisfied

with their incision appearances. In our study, patients with a transverse incision were more satisfied with their incision sites compared to patients with a vertical incision.

Weaknesses of the study

The retrospective design of our study, carried out in a single centre and by a single surgeon, and the relatively small number of non-randomised patients are limitations of our study. Additionally, not having detailed data about our operative time (entrance into the abdominal cavity and abdominal closure times) is another weakness of the study.

5. Conclusions

Our new high transverse skin incision technique, which spares rectus muscle and enables use of the Maylard incision, can contribute to the search for less invasive and safer surgical methods to manage women with a serious condition such as PAS. Additionally, the high transverse incision method has improved cosmetic outcomes and can reduce the cosmetic anxieties of PAS patients about their future lives. Randomized prospective studies evaluating a larger number of patients are warranted.

Abbreviations

BMI, Body mass index; GA, Gestational age; PAS, Placenta accreta spectrum; SCAR, Scar by using the scar cosmetic assessment and rating.

Author contributions

EA conceptualized and designed the study, collected data, performed surgical operations, performed statistical analysis, reviewed and revised the manuscript.

Ethics approval and consent to participate

All procedures involving human participants were done with the ethical standards set by the local ethics committee for clinical research at Mugla Sitki Kocman University, Faculty of Medicine, Mugla, Turkey (approval number: 11.11.20-No: 13/I), in accordance with the 1964 Helsinki declaration and its later amendments. Informed consent was obtained from all individual participants.

Acknowledgment

Thanks to all the peer reviewers for their opinions and suggestions.

Funding

This research received no external funding.

Conflict of interest

The authors declare no conflict of interest.

References

- [1] Garmi G, Salim R. Epidemiology, etiology, diagnosis, and management of placenta accreta. *Obstetrics and Gynecology International*. 2012; 2012: 873929.
- [2] Goh WA, Zalud I. Placenta accreta: diagnosis, management and the molecular biology of the morbidly adherent placenta. *The Journal of Maternal-Fetal & Neonatal Medicine*. 2016; 29: 1795–1800.
- [3] Silver RM, Branch DW. Placenta accreta spectrum. *New England Journal of Medicine*. 2018; 378: 1529–1536.
- [4] Higgins MF, Monteith C, Foley M, O’Herlihy C. Real increasing incidence of hysterectomy for placenta accreta following previous caesarean section. *European Journal of Obstetrics & Gynecology and Reproductive Biology*. 2013; 171: 54–56.
- [5] No G-tG. Placenta praevia, placenta praevia accreta and vasa praevia: diagnosis and management (pp. 1–26). London: RCOG. 2011.
- [6] Vinograd A, Wainstock T, Mazor M, Beer-Weisel R, Klaitman V, Dukler D, *et al.* Placenta accreta is an independent risk factor for late pre-term birth and perinatal mortality. *The Journal of Maternal-Fetal & Neonatal Medicine*. 2015; 28: 1381–1387.
- [7] Comstock CH, Love JJ Jr, Bronsteen RA, Lee W, Vettraino IM, Huang RR, *et al.* Sonographic detection of placenta accreta in the second and third trimesters of pregnancy. *American Journal of Obstetrics and Gynecology*. 2004; 190: 1135–1140.
- [8] Kilicci C, Sanverdi I, Ozkaya E, Eser A, Bostanci E, Yayla Abide C, *et al.* Segmental resection of anterior uterine wall in cases with placenta percreta: a modified technique for fertility preserving approach. *The Journal of Maternal-Fetal & Neonatal Medicine*. 2018; 31: 1198–1203.
- [9] Ellis H, Coleridge-Smith PD, Joyce A. Abdominal incisions—vertical or transverse? *Postgraduate medical journal*. 1984; 60: 407–410.
- [10] Allen L, Jauniaux E, Hobson S, Papillon-Smith J, Belfort MA, Tikkanen M. FIGO consensus guidelines on placenta accreta spectrum disorders: nonconservative surgical management. *International Journal of Gynecology & Obstetrics*. 2018; 140: 281–290.
- [11] Collins SL, Alemdar B, van Beekhuizen HJ, Bertholdt C, Braun T, Calda P, *et al.* Evidence-based guidelines for the management of abnormally invasive placenta: recommendations from the International Society for Abnormally Invasive Placenta. *American Journal of Obstetrics and Gynecology*. 2019; 220: 511–526.
- [12] Mitric C, Desilets J, Balayla J, Ziegler C. Surgical management of the placenta accreta spectrum: an institutional experience. *Journal of Obstetrics and Gynaecology Canada*. 2019; 41: 1551–1557.
- [13] Mantel Å, Ajne G, Wollmann CL, Stephansson O. Previous preterm cesarean delivery and risk of uterine rupture in subsequent trial of labor—a national cohort study. *American Journal of Obstetrics and Gynecology*. 2020; 224: 380.e1–380.e13.
- [14] Clausen C, Lönn L, Langhoff-Roos J. Management of placenta percreta: a review of published cases. *Acta Obstetrica et Gynecologica Scandinavica*. 2014; 93: 138–143.
- [15] Szlachta-McGinn A, Mei J, Tabsh K, Afshar Y. Transverse versus vertical skin incision for planned cesarean hysterectomy: does it matter? *BMC Pregnancy and Childbirth*. 2020; 20: 65.
- [16] Salicath JH, Yeoh EC, Bennett MH. Epidural analgesia versus patient-controlled intravenous analgesia for pain following intra-abdominal surgery in adults. *Cochrane Database of Systematic Reviews*. 2018; 8: CD010434.
- [17] Binici O, Büyükfırat E. Anesthesia for cesarean section in parturients with abnormal placentation: a retrospective study. *Cureus*. 2019; 11: e5033.
- [18] Grantcharov TP, Rosenberg J. Vertical compared with transverse incisions in abdominal surgery. *European Journal of Surgery*. 2001; 167: 260–267.
- [19] Seiler CM, Deckert A, Diener MK, Knaebel H-P, Weigand MA, Victor N, *et al.* Midline versus transverse incision in major abdominal surgery: a randomized, double-blind equivalence trial (PO-VATI: ISRCTN60734227). *Annals of Surgery*. 2009; 249: 913–920.
- [20] Palatnik A, Grobman WA. The association of skin-incision type at cesarean with maternal and neonatal morbidity for women with multiple prior cesarean deliveries. *European Journal of Obstetrics & Gynecology and Reproductive Biology*. 2015; 191: 121–124.
- [21] Halm J, Lip H, Schmitz P, Jeekel J. Incisional hernia after upper abdominal surgery: a randomised controlled trial of midline versus transverse incision. *Hernia*. 2009; 13: 275–280.