

Diagnosis and management of intramural ectopic pregnancy

Qian Hu^{1,2}, Mohammed Sharooq Paramboor³, Tao Guo^{1,2,*}

¹Laboratory of Molecular Translational Medicine, Center for Translational Medicine, Key Laboratory of Birth Defects and Related Diseases of Women and Children (Sichuan University), Ministry of Education, Department of Pediatrics, West China Second University Hospital, Sichuan University, 610041 Chengdu, Sichuan, China

²Department of Obstetrics & Gynecology, West China Second University Hospital, Sichuan University, 610041 Chengdu, Sichuan, China

³West China Medical School, Sichuan University, 610041 Chengdu, Sichuan, China

*Correspondence: ivan.gt@163.com (Tao Guo)

DOI: [10.31083/j.ceog4804154](https://doi.org/10.31083/j.ceog4804154)

This is an open access article under the CC BY 4.0 license (<https://creativecommons.org/licenses/by/4.0/>).

Submitted: 3 August 2020 Revised: 25 September 2020 Accepted: 15 October 2020 Published: 15 August 2021

Background: Intramural pregnancy is a rare form of ectopic pregnancy where the embryo is implanted within the myometrium, separate from the endometrial cavity. Preoperative diagnosis of intramural pregnancy is difficult and it can easily be misdiagnosed for other diseases such as intrauterine pregnancy or gestational trophoblastic disease. Medical therapy and surgery are used to treat intramural pregnancy, with surgery often being performed via laparotomy and also including hysterectomy. **Case:** We present a case of intramural pregnancy that was misdiagnosed and wrongly managed by a local hospital. It was finally diagnosed correctly and managed in our hospital by combining hysteroscopy and laparoscopy under the guidance of intra-abdominal ultrasound. Our experience again highlights the difficulty in diagnosing intramural pregnancy preoperatively due to the lack of standard diagnostic criteria. This can in turn lead to inappropriate treatments. Earlier surgical intervention would allow faster diagnosis and also simultaneous treatment of the disease. The majority of intramural ectopic pregnancies have high blood flow that can cause severe hemorrhage and are therefore treated by medication or laparotomy and hysterectomy. **Conclusion:** Our experience reveals that a minimally invasive procedure is also safe and effective in select cases where advanced endoscopic expertise is available.

Keywords

Intramural ectopic pregnancy; Minimally invasive surgery; Diagnosis and management

1. Introduction

Intramural pregnancy is a rare type of ectopic pregnancy that accounts for less than 1% of all ectopic pregnancies [1, 2]. It refers to a uterine conceptus located within the myometrium but without a connection to the fallopian tubes or endometrial cavity [3]. The etiology of intramural pregnancy is unclear and there are currently several hypotheses. It has been suggested they may occur following surgical procedures such as myomectomy, hysteroscopy and dilatation and curettage [4, 5]. Any of these procedures could lead to the formation of myometrial defects which could then give rise to

intramural pregnancy. The clinical symptoms of intramural pregnancy are nonspecific and patients may present with no obvious symptoms, mild vaginal bleeding and abdominal pain or, conversely, with hypovolemic shock due to a uterine rupture [6–8]. Because of the low incidence of intramural pregnancy and because it has non-specific clinical symptoms that are very similar to those of early pregnancy, attempted abortion, gestational trophoblastic disease and other common diseases, it is very difficult to obtain an early diagnosis of this condition. Diagnosis requires visualization of trophoblastic invasion into the myometrium, which is most commonly achieved using transvaginal ultrasound or magnetic resonance imaging (MRI) [9]. Transvaginal ultrasound has become the method of first choice because it is noninvasive and low cost. However, intramural pregnancy is usually described in case reports and only a few articles have published the ultrasound image characteristics. There is still no consensus regarding the ultrasound criteria required for the diagnosis of intramural pregnancy and this is a significant cause of misdiagnosis before surgery [10]. The management strategies for intramural pregnancy vary depending on the severity of clinical presentation, the exact location of the pregnancy, the viability and gestational age at diagnosis [6]. We present here a case of intramural pregnancy diagnosed after surgery in our institution that illustrates the difficulty in obtaining a correct diagnosis. In this case, the incorrect initial diagnosis of a missed abortion complicated the clinical timeline and delayed the diagnosis, resulting in the wrong management. We also propose the use of diagnostic hysteroscopy and laparoscopy as a minimally invasive method to establish the correct diagnosis. Under the guidance of ultrasound, therapeutic laparoscopy can be used to precisely excise the intramural pregnancy. This is an effective treatment for certain cases and allows hysterectomy to be avoided while preserving patient fertility.

2. Case

A 35-year-old woman (gravida 5, para 2) attended the early pregnancy unit of the No. 1 hospital of Liangshan State. She complained of amenorrhea for 44 days and mild vaginal bleeding for one day, with no abdominal pain. Previously, she had two spontaneous vaginal deliveries at term. She underwent curettage at the local hospital during the last delivery because of postpartum hemorrhage caused by intrauterine pregnancy residues. In the following years she had two unremarkable artificial abortions. Her gynecological and medical histories were otherwise unremarkable. The speculum examination revealed the cervix was smooth and closed. No active bleeding was seen and no tenderness of the cervix, uterus or adnexa was found with bimanual examination. It was reported that transvaginal sonography revealed a heterogeneous mass measuring $2.1 \times 2.9 \times 0.8$ cm and located in the endometrial cavity, however the image could not be obtained. Two weeks later, transvaginal sonography was repeated and an irregular-shaped gestational sac was observed within the endometrial cavity. This measured 3.7×1.5 cm and contained yolk sac and fetal pole, but fetal pulsation was not detected. The serum β -human Chorionic Gonadotropin (β -hCG) level was more than 15,000 mIU/mL. An arrested intrauterine pregnancy was suspected and hence the patient opted for surgical evacuation of conception products under general anesthesia. About 10 g of conception product was evacuated from the uterine cavity, but histological examination was not performed. One week later another ultrasound scan was performed in the local hospital and a 1.6×1.5 cm ill-defined, mild hyperechogenic mass located within the endometrial cavity was reported. The serum β -hCG level had declined to 1700+ mIU/mL. A diagnosis of retained products of conception was made and the patient was given another dilatation and curettage, with 10 g of decidual tissue removed. Two weeks later another ultrasound scan was conducted, this time revealing a mixed echogenic mass measuring 2.4×1.7 cm and located within the endometrial cavity. The serum β -hCG level increased to 6000+ mIU/mL and because products of conception remained in the uterine cavity, a third dilatation and curettage was arranged. However, on this occasion no tissue was removed. The patient was then given oral mifepristone at 50 mg qd for 3 weeks. The β -hCG level declined to 236 mIU/mL after this treatment. The patient then received another week of mifepristone at 50 mg qd po and following this the β -hCG level declined to 52 mIU/mL. The patient then chose to be treated by Traditional Chinese Medicine for one week, however the HCG level declined to only 46 mIU/mL and ultrasound scan showed a 1.5×1.0 cm mixed echogenic mass within the uterine cavity.

The patient was then referred to our hospital for further investigation and treatment. She presented with irregular vaginal bleeding but no other typical symptoms. None of the previous ultrasound imaging pictures taken at the local hospital were provided to us and only the reports were available. In our hospital, ultrasound scan revealed a $1.9 \times 1.9 \times 2.0$ cm

mixed echogenic mass embedded in the myometrium of the right posterior uterine wall near the fundus (Fig. 1A). Color-flow Doppler analysis revealed high blood flow at the periphery of the mass, such that it was difficult to determine the boundary between the myometrium and endometrial cavity. Pelvic CT scan showed a 2.5×2.5 cm abnormal mass within the right posterior uterine wall and with an obscure boundary (Fig. 1C). A tentative diagnosis of intramural pregnancy was made, but gestational trophoblastic neoplasm (GTN) was not excluded. Since the β -hCG level was low, MTX therapy was given and the patient kept under observation, with regular β -hCG level monitoring. The serum β -hCG level increased slightly and one month later the level was 71.9+ mIU/mL. Transvaginal ultrasound showed a $1.9 \times 1.9 \times 2.0$ cm mixed echogenic mass with mild hypervascularity near the right cornu, with no boundary to the myometrium (Fig. 1B). The endometrium was 15 mm thick and not continuous. The diagnosis was uncertain, with retained products of conception after interstitial pregnancy being favored but also with the possibility of invasive trophoblastic disease. The patient was therefore recommended to undergo diagnostic hysteroscopy under general anesthesia. This revealed the endometrial cavity was not triangular and that it was shaped like a bucket instead, with the cornu not visible. Much of the uterine wall was covered by fibrous tissue. After separating the fibrous tissue on the right uterine wall, no intrauterine pregnancy tissue was observed and the ostiums from the fallopian tubes could still not be seen (Fig. 2A). Transabdominal ultrasound was then performed and this showed a hyperechogenic mass measuring $1.5 \times 1.1 \times 1.4$ cm located in the right cornu. The boundary between the mass and the cavity as well as the myometrium was unclear, hence the decision was made to perform a diagnostic laparoscopy. The laparoscopic procedure showed a normal uterus shape, as well as the fallopian tubes and ovaries, with no obvious abnormality of the uterus (Fig. 2B). Under the guidance of transvaginal ultrasound, an incision was made in the right cornu uterine wall near the fundus and 2×1 cm of yellowish, soft conception tissue was found deep in the myometrium (Fig. 2C) and removed completely. Histological examination confirmed the presence of chorionic villi in the intramural product, with no features of abnormal trophoblastic proliferation (Fig. 3). The serum β -hCG level fell to 11.4+ mIU/mL the day after surgery and was not detectable 2 weeks later. One month later, the patient began menstruation and the HCG test result was negative. As the patient expressed no desire to become pregnant again, she was recommended to take longterm contraception.

3. Discussion

Intramural pregnancy is thought to be the rarest form of ectopic pregnancy [3]. It was first reported by Doderlein in 1913 and only a handful of cases have been reported in the world literature to date [1, 11]. Trophoblast invasion in intramural pregnancies extends beyond the endometrial-myometrial junction and the conceptus is partially or com-

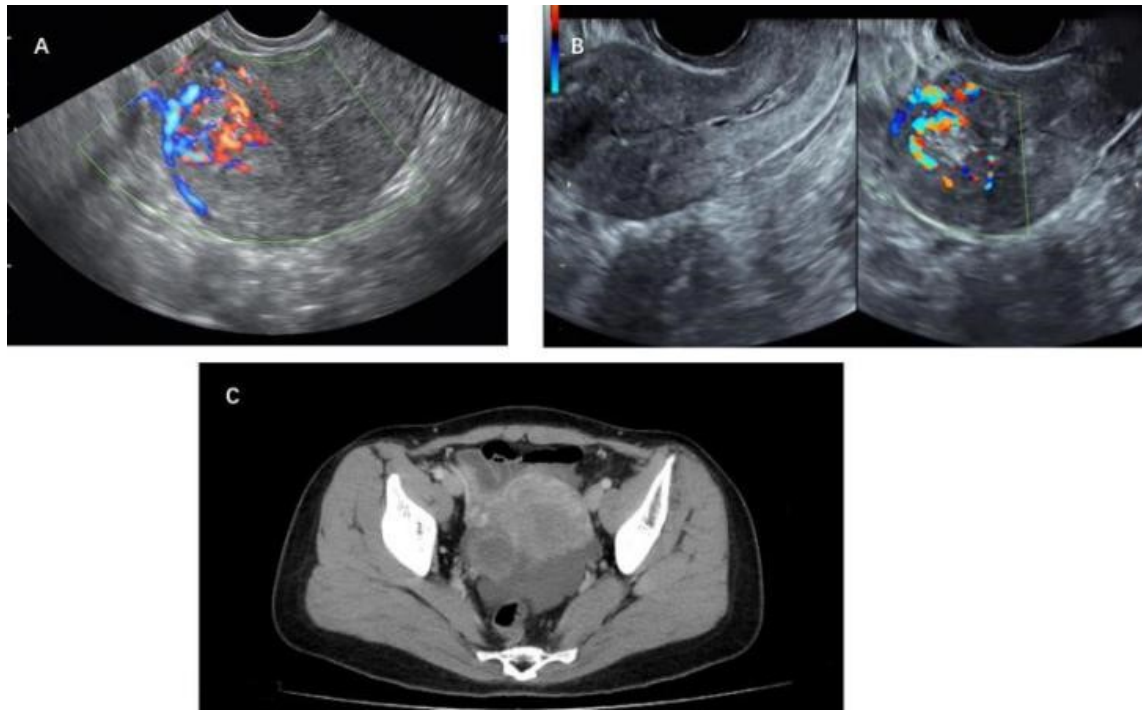


Fig. 1. The ultrasound and Computed tomography scan images. (A) The first ultrasound scan taken in our hospital. A mixed echogenic mass measuring about $1.9 \times 1.9 \times 2.0$ cm in size was embedded in the myometrium of the right posterior uterine wall near the fundus. Color-flow Doppler analysis revealed high blood flow at the periphery of the mass, making it difficult to determine the boundary between the myometrium and the endometrial cavity. (B) Transvaginal ultrasound image after one month of MTX therapy. A $1.9 \times 1.9 \times 2.0$ cm mixed echogenic mass with mild hypervascularity was found near the right cornu and showed no boundary to the myometrium. The endometrium was 15 mm thick and not continuous. (C) The CT scan showed a 2.5×2.5 cm abnormal mass within the right posterior uterine wall and with an obscure boundary.

pletely located within the myometrium of the uterine corpus [9]. Currently, there is no consensus regarding the standard for its diagnosis. The diagnosis relies mainly on vaginal ultrasound, especially 3-dimensional color-Doppler imaging which can improve the accuracy of diagnosis. For difficult cases, MRI can assist with the diagnosis and define the type. This is because it can accurately locate the distance between the uterine horn or the interstitium of the fallopian tube and the uterine cavity, and can clearly distinguish the endometrial-myometrial junction [10]. The ultrasound manifestation can be a gestational sac or a mass within the myometrium. The type of gestational sac in the myometrium is easy to diagnose as intramural pregnancy, especially if it has yolk sac, embryo and a fetal heart beat. When the ultrasound indicates a heterogenous echogenic mass within the myometrium and with unclear boundary and rich peripheral blood flow, it is very difficult to differentiate intramural pregnancy from gestational trophoblastic tumor [12]. In the present case, the patient underwent repeated two-dimensional vaginal ultrasound examination. This approach has limitations for the diagnosis of intramural pregnancy, which was the main reason for the incorrect treatments given in the local hospital. Most intramural pregnancies have no villous tissue remaining following dilatation and curettage. However, for partial intramural pregnancy cases some villous tissue is visible and this can lead to the misdiagnosis of

intrauterine pregnancy, as described in our case. Intramural pregnancy can only be definitively identified by surgery and the postoperative pathology results showing a large amount of placental villi within the myometrium. The exact pathogenesis of intramural pregnancy is not entirely clear. Some of the proposed theories include endometriosis [13], invasive uterine surgery (such as uterine curettage in the case discussed above, cesarean section, myomectomy), failure of *in-vitro* fertilization, and inflammation of the perimetrium [4, 5, 14].

The symptoms of intramural pregnancy are nonspecific and in our case the patient presented with only mild vaginal bleeding and no other typical symptoms. Another reason that our patient was misdiagnosed at the local hospital was the lack of familiarity with intramural pregnancy. This resulted in 3 episodes of curettage, leading to serious uterine cavity adhesions that made the diagnosis even more difficult. Before suggesting ultrasound examination and management, we recommend that sonographers and clinician familiarize themselves with the patient's clinical history. Intramural ectopic pregnancy should be considered in addition to ectopic pregnancy of the uterine cornu, choriocarcinoma and dysfunctional uterine bleeding when the following symptoms are present in women of reproductive age: irregular vaginal bleeding with no villi found after curettage; the curettage instruments cannot reach the gestational sac; the outcomes

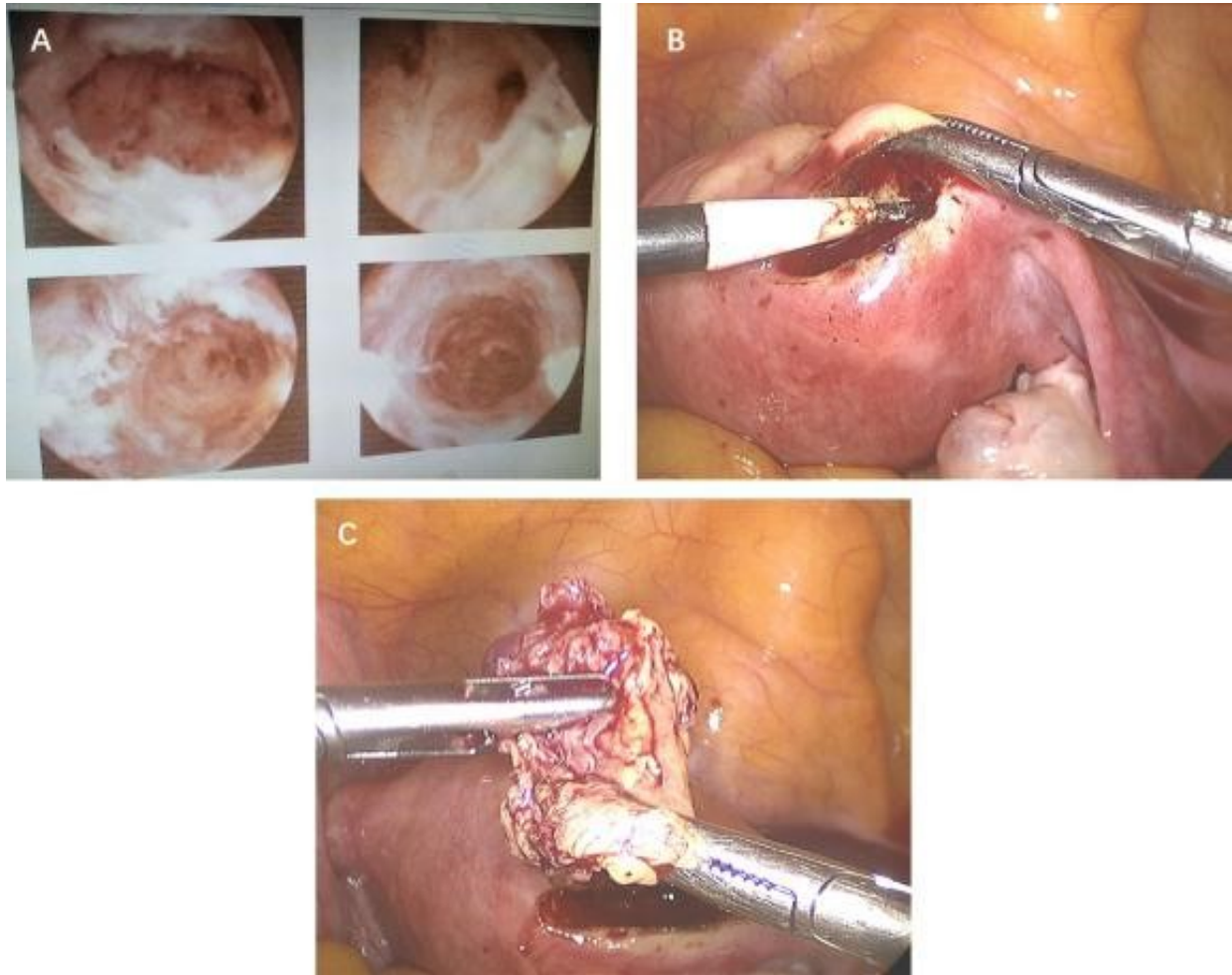


Fig. 2. Hysteroscopic and laparoscopic images. (A) Hysteroscopy showed the endometrial cavity was not triangular and was shaped more like a bucket. The cornu could not be seen. Much of the uterine wall was covered by fibrous tissue. Following separation of the fibrous tissue from the right uterine wall, no intrauterine pregnancy tissue was observed and the outlet of the fallopian tube could still not be seen. (B) Laparoscopic procedure showed a normal uterus shape, as well as the fallopian tubes and ovaries, with no obvious abnormality of the uterus, an incision was made in the right cornu uterine wall near the fundus. (C) 2 × 1 cm of yellowish, soft conception tissue was found deep in the myometrium and removed completely.

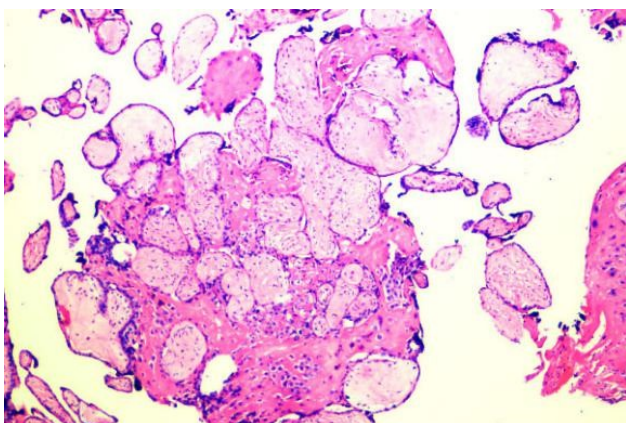


Fig. 3. Pathology results confirmed the presence of chorionic villi in the intramural product, with no features of abnormal trophoblastic proliferation.

from curettage are not ideal; the β -hCG level remains high after curettage. The most important differential diagnosis is with invasive gestational trophoblastic disease, which can also present with foci of trophoblastic tissue invading deep into the myometrium [15]. Since a conservative approach may be appropriate for intramural pregnancy whereas trophoblastic disease requires referral to a dedicated oncology unit for systemic chemotherapy, it is extremely important to make a correct diagnosis before further treatment. Choriocarcinoma should be considered if β -hCG levels continue to rise or do not decrease to an acceptable level post-partum or post-abortion. Metastasis of choriocarcinoma to other organs will induce corresponding symptoms, such as intracranial hemorrhage and hemoptysis. Although serum β -hCG levels may be increased in intramural pregnancy and choriocarcinoma, they are higher in choriocarcinoma compared to ectopic pregnancy, where the level rarely exceeds 10,000 mIU/L. Therefore, when the diagnosis is uncertain we sug-

gest the patient be referred to a tertiary hospital for further management rather than repeated dilatation and curettage or systemic chemotherapy. Although it is very difficult to diagnose intramural pregnancy before surgery, we believe the accuracy could be improved with a better understanding of this condition and with improved examination techniques. For difficult cases such as the patient described in this report, diagnostic hysteroscopy and laparoscopy could be considered.

The management of intramural pregnancy depends on the extent of myometrial involvement, gestational age at diagnosis, overall patient status, hemodynamic stability and the desire for future fertility. As with other types of ectopic pregnancy, treatment can be surgical, medicinal or expectant [1, 6, 16, 17]. Kirket *et al.* described a case of posterior wall intramural pregnancy that was successfully treated by expectant management, as there was no evidence of rupture and the β -hCG levels were quite low (9.5 mIU). During expectant management, the serum β -hCG declined to undetectable levels within 10 days [16]. Some intramural pregnancies are amenable to medicinal management. Methotrexate is the most commonly used drug and may be administered locally or systemically [1]. Surgery should be suggested after medicinal management fails. This can be either laparotomy or laparoscopy, depending on the risk of hemorrhage and the surgeon's ability [7, 17, 18]. Careful laparoscopic surgical removal of lesions can be an effective treatment for intramural pregnancy, although this option should be used with caution because the abundant local blood flow may make it difficult to regulate bleeding.

Since preoperative diagnosis of intramural ectopic pregnancy was very difficult in the present case, we chose surgical intervention to establish the diagnosis. Although no abnormality was found by the initial laparoscopy, intra-abdominal ultrasound was used to guide incision of the uterus in order to precisely locate the lesion. This avoided more extensive damage to the uterus and hysterectomy. Using minimally invasive surgery, we removed the pregnancy product and obtained a definitive pathology result in order to direct the appropriate treatment.

In conclusion, we describe a case of an extremely rare form of ectopic pregnancy that was initially misdiagnosed and managed in a local hospital. We were finally able to establish the correct diagnosis and treat with conservative surgery by performing minimally invasive laparoscopy under the guidance of ultrasound. The present case report again demonstrates the difficulty in achieving preoperative diagnosis of intramural pregnancy. Under these circumstances, earlier surgical intervention would be an appropriate choice to simultaneously diagnose and treat intramural pregnancy. In addition, surgical intervention reduces the risk of potentially toxic side effects from chemotherapy due to a misdiagnosis of choriocarcinoma. Although intramural pregnancy is a rare condition, uterine rupture could become a serious complication as the pregnancy develops. Hence, it is important to establish a precise definition and classification system for in-

tramural pregnancy, in addition to improved diagnostic and treatment guidelines. As with most intramural pregnancies, blood flow to the gravid uterus increases significantly over baseline before medication. While laparoscopic management of such cases is feasible, this procedure carries the risk of significant hemorrhage. Historically, laparoscopy has only been used for diagnosis in difficult cases [18]. The patient should therefore be carefully evaluated prior to laparoscopic surgery, especially with regard to blood flow to the lesion. Although almost all cases of intramural pregnancy are treated with either laparotomy or medication, minimally invasive laparoscopic surgery can also be used to excise the intramural products of conception, as in this case.

Abbreviations

MTX, Methotrexate; qd, quaque die.

Author contributions

QH conceived the idea and prepared the original manuscript. MSP revised and edited the contents. TG edited it, added more content. All authors read and approved the final manuscript.

Ethics approval and consent to participate

Institutional review board and ethics committee of West China Second University Hospital approval was obtained (Ethical approval number: K2017035). Written informed consent was provided by the patient for publication.

Acknowledgment

Thanks to all the peer reviewers for their opinions and suggestions.

Funding

This research received no external funding.

Conflict of interest

The authors declare no conflict of interest.

References

- [1] Ong C, Su L, Chia D, Choolani M, Biswas A. Sonographic diagnosis and successful medical management of an intramural ectopic pregnancy. *Journal of Clinical Ultrasound*. 2010; 38: 320–324.
- [2] Chida H, Kikuchi A, Murai M, Sasaki Y, Kanasugi T, Isurugi C, *et al.* Intramural pregnancy implanted into a myometrial defect caused by curettage: diagnosis with transvaginal sonography and preconception and postconception magnetic resonance imaging. *Journal of Ultrasound in Medicine*. 2016; 35: 2066–2067.
- [3] Bouzari Z, Keshani M, Yazdani S, Barat S, Zinalzadeh M. Intramural pregnancy. *Journal of Obstetrics and Gynaecology*. 2010; 30: 195–196.
- [4] Ishiguro T, Yamawaki K, Chihara M, Nishikawa N, Enomoto T. Myomectomy scar ectopic pregnancy following a cryopreserved embryo transfer. *Reproductive Medicine and Biology*. 2018; 17: 509–513.
- [5] Wong KS, Tan J, Ang C, Ngu A. Myomectomy scar ectopic pregnancy. *Australian and New Zealand Journal of Obstetrics and Gynaecology*. 2010; 50: 93–94.

- [6] Bannon K, Fernandez C, Rojas D, Levine EM, Locher S. Diagnosis and management of intramural ectopic pregnancy. *Journal of Minimally Invasive Gynecology*. 2013; 20: 697–700.
- [7] Memtsa M, Jamil A, Sebire N, Jauniaux E, Jurkovic D. Diagnosis and management of intramural ectopic pregnancy. *Ultrasound in Obstetrics & Gynecology*. 2013; 42: 359–362.
- [8] Naftalin J, Jurkovic D. The endometrial-myometrial junction: a fresh look at a busy crossing. *Ultrasound in Obstetrics and Gynecology*. 2009; 34: 1–11.
- [9] Liu N, Han X, Guo X, Sun L, Kong X. Ultrasound diagnosis of intramural pregnancy. *Journal of Obstetrics and Gynaecology Research*. 2017; 43: 1071–1075.
- [10] Wang J, Xie X. Sonographic diagnosis of intramural pregnancy. *Journal of Ultrasound in Medicine*. 2013; 32: 2215–2217.
- [11] Lu H, Sheu B, Shih J, Chang Y, Torng P, Huang S. Intramural ectopic pregnancy. *Acta Obstetrica et Gynecologica Scandinavica*. 1997; 76: 886–889.
- [12] Luo ZQ, Zhou P, Gao F, He W, Luo SJ. Diagnosis of intramural pregnancy by endoluminal color Doppler ultrasonography and review of the literature. *Journal of Southern Medical University*. 2010; 30: 2343–2346.
- [13] Sebire NJ. The diagnosis of gestational trophoblastic disease in early pregnancy: implications for screening, counseling and management. *Ultrasound in Obstetrics and Gynecology*. 2005; 25: 421–424.
- [14] Lyu J, Sun W, Lin Y. Successful management of heterotopic intramural pregnancy leading to a live birth of the intrauterine pregnancy. *Journal of Minimally Invasive Gynecology*. 2018; 25: 1126–1127.
- [15] Kong L, Mao N, Shi Y, Ma H, Xie H. Diagnosis and management of intramural ectopic pregnancy in the second trimester—a case report. *BJR: Case Reports*. 2017; 3: 20160095.
- [16] Kirk E, McDonald K, Rees J, Govind A. Intramural ectopic pregnancy: a case and review of the literature. *European Journal of Obstetrics & Gynecology and Reproductive Biology*. 2013; 168: 129–133.
- [17] Nabeshima H, Nishimoto M, Utsunomiya H, Arai M, Ugajin T, Terada Y, *et al*. Total laparoscopic conservative surgery for an intramural ectopic pregnancy. *Diagnostic and Therapeutic Endoscopy*. 2010; 2010: 1–4.
- [18] Ye K, Chen XH, Si Y, Kong XC. Preoperative diagnosis and successful laparoscopic management of intramural pregnancy: case report. *European Journal of Obstetrics & Gynecology and Reproductive Biology*. 2013; 171: 385–386.