

# The brainstem-tentorium angle revisited. Difficulties encountered and possible solutions

Laura Joigneau<sup>1,2</sup>, Yolanda Ruiz<sup>1,2,3</sup>, Coral Bravo<sup>2,3</sup>, Julia Bujan<sup>4,5,6</sup>, Miguel A Ortega<sup>4,5,6,7,\*,†</sup>, Juan De León-Luis<sup>1,2,3,8,†</sup>

<sup>1</sup>Department of Radiology, University Hospital Gregorio Marañón, 28009 Madrid, Spain

<sup>2</sup>Fetal Medicine Unit, Maternal and Child Health and Development Network, Department of Obstetrics and Gynecology, Gregorio Marañón Hospital, 28009 Madrid, Spain

<sup>3</sup>Department of Obstetrics and Gynecology, Complutense University of Madrid, 28009 Madrid, Spain

<sup>4</sup>Ramón y Cajal Institute of Healthcare Research (IRYCIS), 28034 Madrid, Spain

<sup>5</sup>Department of Medicine and Medical Specialties, Faculty of Medicine and Health Sciences, University of Alcalá, Alcalá de Henares, 2880 Madrid, Spain

<sup>6</sup>University Center for the Defense of Madrid (CUD-ACD), 28047 Madrid, Spain

<sup>7</sup>Department of Cancer Registry and Pathology, Hospital Universitario Príncipe de Asturias, Alcalá de Henares, 28801 Madrid, Spain

<sup>8</sup>Department of Public and Maternal and Child Health, School of Medicine, Complutense University of Madrid, 28801 Madrid, Spain

\*Correspondence: [miguel.angel.ortega92@gmail.com](mailto:miguel.angel.ortega92@gmail.com) (Miguel A Ortega)

† These authors contributed equally.

DOI: [10.31083/j.ceog4804158](https://doi.org/10.31083/j.ceog4804158)

This is an open access article under the CC BY 4.0 license (<https://creativecommons.org/licenses/by/4.0/>).

Submitted: 22 November 2020 Revised: 11 January 2021 Accepted: 19 January 2021 Published: 15 August 2021

**Background:** Fetal posterior fossa fluid collections (PFFC) can range from normal variants to severe anomalies with highly variable neurological prognosis. The diagnosis of these entities is still a challenge for ultrasound as well as for fetal magnetic resonance imaging (MRI). The measurements of the brainstem-vermis angle (BV angle) and the brainstem-tentorium angle (BT angle) have been described as helpful in the differential diagnosis of the PFFC. **Case:** We present a case with posterior fossa abnormalities where the measurement of the BT angle could be difficult due to the anatomy distortion. **Conclusion:** We propose two alternative ways of measuring the BT angle that could be reliable in all the spectrum of PFFC.

## Keywords

Fetal posterior fossa fluid collections; Fetal magnetic resonance imaging; Brainstem-tentorium angle; BT angle; Brainstem-vermis angle

## 1. Introduction

Prenatal diagnosis and classification of fetal posterior fossa fluid collections (PFFC) is still a challenge nowadays. Numerous studies have evaluated different approaches and measurements to better depict these findings [1]. The measurements of the brainstem-vermis angle (BV angle) and the brainstem-tentorium angle (BT angle) have been described as helpful in the differential diagnosis of the PFFC [2, 3]. We present a case with posterior fossa abnormalities where the measurement of the BT angle could be difficult due to the anatomy distortion.

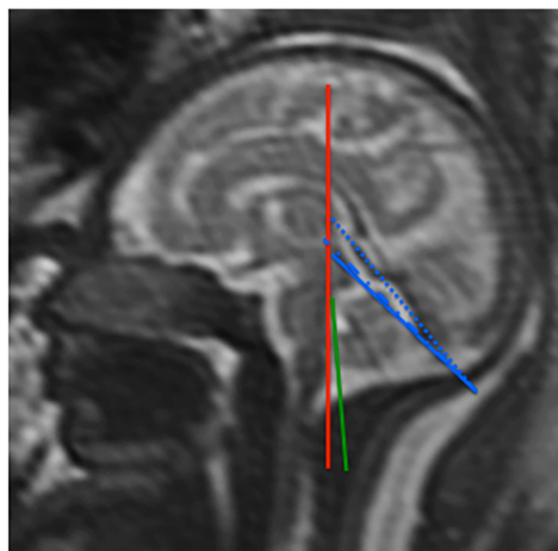
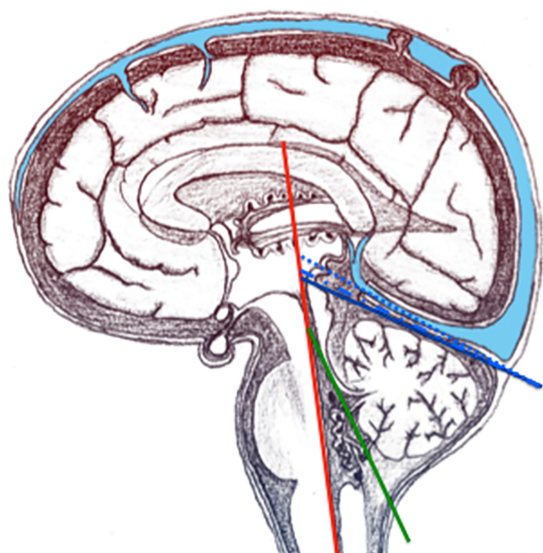
## 2. Case report

A 34-year-old woman, gravida 3, para 2, was referred to our unit during week 26 of her pregnancy due to a suspicion of fetal posterior fossa abnormality. She had followed a normal pregnancy control in another center. During the midtrimester scan a widened posterior fossa was visualized, without any other apparent malformation. An amniocentesis for fetal karyotyping was performed, obtaining a normal result (46 XY).

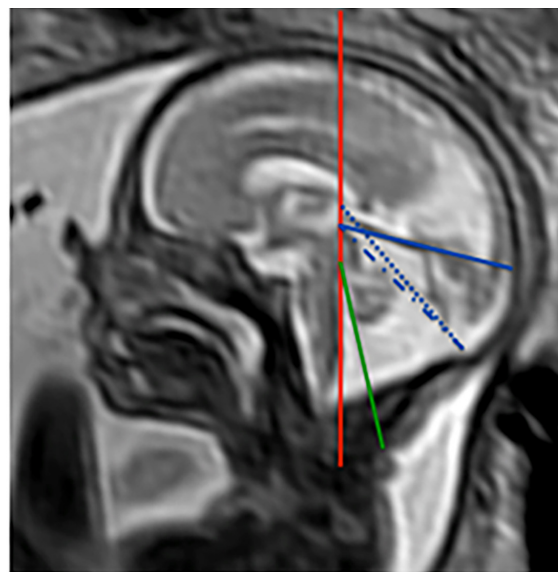
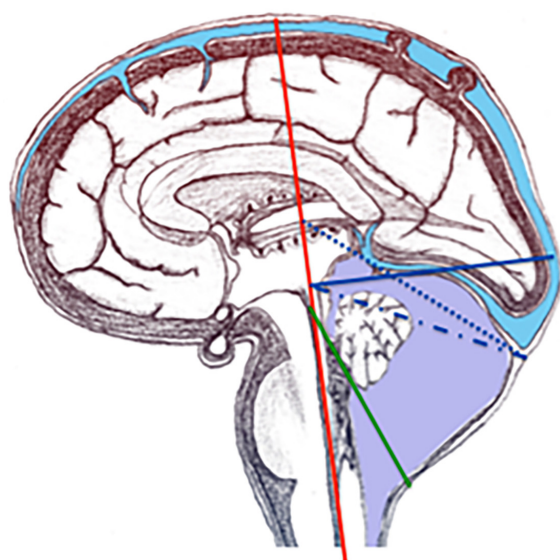
A complete sonography performed at our center revealed a mild unilateral ventriculomegaly (13 mm), with a widened cisterna magna, and an apparently hypoplastic vermis. We did not detect any extracranial abnormalities. Maternal blood samples for CMV, toxoplasmosis and rubella were negative. We performed a sonographic follow-up, without detecting any changes in the findings. The fetal magnetic resonance imaging (MRI) performed in week 29 revealed a bilateral ventriculomegaly, cerebellar hypoplasia, the presence of an arachnoid cyst in the posterior fossa and periventricular white matter lesions.

The patient was informed by a multidisciplinary group about the prognosis, and decided to undergo a termination.

We retrospectively measured the BT and BV angles as described by Ghi *et al.* [2] (Fig. 1) using a midsagittal view of the fetal brain obtained by MRI. The BV angle was 12°. Although we also measured the BT angle (76°), we encountered some difficulties due to the highly distorted anatomy of the posterior fossa (Fig. 2).



**Fig. 1. Anatomical scheme and MRI performed in a fetus with normal posterior fossa.** According to Ghi *et al.* [2], the BV angle is defined as the angle formed by a line tangential to the dorsal part of the brainstem (red line) and a line starting from the tip of the pons and crossing the lower edge of the cerebellar vermis (green line); whereas the BT angle is defined as the angle formed by a line tangential to the dorsal part of the brainstem and a line starting from the upper limit of the quadrigeminal plate, and following the tentorial surface down to the occipital bone (continuous blue line). The dotted blue line starts at the posterior tentorial insertion and ends at the anterior tentorial insertion. The dash-dotted blue line starts at the posterior tentorial insertion and ends at the quadrigeminal plate.



**Fig. 2. Anatomical scheme and MRI performed in a fetus with a posterior fossa abnormality.** The BT angle is formed by the red line and the continuous blue line. The dash-dotted blue line starts from the posterior tentorial insertion towards the quadrigeminal plate; the dotted blue line starts at the posterior tentorial insertion and ends at the anterior tentorial insertion. The BV angle is defined by the red and green lines.

### 3. Discussion

Fetal PFFC associated with upward displacement of the tentorium and rotation of the cerebellar vermis can range from normal variants to severe anomalies with highly variable neurological prognosis [4–6] (Blake's pouch cyst, megacisterna magna, vermian hypoplasia and Dandy-Walker malformation). Although prenatal ultrasound is currently the standard technique for the diagnosis of fetal anomalies,

fetal MRI is increasingly applied as a complementary technique, mainly in central nervous system defects, diaphragmatic hernias or placental anomalies [7, 8]. Despite the ongoing debate over whether one technique is superior to the other in the evaluation of the fetal brain [8–12], prenatal diagnosis of these entities is a challenge for both techniques. Some authors [13] advocate the use of fetal MRI as it can provide detailed information about normal and abnormal neu-

roanatomy [9, 14] and therefore identify other neural malformations that are typically not detected by ultrasound [3]. Other authors as Gandolfi *et al.* [12] consider that if multiplanar sonography is obtained satisfactorily, fetal MRI rarely adds significant information in the evaluation of the PFFC. Both techniques may provide the differential diagnosis of PFFC mainly based upon the rotation of the vermis and the level of the tentorium insertion (evaluated by the position of the torcular Herophili). However, it is precisely in the evaluation of the posterior fossa and its anatomical structures that fetal MRI has proven the greatest advantage over sonography [3, 9] especially in delineating the torcular Herophili, which is rarely seen with ultrasound due to acoustic shadowing from the skull bones [12].

Ghi *et al.* [2] published two sonographic measurements obtained in a mid-sagittal plane (BT angle and BV angle) that can be reproduced in fetal MRI in normal midtrimester fetuses. In abnormal conditions, both angles have shown to be useful in the categorization of the PFFC [15]. Specifically, the clinical utility is that the BT angle is assumed as a quantitative measure of the normal tentorial insertion on the skull, and the BV angle as a quantitative measurement of the normal rotation of the cerebellar vermis over the brainstem [2]. Although reproducible in normal midtrimester fetuses [2] and of valuable interest in the categorization of the PFFC [15], the reproducibility of these measurements in fetuses with PFFC has not yet been demonstrated, and intra and interobserver variability [16] in these cases varies widely among different authors [8, 17].

The case presented illustrates the difficulty that can be found when measuring the BT angle in fetuses with PFFC. Given that fetal MRI allows an excellent visualization of the whole tentorium, drawing the line that starts at the upper limit of the quadrigeminal plate and follows the tentorial surface should be done with ease (BT angle as described by Ghi *et al.* [2]) (Fig. 2, continuous line). But this line does not seem to accurately represent the posterior insertion of the tentorium in the occipital bone in cases where the tentorium does not follow a linear trajectory. We propose two alternative definitions of the BT angle. In the first one, the line that delineates the tentorium would connect the anterior and posterior tentorial insertion (Fig. 2, dotted line). However, we have observed that in some cases the anterior insertion can be difficult to identify as it can overlap with the straight sinus at its junction with the inferior sagittal sinus and the vein of Galen. For this reason, we propose a second BT angle, in which we would keep the quadrigeminal plate, that is always correctly visualized by fetal MRI, as the anterior reference point. In this case, we would connect the quadrigeminal plate with the posterior tentorial insertion at the torcular Herophili (Fig. 2, dash-dotted line). Any of these two alternative forms of measuring the angle would probably be more suitable for the majority of cases with PFFC. Further works would be necessary to prove it.

In accordance with the reported results of Volpe *et al.* [15],

the BV angle seems to be more accurate than the BT angle as described by Ghi *et al.* [2] in the evaluation of PFFC. However, we believe that the alternative descriptions we propose may be reliable in all the spectrum of PFFC, even when the anatomy is highly distorted (as in the case presented). More studies are warranted in order to assess their reproducibility and accuracy in evaluating fetuses with posterior fossa abnormalities.

## 4. Conclusions

Diagnosis of PFFC remains challenging, and intra and inter observer variability of currently used BT and BV angles can vary widely. The new BT angle that we propose could improve this variability owing to a better diagnosis of PFFC.

## Author contributions

LJ, YR and JDLL conceived and designed the experiments; LJ, YR, CB and JDLL performed the experiments; LJ, YR, JB, MAO and JDLL analyzed the data; LJ, YR, CB and JDLL contributed reagents and materials; LJ, YR, CB, JB, MAO and JDLL wrote the paper. All authors read and approved the final manuscript.

## Ethics approval and consent to participate

The study was conducted according to the guidelines of the Declaration of Helsinki, and approved by the Clinical Research Ethics Committee of the Central University Hospital of Defense-UAH (37/17). The collected data and information complied with the current legislation on data protection (Organic Law 3/5 December 2018 on the Protection of Personal Data and the Guarantee of Digital Rights and Regulation (EU) 2016/679).

## Acknowledgment

We wish to thank the Hospital Universitario de Fuenlabrada for partially funding her observership at the Fetal Medicine Foundation in London. The authors are grateful to Mr. Miguel Pérez Valderrama for assistance with graphics.

## Funding

This study (FIS-PI18/00912, FIS-PI13/02769, BA#09/90011) was supported by the Instituto de Salud Carlos III (Plan Estatal de I + D + i 2013-2016) and cofinanced by the European Development Regional Fund "A way to achieve Europe" (ERDF) and B2017/BMD-3804 MITIC-CM.

## Conflict of interest

The authors report no conflicts of interest. Miguel A Ortega is our Reviewer Board, given his role as Reviewer board member, had no involvement in the peer-review of this article and has no access to information regarding its peer-review.

## References

- [1] D'Antonio F, Khalil A, Garel C, Pilu G, Rizzo G, Lerman-Sagie T, *et al.* Systematic review and meta-analysis of isolated posterior fossa malformations on prenatal ultrasound imaging (part 1): nomenclature, diagnostic accuracy and associated anomalies. *Ultrasound in Obstetrics & Gynecology*. 2016; 47: 690–697.
- [2] Ghi T, Contro E, De Musso F, Farina A, Conturso R, Bonasoni P, *et al.* Normal morphometry of fetal posterior fossa at midtrimester: brainstem-tentorium angle and brainstem-vermis angle. *Prenatal Diagnosis*. 2012; 32: 440–443.
- [3] Patek KJ, Kline-Fath BM, Hopkin RJ, Pilipenko VV, Crombleholme TM, Spaeth CG. Posterior fossa anomalies diagnosed with fetal MRI: Associated anomalies and neurodevelopmental outcomes. *Prenatal Diagnosis*. 2012; 32: 75–82.
- [4] Adamsbaum C, Moutard ML, Andre C, Merzoug V, Ferey S, Quere MP, *et al.* MRI of the fetal posterior fossa. *Pediatric Radiology*. 2005; 35: 124–140.
- [5] D'Antonio F, Khalil A, Garel C, Pilu G, Rizzo G, Lerman-Sagie T, *et al.* Systematic review and meta-analysis of isolated posterior fossa malformations on prenatal imaging (part 2): neurodevelopmental outcome. *Ultrasound in Obstetrics & Gynecology*. 2016; 48: 28–37.
- [6] Chapman T, Menashe SJ, Zare M, Alessio AM, Ishak GE. Establishment of normative values for the fetal posterior fossa by magnetic resonance imaging. *Prenatal Diagnosis*. 2018; 38: 1035–1041.
- [7] Levine D, Barnes PD, Madsen JR, Li W, Edelman RR. Fetal central nervous system anomalies: MR imaging augments sonographic diagnosis. *Radiology*. 1997; 204: 635–642.
- [8] Zhao D, Cai A, Zhang J, Wang Y, Wang B. Measurement of normal fetal cerebellar vermis at 24–32 weeks of gestation by transabdominal ultrasound and magnetic resonance imaging: a prospective comparative study. *European Journal of Radiology*. 2018; 100: 30–35.
- [9] Sepulveda W, Wong AE, Sepulveda F, Martinez-Ten P, Ximenes R. Fetal magnetic resonance imaging and three-dimensional ultrasound in clinical practice: general aspects. *Best Practice & Research Clinical Obstetrics & Gynaecology*. 2012; 26: 575–591.
- [10] Robinson AJ, Ederies MA. Diagnostic imaging of posterior fossa anomalies in the fetus. *Seminars in Fetal & Neonatal Medicine*. 2016; 21: 312–320.
- [11] Lerman-Sagie T, Prayer D, Stöcklein S, Malinger G. Fetal cerebellar disorders. *The Cerebellum: Disorders and Treatment*. 2018; 35: 3–23.
- [12] Gandolfi Colleoni G, Contro E, Carletti A, Ghi T, Campobasso G, Rembouskos G, *et al.* Prenatal diagnosis and outcome of fetal posterior fossa fluid collections. *Ultrasound in Obstetrics & Gynecology*. 2012; 39: 625–631.
- [13] Malinger G, Lev D, Lerman-Sagie T. Is fetal magnetic resonance imaging superior to neurosonography for detection of brain anomalies? *Ultrasound in Obstetrics & Gynecology*. 2002; 20: 317–321.
- [14] Sepulveda W, Ximenes R, Wong AE, Sepulveda F, Martinez-Ten P. Fetal magnetic resonance imaging and three-dimensional ultrasound in clinical practice: applications in prenatal diagnosis. *Best Practice & Research. Clinical Obstetrics & Gynaecology*. 2012; 26: 593–624.
- [15] Volpe P, Contro E, De Musso F, Ghi T, Farina A, Tempesta A, *et al.* Brainstem-vermis and brainstem-tentorium angles allow accurate categorization of fetal upward rotation of cerebellar vermis. *Ultrasound in Obstetrics & Gynecology*. 2012; 39: 632–635.
- [16] Illescas T, Martínez-Ten P, Bermejo C, Estévez M, Adiego B. Brainstem-vermis and brainstem-tentorium angles: 3D ultrasound study of the intra- and inter-observer agreement. *Journal of Maternal-Fetal & Neonatal Medicine*. 2018; 31: 1073–1077.
- [17] Paladini D, Donarini G, Parodi S, Volpe G, Sglavo G, Fulcheri E. Hindbrain morphometry and choroid plexus position in differential diagnosis of posterior fossa cystic malformations. *Ultrasound in Obstetrics & Gynecology*. 2019; 54: 207–214.