Fallopian tube carcinoma metastatic to the pericardium and breast

S. Buyukkurt[1], M.A. Vardar[1], H. Zeren[2], B. Guzel[1], I. Tuncer[2]

[1]*Department of Obstetrics & Gynecology,* [2]*Department of Pathology, University of Cukurova School of Medicine, Adana (Turkey)*

Summary

Introduction: Fallopian tube carcinoma is a rare gynecological tumor and simultaneous pericardial and breast metastasis of this cancer is an extremely exceptional event. *Case:* A 46-year-old woman with FIGO Stage IIIc, grade 3 adenocarcinoma of the fallopian tube received cyclophosphamide and carboplatin subsequent to surgery. The disease had been completely silent for 41 months and then it relapsed with pericardial and breast metastasis consecutively. She expired one year after the relapse. *Conclusion:* Although clinical and biological behavior and response to the treatment of fallopian tube carcinoma is quite similar to epithelial ovarian carcinoma, breast and pericardium are unusual sites of metastasis for each malignancy. As survival is prolonged with new chemotherapeutics these atypical cancer metastases will be observed more frequently.

Key words: Fallopian tube carcinoma; Adenocarcinoma; Breast metastasis; Pericardial metastasis.

Introduction

Primary fallopian tube carcinoma accounts for a very small portion of female cancers. The clinical course of the disease is quite similar to epithelial ovarian cancer. Although fallopian tube carcinoma usually spreads intraperitoneally, distant metastases to the common target of the metastatic disease such as the brain, lung and bone have been reported previously [1-3]. Pericardium and breast are not common sites for metastasis. In this paper we report a case of fallopian tube carcinoma metastasizing simultaneously to the breast and pericardium which are rarely involved by metastatic disease.

Case Report

A 46-year-old, gravida 3, para 2, abortus 1 woman presented with weight loss, abdominal distention and fatigue in May 2003. These complaints had started two months before and her personal and familial medical history were unremarkable. A 3 x 4 x 4 cm solid, heterogeneous mass was discovered in the left adnexal area with diffuse ascites using sonography and computerized axial tomography (CAT). Tumoral implantation on the peritoneum and omentum was also found. Cytological examination of the ascites fluid revealed malignant epithelial carcinoma. As the serum level of CA 125 was 345 U/ml, the initial diagnosis was ovarian carcinoma. Exploratory laparotomy was performed and a mass filling the left tube was seen accompanying the peritoneal carcinomatosis and omental caking. The opposite tube, both ovaries and uterus appeared normal. Total abdominal hysterectomy, bilateral salpingo-oophorectomy, omentectomy, pelvic and paraaortic lymphadenectomy were performed. Any tumoral implant greater than 1 cm in diameter was left at the end of the operation. The pathological examination of the specimen revealed grade 3 adenocarcinoma of the uterine tube without lymph node involvement (Figure 1).

At first six cycles of paclitaxel and carboplatin as first-line chemotherapy were employed but the patient developed an allergic reaction to the former agent on the first day of the treatment and the chemotherapy regimen was changed to six cycles of cyclophosphamide with carboplatin. This chemotherapy regimen ended in October 2003. In October 2006 her CA 125 level was found to be 183 U/ml following three years where the disease had been radiologically and biochemically silent. Computed tomography (CT) of the thorax and abdomen was only remarkable for peritoneal carcinomatosis. Malignant epithelial cells were found in the peritoneal fluid. Five cycles of second-line chemotherapy were started with docetaxel and carboplatin. She received five cycles of third-line chemotherapy with liposomal doxorubicin, because her CA 125 level was still high (113 U/ml). The CA 125 level was persistently elevated (162 U/ml) and the patient's respiratory complaints started when the chemotherapy regimen finished in June 2007. The chest radiogram was remarkable only for a minimally enlarged cardiac silhouette. Echocardiography demonstrated pericardial effusion and the ejection fraction was 55%. A catheter was placed in the pericardium and 220 ml of serosanguinous fluid was drained. The patient's complaints improved considerably and the catheter was removed on the third day. The cytological examination of the pericardial fluid revealed malignant epithelial carcinoma (Figure 2). Simultaneously a 3 x 3 cm solid mass was palpated at the upper outer quadrant of the left breast. The breast examination was not significant for peau d'orange, nipple discharge or retraction. Excisional biopsy of the breast mass revealed adenocarcinoma with disseminated intra-lymphatic tumoral thrombus (Figure 3). The immunohistochemical evaluation of the sample was negative for estrogen receptor, progesterone receptor, c-erb 2 and gross cystic disease fluid protein (GCDFP)-15.

The patient refused additional therapy and expired in October 2007, 53 months after the initial diagnosis.

Discussion

Carcinoma of the fallopian tube accounts less than 0.5% of all female cancers [1]. The classical symptoms

Revised manuscript accepted for publication July 24, 2008

Fig. 1

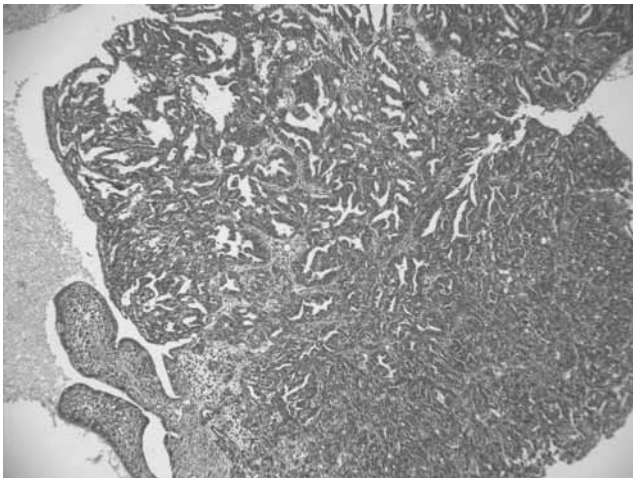

Fig. 2

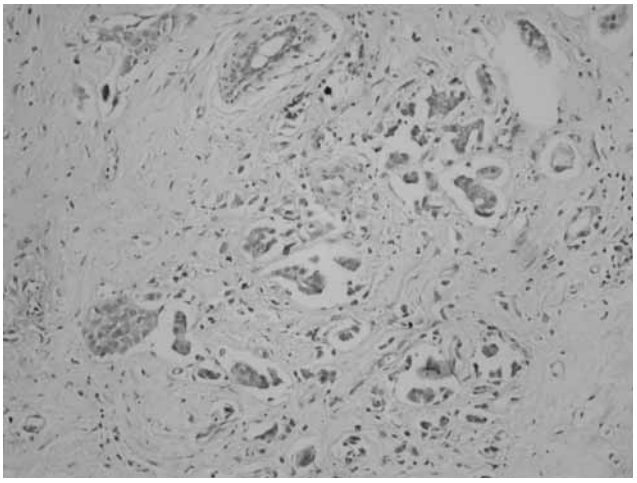

Fig. 3

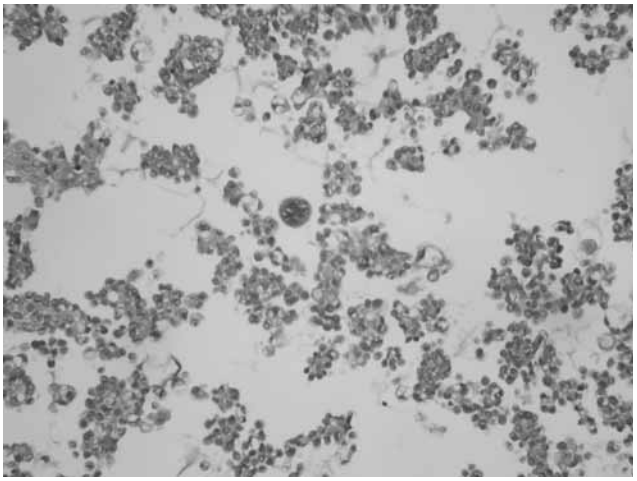

Figure 1. — A hematoxylin-eosin stained section from the fallopian tube showing a highly aggressive tumor invading the tubal wall. Tumor cells are arranged in cords, glands and small groups.

Figure 2. — Malignant cells with papillary projections and a few bizarre multi nucleated atypical cells can be seen in the pericardial cytology.

Figure 3. — Disseminated intra-lymphatic tumor thrombus is seen in the breast parenchyma.

of tubal carcinoma are pelvic pain, pelvic mass and serosanguinous vaginal discharge which are known as the Latzko triad [3]. The biological and clinical behavior of fallopian tube carcinoma closely resemble that of ovarian cancer. While dissemination of the tumor usually occurs in the peritoneal cavity, lymphatic and hematogenous spread of the tumor may rarely be seen [1-3].

Breast involvement is a rare entity in oncology. The incidence of secondary breast cancer in autopsy series varies from 0.4% to 6.6% while nearly 1% is observed clinically. The range is dependent on whether hematological malignancies are included or not [4]. The most common source of metastasis to the breast is the opposite breast. Leukemia, lymphoma, malignant melanoma and lung carcinoma are the most common cancers metastasizing to the breast. Ovarian cancer is the commonest gynecological cancer that spreads to the breast [5]. The clinical findings of breast metastasis are not similar to that of primary malignant breast cancer. While metastatic lesions in the breast tend to be superficial, they cause neither skin or nipple retraction, nor nipple discharge. The mass is usually firm, mobile and painless. The diagnosis requires a strong suspicion and knowledge of the history of primary malignant carcinoma [4, 5]. Metastatic lesions to the breast do not show the mammographic features of primary malignancy, such as microcalcification and spiculation. Metastasis to the breast may be through the lymphatic or hematogenous route and each has different mammographic features. Lymphatic metastasis shows subcutaneous trabeculation and irregularity. Glandular stroma is denser as well. Lymphatic metastases to the breast and inflammatory breast carcinoma have similar mammographic appearances. Hematogenous metastasis to the breast may exhibit a solitary, well demarcated lesion which seems to be benign fibroadenoma. On the other hand, multiple or diffuse involvement may also be seen in hematological metastasis [6]. Fine needle aspiration cytology, incisional or excisional biopsy are the appropriate ways of the histological diagnosis. Radical excision of the breast mass is redundant unless it becomes an ulcerated or excessively huge mass [5].

The incidence of neoplastic cardiac invasion is 10% to 20% in autopsy series and 85% of them have pericardial involvement [7]. Nearly one-third of pericardial involvement is symptomatic [8]. Symptoms of pericardial involvement are related to the amount of fluid and the rapidness of fluid accumulation. A huge amount of fluid collected slowly in the pericardium may be asymptomatic whereas a small amount of pericardial effusion may produce cardiac tamponade when it is stored quickly.

Clinical findings are usually nonspecific and the diagnosis can be made easily via echocardiography [9]. Pericardiocentesis is an easy procedure to relieve the symptoms and collect a fluid sample for pathological analysis. Pericardial effusion can be managed via catheter drainage, systemic chemotherapy, intrapericardial chemotherapeutics, radioisotopes or sclerosing agent instillation and external radiotherapy. Stage and histopathology of the disease should be kept in mind when selecting a treatment modality stated above. Catheter drainage should be used initially because it is an easy procedure and effective in most cases. When malignant pericarditis relapses, instillation therapies should be considered. On the other hand, systemic chemotherapy or external radiotherapy may be favored for cancers which are extremely sensitive to these therapies, like lymphoma or leukemia [7, 9].

Breast or pericardial invasion of gynecological malignancies usually signifies widely disseminated disease. Extra abdominal metastasis of fallopian tube carcinoma has rarely been reported. In this report, we have presented a case of tubal carcinoma which was asymptomatic for 41 months and then pericardial and breast metastasis developed respectively. A review of the previous reports showed that this is the first case of pericardial metastasis and the second case of breast metastasis of the primary fallopian tube. As new chemotherapeutical drugs gain success in the treatment of epithelial ovarian cancer as well in that of tubal cancer, we believe that these atypical sites of metastasis will be involved more frequently. Precise diagnosis of the metastatic disease is very important for accurate management. The aim of the treatment should only be to relieve the symptoms and avoid radical excision of the breast tumor or extensive pericardiectomy.

References

[1] Hidaka T., Nakamura T., Shima T., Sumiya S., Saito S.: "Cerebral metastasis from a primary adenocarcinoma of the fallopian tube". *Gynecol. Oncol.*, 2004, *95,* 260.

[2] Newton H.B., Stevens C., Santi M.: "Brain metastases from fallopian tube carcinoma responsive to intra-arterial carboplatin and intravenous etoposide: a case report". *J. Neurooncol.,* 2001, *55*, 179.

[3] Courville X.F., Cortés Z., Katzman P.J., Rosier R.N.: "Case report: Bone metastasis from fallopian tube carcinoma". *Clin. Orthop. Relat. Res.,* 2005, *434,* 278.

[4] Akcay A.: "Metastatic disease in the breast". *The Breast*, 2002, *11,* 526.

[5] Moore D.H., Wilson D.K., Hurteau J.A., Look K.Y., Stehman F.B., Sutton G.P.: "Gynecolgic cancers metastatic to the breast". *J. Am. Coll. Surg.,* 1998, *187,* 178.

[6] Lee S.H., Park J.M., Kook S.H., Han B.K., Moon W.K.: "Metastatic tumors to the breast: Mammographic and ultrasonographic findings". *J. Ultrasound Med.*, 2000, *19*, 257.

[7] Donato D.M., Sevin B.U., Averette H.E.: "Neoplastic pericarditis and gynecologic malignancies: a review of the literature". *Obstet. Gynecol. Surv.,* 1986, *41*, 473.

[8] Jamshed A., Khafaga Y., El-Husseiny G., Gray A.J., Manji M.: "Pericardial metastasis in carcinoma of the uterine cervix". *Gynecol. Oncol.*, 1996, *61*, 451.

[9] Ghosh K., Dusenbery K., Twiggs L.B.: "Cardiac metastasis of cloacagenic carcinoma of the vagina: a case and review of gynecologic malignancies with cardiac metastasis". Gynecol. Oncol., 2000, *76,* 208.

Address reprint requests to:
S. BUYUKKURT, M.D.
Department of Obstetrics & Gynecology
University of Cukurova School of Medicine
01330, Adana (Turkey)
e-mail: selimbuyukkurt@gmail.com