A novel technique for surgical reconstruction of the perineal floor following anteroposterior exenteration of the pelvis - case report and review of the literature

M.A. Kyriazi[1], V.K. Stafyla[1], A. Kondi-Pafiti[2], N. Arkadopoulos[1], N. Dafnios[1], D. Hasiakos[3], S. Fotiou[3], D. Mastorakos[1], V. Smyrniotis[4]

[1] *2nd Department of Surgery, Areteion Hospital, University of Athens Medical School*
[2] *2nd Department of Pathology, Areteion Hospital, University of Athens Medical School*
[3] *2nd Department of Obstetrics and Gynaecology, Areteion Hospital University of Athens Medical School*
[4] *5th Department of Surgery, Areteion Hospital, University of Athens Medical School, Athens (Greece)*

Summary

Pelvic exenteration is the only potentially curative surgical procedure for patients with recurrent cervical, vaginal, vulvar or rectal cancers, especially following adjuvant chemotherapy or radiotherapy. Morbidity rates, however, remain high, which is significantly attributed to complications of the pelvic floor reconstruction techniques. We describe a novel reconstruction technique of the pelvic floor, involving a combination of an oblique rectus abdominis myocutaneous flap and a synthetic absorbable mesh as a pelvic sling for additional support, in a 63-year-old female patient with recurrent vulvar carcinoma. Combining the use of myocutaneous flaps and prosthetic mesh material can provide an effective alternative solution to the complications arising from pelvic floor reconstruction of large defects after exenteration procedures, especially in previously irradiated settings. Further studies are necessary to define the long-term outcomes and indications of these techniques, as well as the optimal combination between the available myocutaneous flaps and prosthetic materials.

Key words: Vulvar canver; Exenteration; Pelvic floor reconstruction; Oblique rectus abdominis flap; Vicryl mesh.

Introduction

Pelvic exenteration is a radical surgical procedure involving en bloc resection of multiple viscera, located both in and out of the pelvis. This is followed by surgical reconstruction with the aim of restoring the perineal floor as well as the normal bodily functions of the organs removed. Since it was first reported in 1948 by Brunschwig for the treatment of persistent or recurrent gynecological cancer [1], improvements in critical care, antibiotics, hyperalimentation, and thromboembolism prophylaxis, accompanied by similar advances in surgical technique, including the use of stapling devices, separate urinary conduits, and pelvic reconstruction, have improved the morbidity and mortality rates associated with the procedure. Today, pelvic exenteration is still considered to be the only curative option in certain patients with centrally recurrent cervical, vaginal, or vulvar cancers or even for locally recurrent rectal cancers, especially following adjuvant chemotherapy and radiotherapy treatment. Despite the fact that mortality rates have dropped to an acceptable rate of 3-5%, the perioperative complication rate remains high at 30-44% [2]. This is probably due to the compromised healing of irradiated tissue as well as the use of intricate surgical reconstructive techniques [3].

The use of loco-regional tissue flaps to reconstruct the pelvic floor has been well established in patients with large perineal defects which cannot be closed primarily or whenever a huge noncollapsible dead space is left after the resection. Commonly used flaps for perineal reconstruction include the greater omentum, gracilis myocutaneous, posterior thigh and vertical or oblique rectus abdominis myocutaneous flaps (VRAM/ORAM) [4]. Moreover, there is great controversy concerning the adjuvant role of prosthetic materials in pelvic floor reconstruction surgery, as a means of reinforcement, with the aim of obliterating the possibility of complications [5]. However, there has been no unanimous agreement to date as to the optimal way to treat patients undergoing pelvic exenteration procedures.

We will hereby describe a novel reconstructive surgical technique of the pelvic floor, following antero-posterior pelvic exenteration in a 63-year-old woman with recurrent vulvar cancer, using both an ORAM flap and a synthetic absorbable mesh. Our goal in using this combined technique is to resolve most of the concerns regarding the possible complications of the common reconstruction procedures following pelvic exenteration.

Case Report

A 63-year-old female patient was referred to our hospital in January 2008 for treatment of a locally recurrent vulvar carcinoma, which was infiltrating both the urogenital and the anal perineal triangles. The patient had originally been diagnosed with vulvar carcinoma in 1995. She was then treated with vulvar excision and inguinal and femoral lymph node dissec-

Revised manuscript accepted for publication June 5, 2009

Fig. 1

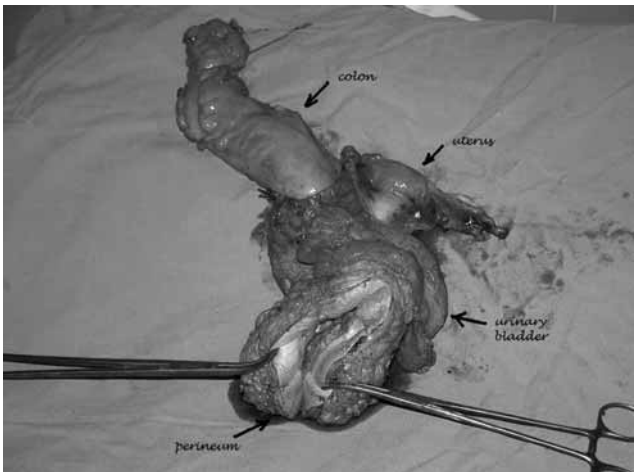

Fig. 2

Fig. 3

Figure 1. — View of the perineal floor before the patient's operation.

Figure 2. — The specimen comprising the colon, uterus, urinary bladder and perineal floor.

Figure 3. — View of the preoperative planning of the ORAM flap.

tion. Pathology of the specimen revealed a moderately to well differentiated squamous cell vulvar carcinoma, with negative resection margins and negative for metastases lymph nodes. The patient did not receive any adjuvant treatment and remained free of disease for 11 years. In 2006 she presented with a local recurrence of her vulvar carcinoma. She subsequently underwent an additional wide local excision with negative resection margins followed by adjuvant radiotherapy. One year later, in December 2007 the patient presented once more with a local recurrence of her disease, which was at this time complicated by the presence of a rectovaginal fistula (Figure 1). After a complete clinical and radiological workup it was decided to submit the patient to salvage surgical treatment through an antero-posterior exenteration, since her disease was found to be restricted in the pelvis.

The operation was carried out via a hypogastric and epigastric midline incision. After entering the peritoneal cavity, the resectability of the tumour as well as the macroscopic absence of distant metastases was assessed and confirmed. A laterally extended endopelvic resection was carried out consisting of a composite exenteration of the pelvic visceral compartments en bloc with the endopelvic parietal structures. Special attention was paid to performing a multimesovisceral exsicion, by including total mesorectal and mesometrial excision and removal of the ureteovesical compartment (Figure 2). The resection was completed through an additional perineal incision, which included the pelvic floor skin, from the pubic symphysis to the ischial tuberosity. Anorectal function was restored through a permanent left end colostomy and urethrovesical function was

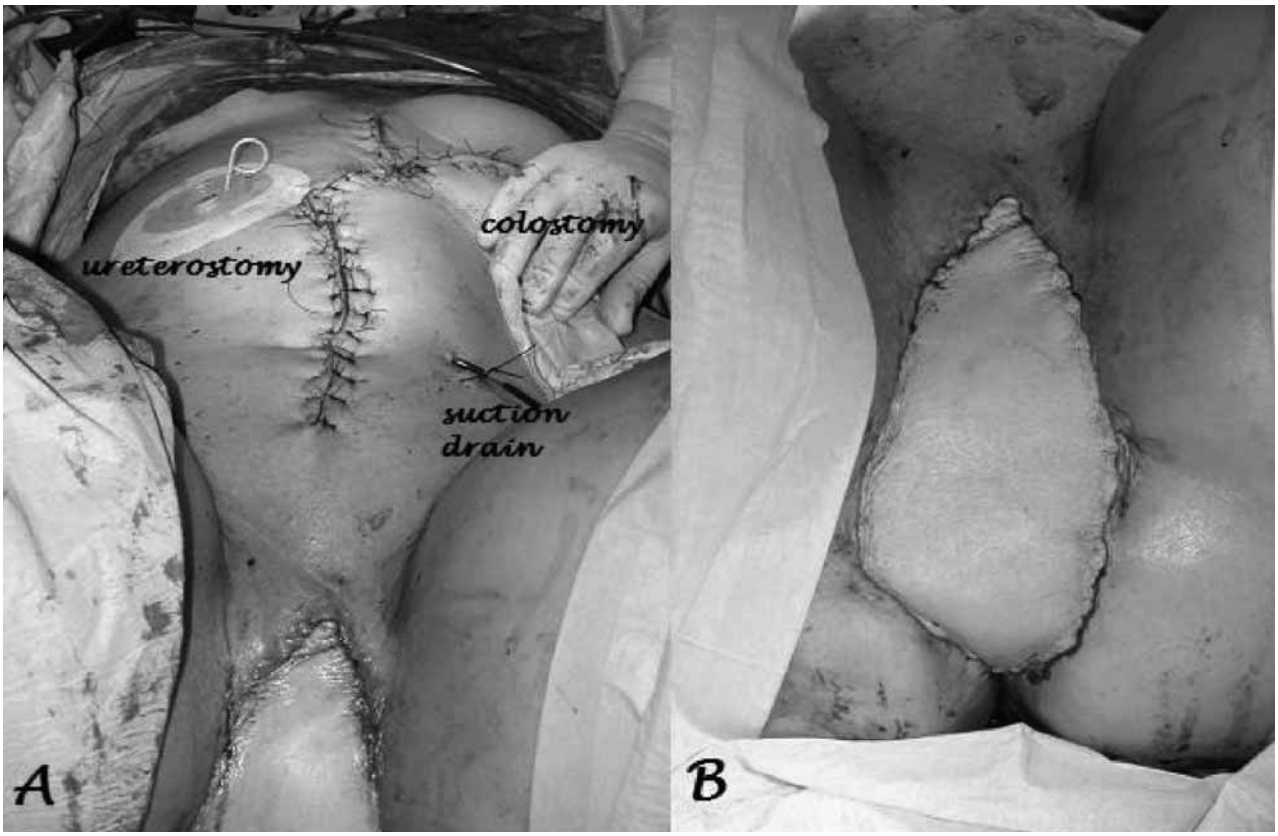

Figure 4. — A. Final view after completion of the operation. B. The ORAM flap at the completion of the operation.

restored with the formation of an eterotopic, right, incontinent neobladder, by use of an ileal conduit in which both the ureters were implanted.

Subsequently, attention was drawn to the reconstruction of the pelvic floor defect. In view of the fact that the patient had been previously subjected to regional lymphadenectomy and extensive radiotherapy of the region, she presented with widespread, longstanding lymphedema of the thighs. This immediately posed questions as to the suitability of a gracilis muscular flap. Moreover, considering the size of the pelvic defect, even preoperatively the decision was to use an oblique rectus abdominis flap for the pelvic floor reconstruction (Figure 3). The stoma sites had been marked preoperatively, and it was decided to utilise the left rectus abdominis muscle, since the patient already had a right paramedial incision from a previous open cholecystectomy. The flap was elevated from the subcutaneous adipose tissue of the anterior abdominal wall and its size was estimated to sufficiently cover the pelvic floor defect. The skin incisions were made, outlining the flap and they were carried down through the subcutaneous tissue to the oblique fascia. The flap was then dissected from the fascia and the deep inferior epigastric vessels were dissected with a fascial and muscle wrap to create a myocutaneous flap with a muscle band extending down to the pubic symphysis. This rectus abdominis wrap enveloping the inferior epigastric vessels serves as protection against extensive stretching and eventual compromise of the vascular pedicle during flap translocation to the perineum. The flap was ultimately inverted into the pelvis and was fashioned to match the pelvic wall defect.

In addition to this, an absorbable Vicryl mesh was utilized so as to reconstruct the pelvic peritoneal sling, with the aim of preventing the small bowel from coming in contact with the newly created pelvic floor. The mesh was anchored with sutures to the sacral promontory, the lateral pelvic wall and the symphysis pubis in order to close the pelvic brim, and a closed suction drain was left in the pelvic cavity. Both the abdominal and perineal skin incisions were closed primarily. Figure 4 demonstrates the final result of the abdominal and perineal trauma at the completion of the operation.

Pathological examination of the resected specimen revealed a moderately differentiated squamous cell vulvar carcinoma, 5 cm in diameter, which was infiltrating the outer urethra, the vaginal wall, and the anal canal wall as well as the perineum, with negative resection margins and lymph nodes. The uterus and ovaries as well as the urinary bladder were closely adherent to the vulvar carcinoma, but they were not invaded by it.

The patient recovered well from the surgery with no complications and was discharged three weeks later. However, she later on developed hepatic metastases and eventually succumbed to her disease six months after the operation.

Discussion

Pelvic exenteration is a radical surgical procedure most commonly used in cases of advanced or recurrent cancer, in which less radical options are not technically possible or would not be sufficient to remove the entire tumour. This procedure is performed for many types of cancer including genitourinary and colorectal cancers.

Considerable morbidity has been associated with the resultant large pelvic defect left after pelvic exenteration. Complications include pelvic abscess and/or fistula formation, intestinal obstruction and perineal wound problems. Therefore, a reliable pelvic floor reconstruction is critical after pelvic exenteration. Primary repair of the pelvic floor is most often unfeasible, but it is also imprudent, especially in previously irradiated tissues [6, 7]. Many different methods have been advocated to obliterate the large pelvic dead space left after pelvic exenteration. These include use of synthetic absorbable mesh, omentum or other autologous tissue. The use of well vascularised myocutaneous flaps has been shown to significantly reduce the rate of pelvic wound complications. The advantages of myocutaneous flap reconstruction include reduction of the pelvic dead space, interposition of well-vascularised, non-irradiated tissue and replacement of the resected skin [7]. Frequently used myocutaneous flaps are those based on the gracilis, gluteous maximus and rectus abdominis muscles, either with a vertical or an oblique flap [4, 8, 9-11]. In our patient, a choice was made to use the oblique rectus abdominis myovcuaneous flap (ORAM), taking into consideration the anticipated great size of the pelvic floor defect. Moreover, the lymphedema of the patient's thighs made the gracilis myocutaneous unsuitable in this case, although it is usually favoured whenever bilateral abdominal stomata are planned [3]. This ORAM flap is easy to rotate, it can be fashioned so as to fill the pelvic dead space completely and it can augment the perineal wound with well vascularized epithelium [11]. Its use has been associated with a favourable outcome as to the severity of postoperative complications. That is, it has been shown that the complications typically following ORAM flap reconstruction are less often life threatening, life altering or fatal [11].

However, even in the best case scenarios, the effort to reconstruct the pelvic floor after radiotherapy is rarely without complications. One of the major considerations of the surgical techniques utilised for pelvic floor reconstruction after pelvic exenteration or abdominoperineal resection is to provide optimal support for intraabdominal organs. In this perspective the use of prostheses in pelvic floor reconstruction has been investigated. Many different surgical procedures have been designed to prevent the small bowel from coming in contact with the pelvic floor. Most often they are used to prevent radiation – induced bowel injury associated with pelvic postoperative radiotherapy and in pelvic prolapse surgery. The idea is to create an artificial sling which can close the pelvic brim, and recreate the peritoneal pelvic layer. The mesh can serve as additional supportive tissue or as a way of reinforcing inadequate or unsuitable tissue, it can induce new supportive tissue growth and it can be combined with other surgical techniques, whenever there are concerns that these will prove inadequate [5]. The prosthetic materials used today are either synthetic (absorbable, non-absorbable or mixed) or biological (autologous, allograft or xenograft donor tissue). Non-absorbable mesh reconstruction has been more or less abandoned due to the high rate of complications (mesh erosion, enteric fistula formation, etc). The two most common types of absorbable mesh slings are Polygalactin 910 (Vicryl; Ethicon, Sommerville, NJ, USA) and Polyglycolic acid (Dexon; Davis & Geck Co, Danbury, CO, USA) [12-14]. Bioprosthetic materials have also been used, such as autologous fascia lata from the lateral thigh, human acellular dermal matrix [6] and xenograft donor tissue, such as porcine small intestinal submucosa mesh [15].

There have been a few reports of simultaneous use of both a myocutaneous flap and prosthetic mesh in reconstructing the pelvic floor after pelvic exentaration [2, 6]. To our knowledge, this is the first case in which a biodegradable synthetic mesh has been used to create a pelvic sling in combination with ORAM flap reconstruction. The surgeon's choice of the absorbable Vicryl mesh was based on the fact that the time period of 90 to 120 days, which is necessary for the mesh to dissolve completely, would be more than sufficient to ensure the ORAM flap viability by preventing the small bowel to fall back in the pelvis. Furthermore, the mesh can promote host connective and epithelial tissue growth and differentiation, resulting in the formation of a novel natural pelvic sling lasting long after the mesh has been absorbed.

In conclusion, the combined utilisation of myocutaneous flaps and prosthetic mesh material can provide an effective alternative solution to the complications arising from pelvic floor reconstruction of large defects after exenteration procedures, especially in previously irradiated settings. Defining the most advantageous technique for pelvic floor reconstruction after anteroposterior exenteration for recurrent carcinoma, however, will necessitate additional studies to evaluate the long-term outcomes of this technique compared with traditional reconstructive surgical procedures. The indications, contraindications and possible complications of this technique should be determined in a series of patients, and the role of various prosthetic materials and different myocutaneous flaps should be thoroughly explored to provide patients undergoing pelvic exenteration with the optimum reconstructive option.

References

[1] Brunschwig A.: "Complete excision of pelvic viscera for advanced carcinoma; a one-stage abdominoperineal operation with end colostomy and bilateral ureteral implantation into the colon above the colostomy". *Cancer,* 1948, *1,* 177.

[2] Goldberg G.L., Sukumvanich P., Einstein M.H., Smith H.O., Anderson P.S., Fields A.L.: "Total pelvic exenteration: the Albert Einstein College of Medicine/Montefiore Medical Center Experience (1987 to 2003)". *Gynecol. Oncol.*, 2006, *101*, 261.

[3] Höckel M., Dornhöfer N.: "Pelvic exenteration for gynaecological tumours: achievements and unanswered questions". *Lancet Oncol.*, 2006, *7,* 837.

[4] Butler C., Gündeslioglu Ö., Rodriguez-Bigas M.: "Outcomes of immediate vertical rectus abdominis myocutaneous flap reconstruction for irradiated abdominoperineal resection defects". *J. Am. Coll. Surg.*, 2008, *206*, 694.

[5] Wu M.P.: "The use of prostheses in pelvic reconstructive surgery: joy or toy?". *Taiwan J. Obstet. Gynecol.*, 2008, *47,* 151.

[6] Said H.K., Bevers M., Butler C.: "Reconstruction of the pelvic floor and perineum with human acellular dermal matrix and thigh flaps following pelvic exenteration". *Gynecol. Oncol.,* 2007, *107,* 578.
[7] Pawlik T.M., Skibber J.M., Rodriguez-Bigas M.A.: "Pelvic exenteration for advanced pelvic malignancies". *Ann. Surg. Oncol.*, 2006, *13*, 612.
[8] Vermaas M., Ferenschild F.T.J., Hofer S.O.P., Verhoef C., Eggermont A.M.M., de Wilt J.H.W.: "Primary and secondary reconstruction after surgery of the irradiated pelvis using a gracilis muscle flap transposition". *Eur. J. Surg. Oncol.*, 2005, *31*, 1000.
[9] Hsu H., Lin C.M., Sun T.B., Cheng L.F., Chien S.H.: "Unilateral gracilis myofasciocutaneous advancement flap for single stage reconstruction of scrotal and perineal defects". *J. Plast. Reconstr. Aesthet Surg.*, 2007, *60*, 1055.
[10] Tei T.M., Stolzenburg T., Buntzen S., Laurberg S., Kjeldsen H.: "Use of transpelvic rectus abdominis musculocutaneous flap for anal cancer salvage surgery". *Br. J. Surg.*, 2003, *90*, 575.
[11] Abbott D.E., Halverson A.L., Wayne J.D., Kim J.Y.S., Talamonti M.S., Dumanian G.A.: "The oblique rectus abdominal myocutaneous flap for complex pelvic wound reconstruction". *Dis. Colon Rectum.,* 2008, *51*, 1237.
[12] Hoffman M.S., Roberts W.S., LaPolla J.P., Fiorica J.V., Cavanagh D.: "Use of Vicryl mesh in the reconstruction of the pelvic floor following exenteration". *Gynecol. Oncol.*, 1989, *35*, 170.
[13] Buchsbaum H.J., Christopherson W., Lifshitz S., Bernstein S.: "Vicryl mesh in pelvic floor reconstruction". *Arch. Surg.*, 1985, *120,* 1389.
[14] Rodier J.F., Janser J.C., Delahaye J.F., Rodier D.: "Use of polyglactin 910 mesh (Vicryl) in pelvic oncologic surgery". *Adv. Ther.*, 1992, *9*, 233.
[15] Al-Sahaf O., El-Masry S.: "The use of porcine small intestinal submucosa mesh (SURGISIS) as a pelvic sling in a man and a woman with previous pelvic surgery: two case reports". *J. Med. Case Reports*, 2009, *3*, 70.

Address reprint requests to:
M.A. Kyriazi, M.D
2nd Department of Surgery
Areteion Hospital
University of Athens Medical School
17 Efpatorias str.
11522 Athens (Greece)
e-mail: mkyriazi@otenet.gr