EJGO European Journal of Gynaecological Oncology

Diagnostic accuracy of 1.5 Tesla breast magnetic resonance imaging in the pre-operative assessment of axillary lymph nodes

C. de Felice[1], V. Cipolla[1], A. Stagnitti[1], L.M. Porfiri[1], D. Guerrieri[1], A. Musella[2], D. Santucci[1], M.L. Meggiorini[2]

[1] *Department of Radiological Sciences, University of Rome "Sapienza", Rome*
[2] *Department of Gynaecological Sciences, University of Rome "Sapienza", Rome (Italy)*

Summary

The purpose of this study was to test the accuracy of 1.5 Tesla magnetic resonance imaging (1.5T MRI) in the preoperative evaluation of axillary lymph nodes in patients with invasive breast cancer. The authors retrospectively analyzed 26 patients with invasive breast cancer who had undergone sentinel lymph node biopsy (SLNB) and/or axillary lymph node dissection (ALND). All patients had been submitted to preoperative contrast enhanced breast 1.5T MRI. On the basis of lymph nodes morphological and dynamic characteristics, lymph nodes were classified as "negative" (short axis < 5 mm), "borderline" (short axis > 5 mm, absence of a hilum) or "positive" (short axis > 5 mm, absence of a hilum and also other suspicious features). The authors compared 1.5T MRI results with the outcome of histological analysis performed according to the TNM criteria; sensitivity (SE), specificity (SP), positive predictive value (PPV), and negative predictive value (NPV) of 1.5T MRI were evaluated. Considering only the lymph nodes "positive", 1.5 T MRI showed: SE 37.8%, SP 99.3%, FP 0.7%, PPV 92.5%, and NPV 88.1%. However, considering also "borderline", 1.5T MRI achieved: SE 75.7%, SP 99.3%, FP 0.7%, PPV 96.1%, and NPV was 95%. Contrast enhanced breast 1.5T MRI is not yet a valid alternative to histological analysis but it is a valid tool for a preoperative study of the topography of axillary lymph nodes and has the potential to become a routine method for evaluating the metastatic lymph nodes before submission to ALND.

Key words: Breast cancer; Axillary lymph nodes; Magnetic resonance imaging.

Introduction

Axillary lymph node status is one of the most important prognostic factors in patients with breast cancer [1-5]. For an accurate staging and prognosis, axillary lymph node dissection (ALND) with removal of at least ten lymph nodes is currently recommended [6]. However, this procedure may lead to side effects such as lymphedema, seroma, numbness of the arm, infection, pain, and damage to the motor nerve resulting in decreased mobility and impaired quality of life [6-18]. Screening and early detection of breast cancer, while the disease may still not have spread through the lymphatic system, have led to the development of sentinel lymph node biopsy (SLNB) to reduce morbidity linked to ALND [2, 19]. In patients with clinically negative axilla and early stage breast cancer, SLNB has thus become a standard procedure as it permits selective ALND in patients with sentinel lymph node metastases [20].

The purpose of this study was to test the diagnostic accuracy of 1.5 Tesla magnetic resonance imaging (1.5T MRI) in the preoperative evaluation of axillary lymph nodes in patients with invasive breast cancer.

Materials and Methods

In this retrospective study, the authors reviewed all MRI examinations performed between December 2008 and December 2009 for local staging of breast cancer at the Department of Radiological Sciences, University of Rome "Sapienza".

Only patients who met the following inclusion criteria were enrolled in the study: (a) contrast enhanced 1.5T MRI of the breast was performed at a maximum of 30 days before surgery; (b) diagnosis of breast cancer was confirmed by histological analysis after surgery performed in our Department of Obstetrics, Gynaecology and Urological Sciences; (c) ALND was performed due to the presence of clinically palpable lymph nodes or previous SLNB. Patients whose images were not of a good diagnostic quality were excluded from the study.

At the time of enrollment, the following information was collected: TNM classification, histological tumor type, tumor cell grading (G), angioinvasion, hormone receptor status (ER, PgR, Her2), Ki-67 protein expression, total number of lymph nodes removed, and number of metastatic lymph nodes. Histological evaluation of lymph nodes was performed according to the TNM criteria (sixth edition).

The American Joint Committee on Cancer (AJCC) staging system classifies metastases as follows:

– isolated tumor cells (ITC) (pN0) defined as small groups of metastatic cells measuring ≤ 0.2 mm in greatest dimension or as a group of cells < 200 units in a single histological section [21].

Revised manuscript accepted for publication March 27, 2014

7847050 Canada Inc.
www.irog.net

– micrometastasis (pNlmi): > 200 metastatic cells or one metastasis measuring 0.2 to two mm in greatest dimension [21,22].
– macrometastasis: measuring > two mm in greatest dimension [22, 23].

Lymph nodes negative for malignancy, lymph nodes with ITC, and lymph nodes with micrometastases were classified as "negative" according to the meta-analysis published by Bilimoria *et al.*, who concluded that these types of lymph nodes have no influence on the choice of treatment [24].

All MRI examinations were performed using a 1.5T magnet and a dedicated four-channel breast coil with the patient in the prone position. Image acquisition was carried out in accordance with the international guidelines issued by the European Society of Breast Imaging [25]. After localizer sequences in three orthogonal planes, the following sequences were acquired:

– axial T2-weighted short-time inversion recovery (TIRM) sequences (repetition time (TR)/echo time (TE) 6000/140 ms, field of view (FOV) = 340 x 340, slice thickness: four mm, matrix 320 x 190, NEX 2.00);
– axial T1-weighted fast spin echo (FSE) sequences (TR/TE 467/9.9 ms, FOV = 380 x 380, slice thickness: four mm, matrix 320 x 224, NEX 1.00);
– axial T1-weighted FLASH 3D Dynamic (FL 3D DYN) sequences in the axial plane, before and five times after contrast administration (TR/TE 5.8/2.8 ms, FOV 380 x 380, slice thickness: two mm, matrix 320 x 320, NEX 1.00).

Contrast medium was gadobenate-dimeglumine administered in a concentration of 0.2 mmol/kg injected through a 20 G intravenous cannula at the rate of two ml/sec using an automatic injector, followed by infusion of 20 ml saline solution at the same speed.

– Sagittal fat-saturated T1-weighted FSE sequence (TR/TE 467/9.9 ms, FOV = 112 x 320, slice thickness: five mm, matrix 320 x 224, NEX 1.00);

Image post-processing included temporal subtraction (contrast-enhanced minus unenhanced image) of dynamic studies with fat saturation. MR images were interpreted retrospectively by two radiologists in consensus using the picture archiving and communication system which allows 3D maximum intensity projections (MIP) of the dynamic sequences and manual selection of the window. Both radiologists were familiar with the patient's clinical history and had reviewed all previous mammograms and ultrasound images.

A predictive model was hypothesized according to the parameters for metastatic lymph node involvement reported in the literature [26], and lymph nodes were classified as "negative", "borderline" or "positive":

Depending on the length of the short axis, the lymph nodes were divided into two categories: lymph nodes with a short axis < five mm and lymph nodes with a short axis ≥ five mm.

Lymph nodes with a short axis < five mm were interpreted as "negative", i.e. not invaded by macrometastases. Lymph nodes with a short axis ≥ five mm were studied for the following parameters:

A) Presence or absence of a discernible hilum.
B) Other morphological or dynamic changes such as shape (round or oval), margins (regular or irregular), cortex (homogeneous if C-shaped and thickness < three mm and inhomogeneous if not C-shaped and thickness ≥ three mm), perifocal edema (presence or absence of hyperintense signal from the tissue around the lymph node on T2-weighted images), symmetry (presence or absence of difference between lymph node distribution in the axilla near the affected breast and the contralateral axilla), and enhancement (presence or absence of contrast uptake in the peripheral portion of the lymph node on T1-weighted sequences after injection of contrast agent).

Lymph nodes with a short axis ≥ five mm and absence of a hilum but no other morphological or dynamic changes were classified as borderline" [23].

Lymph nodes with a short axis ≥ five mm, absence of a discernible hilum and other suspicious features, such as round shape, irregular margins, not C-shaped and cortical thickening, perifocal edema, asymmetry in lymph node distribution between the axilla near the affected breast and the contralateral axilla and/or ring enhancement, were classified as "positive".

In order to assess the accuracy of the method, 1.5T MRI results were compared with the outcome of histological analysis after ALND and/or SLNB, and sensitivity (SE), specificity (SP), positive predictive value (PPV) and negative predictive value (NPV) were analyzed.

Results

Of the 66 pre-surgical breast MRI examinations which were reviewed, 17 were excluded as no suspicious abnormality was visible on the dynamic images, 15 were excluded because the patients were lost to the present institution, six were excluded because it was not possible to assess axillary lymph nodes on the images, as MRI had been performed to study the primary tumor and not the axilla, and two were excluded because the images presented motion artifacts.

A total of 26 patients met the selection criteria and were included in this retrospective study. Mean age of the patients was 56 years (range 40-65); 17 patients (65.4%) were postmenopausal and nine patients (34.6%) were premenopausal.

Histopathological analysis of the surgical specimens showed that 14 patients had carcinoma Stage T1, nine had carcinoma Stage T2, and three had carcinoma Stage T3. Histological analysis furthermore showed that 20 patients had invasive ductal carcinoma, two had invasive lobular carcinoma, and four had mixed ductal-lobular carcinoma. With regards to hormone receptor status, 11 patients had Luminal A tumor, eight had Luminal B tumor, four had triple-negative tumor, and the remaining three patients had Her2 overexpression tumor. Tumors were graded as follows: four patients had grade 1 tumors, ten had grade 2 tumors, and 12 had grade 3 tumors. Mean tumor size was 23 mm in diameter (range 7-80). According to the TNM staging system, 20 patients were staged N1 and six were staged N2.

The total number of removed lymph nodes was 372 of which 66 proved to be metastatic at histological analysis while 306 were non-metastatic. MRI identified 52 affected lymph nodes of which 27 were classified as "borderline" and 25 as "positive" (Figure 1).

MRI evidenced round shape in 21 cases (40.3%), irregular lymph node margins in 14 cases (26.9%), not C-shaped and cortical thickening in 20 cases (38.4%), and ring enhancement in 16 cases (30.7%). There was asymmetry in lymph node distribution between the axilla near the affected breast and the contralateral axilla in four cases (15.4%). No lymph nodes presented perifocal edema.

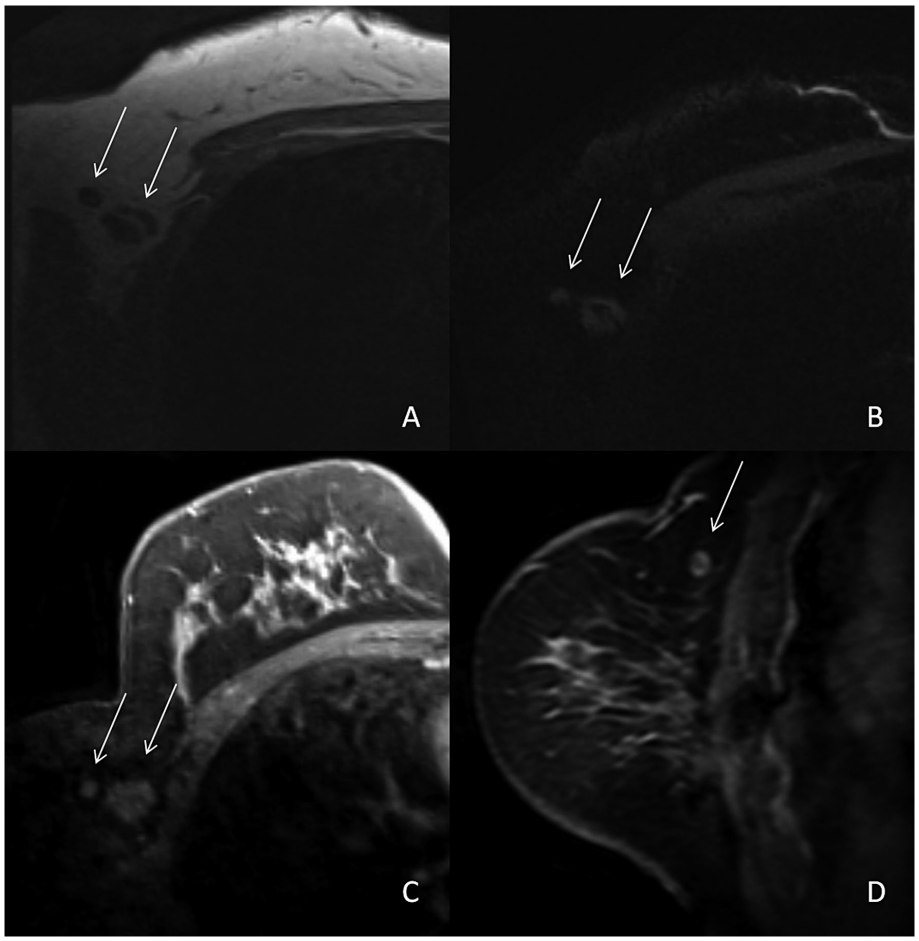

Figure 1. — Lymph nodes classified as "positive" at contrast enhanced 1.5T MRI due to short axis ≥ 5 mm, no discernible hilum, irregular margins, inhomogeneous cortex and contrast enhancement. A) T1-weighted TSE sequence; B) T2-weighted TIRM sequences; C) 3D T1-weighted FLASH after contrast injection; D) sagittal fat-saturated T1-weighted FSE sequence after contrast injection.

Sixteen lymph nodes (30.7%) classified as "negative" at MRI according to the described criteria were identified as metastatic at histological examination, while two lymph nodes classified as "positive" at MRI were classified as "negative" at histological analysis.

Considering as metastatic only the lymph nodes classified as "positive" and comparing the result of breast MRI with histological outcome after ALND and/or SLNB, 1.5 T MRI proved to have a SE of 37.8% and a SP of 99.3%. False positive rate was 0.7%, PPV 92.5%, and NPV 88.1%.

However, considering as metastatic lymph nodes also those classified as "borderline", 1.5T MRI achieved a SE of 75.7% and SP of 99.3%. False positive rate was 0.7%, PPV was close to 96.1%, and NPV was 95%

Comparison between lymph node features detected at 1.5T MRI and histological outcome revealed that the following MRI findings occurred at a greater frequency in metastatic lymph nodes: no discernible hilum (80.7 % of metastatic lymph nodes), round shape (40.3% of metastatic lymph nodes), and cortical thickening (38.4% of metastatic lymph nodes).

Discussion

In patients with breast cancer, the surgeon currently has to perform a careful preoperative clinical evaluation of the axilla in order to plan SLNB or ALND, as ALND and to a lesser extent SLNB, may lead to sequelae, particularly lymphedema and functional neurological deficit [27-29]. However, clinical examination has a low SP in the preoperative evaluation, and histological analysis confirms malignancy of palpable lymph nodes in less than 50% of cases.

Non-invasive diagnostic methods have improved in recent years, and MRI may become the imaging technique of choice in the evaluation of axillary lymph nodes. This technique has several advantages: it is operator-independent and it allows revaluation over time as it is not a real-time examination like US imaging. MRI furthermore provides visualization of the axilla on several levels.

The aim of this study was to test the accuracy of 1.5T MRI in the preoperative assessment of axillary lymph nodes using a predictive model for MRI evaluation of axillary lymph nodes in breast cancer. In order to do this, morphological and dynamic criteria were established. On the basis of these parameters, a predictive model was hypoth-

esized, and the detected lymph nodes were classified as "negative", "borderline" or "positive".

When only the "positive" lymph nodes were considered as metastatic, SE was very low as only 37.8% proved to be metastasis positive at histologic examination, while 0.5% were false positive. Considering as metastatic lymph nodes also those classified as "borderline", MRI achieved higher values including a SE of 75.7%. Also, PPV and NPV were higher when "borderline" lymph nodes were classified as metastatic (92.5% *vs* 96.1% and 88.1% *vs* 95%, respectively).

1.5 T MRI thus achieved a high SP in the detection of metastatic lymph nodes (99.3% both when "positive " only and when "positive " and "borderline" were considered as metastatic). SP is perhaps the most important parameter for evaluating an imaging technique, as the main objective is not to reduce the risk of overtreatment but to avoid undertreatment.

SE achieved in this study was in agreement with the values reported in the literature [30, 31]. The present results show that lymph nodes with a short axis measuring ≥ five mm, no discernible hilum, and at least one additional suspicious finding (most frequently round shape and cortical thickening) has a high probability of being metastatic. This suggests that lymph nodes classified as "borderline" on the basis of the predictive model proposed in this study should be considered as metastatic.

Today, treatment of patients with breast cancer and metastatic lymph nodes has greatly improved. The Z0011 study confirmed the usefulness of conservative surgery in selected patients with early stage breast cancer and a maximum of two macrometastatic lymph nodes [26]. The authors furthermore stated that ALND could be omitted without compromising overall survival in these patients. However, ALND is currently recommended in all patients who do not meet the selection criteria reported in the Z0011 study, i.e., mastectomized patients, patients with a single metastatic sentinel lymph node, undergoing neoadjuvant chemotherapy, and patients undergoing partial breast irradiation.

The outcome of the present study shows that 1.5 MRI can support management decisions in patients in whom ALDN is currently recommended. A limitation of this study is that lymph node assessment was not possible in six patients due to partial visualization of the axilla; however future investigation focused on the axillary will solve this problem. In two patients the images showed motion artifacts caused by breathing movements affecting the uptake of contrast agent.

Further studies are required to confirm the predictive value of 1.5T MRI in the preoperative evaluation of axillary lymph nodes using an appropriate evaluation model. However, the improved quality of images obtained using 3 Tesla (3T) MRI and diffusion-weighted imaging (DWI) may further refine this technique. The greater spatial and contrast resolution of 3T MRI can provide a more accurate evaluation of lymph nodes, and DWI sequences can add information about the microscopic cellular environment and tumor cellularity [32].

Conclusions

Despite the accuracy of the method, contrast enhanced breast 1.5 T MRI is not yet a sufficiently valid alternative to histological analysis. The SP of 1.5T MRI is high, and only 3.8% of lymph nodes classified as "negative" according to the described criteria were identified as metastatic lymph nodes at histological examination. However, the low SE negatively affects the value of this method as a decision making tool before ALND.

Nevertheless, MRI is a valid method for studying the topography of axillary lymph nodes, and it has the potential to become a routine tool for evaluating the axilla in patients with metastatic sentinel lymph nodes before submission to ALND [25].

Future studies using 3T MRI and DWI sequences may provide a greater diagnostic accuracy than the accuracy reported in this paper. Detailed information on the status of axillary lymph nodes before surgery can help a multidisciplinary team to improve the treatment of breast cancer patients.

References

[1] Nemoto T., Vana J., Bedwani R.N., Baker H.W., McGregor F.H., Murphy G.P.: "Management and survival of female breast cancer: results of a national survey by the American College of Surgeons". *Cancer*, 1980, *45*, 2917.

[2] Carter C.L., Allen C., Henson D.E.: "Relation of tumor size, lymph node status, and survival in 24,740 breast cancer cases". *Cancer*, 1989, *63*, 181.

[3] Clayton F., Hopkins C.L.: "Pathologic correlates of prognosis in lymph node-positive breast carcinomas". *Cancer*, 1993, *71*, 1780

[4] Moore M.P., Kinne D.W.: "Axillary lymphadenectomy: a diagnostic and therapeutic procedure". *J. Surg. Oncol.*, 1997, *66*, 2.

[5] Silverstein M.J., Skinner K.A., Lomis T.J.: "Predicting axillary nodal positivity in 2282 patients with breast carcinoma". *World J. Surg.*, 2001, *25*, 767.

[6] Kiricuta C.I., Tausch J.: "A mathematical model of axillary lymph node involvement based on 1446 complete axillary dissections in patients with breast carcinoma". *Cancer*, 1992, *69*, 2496.

[7] Lotze M.T., Duncan M.A., Gerber L.H., Woltering E.A., Rosenberg S.A.: "Early versus delayed shoulder motion following axillary dissection: a randomized prospective study". Ann. Surg., 1981, *193*, 288.

[8] Yeoh E.K., Denham J.W., Davies S.A., Spittle M.F.: "Primary breast cancer. Complications of axillary management". *Acta Radiol. Oncol.*, 1986, *25*, 105.

[9] Siegel B.M., Mayzel K.A., Love S.M.: "Level I and II axillary dissection in the treatment of early-stage breast cancer. An analysis of 259 consecutive patients". *Arch. Surg.*, 1990, *125*, 1144.

[10] Shaw J.H., Rumball E.M.: "Complications and local recurrence following lymphadenectomy". *Br. J. Surg.*, 1990, *77*, 760.

[11] Ivens D., Hoe A.L., Podd T.J., Hamilton C.R., Taylor I., Royle G.T.: "Assessment of morbidity from complete axillary dissection". *Br. J. Cancer*, 1992, *66*, 136.

[12] Lin P.P., Allison D.C., Wainstock J., Miller K.D., Dooley W.C., Friedman N., *et al.*: "Impact of axillary lymph node dissection on the therapy of breast cancer patients". *J. Clin. Oncol.*, 1993, *11*, 1536.

[13] Maunsell E., Brisson J., Deschênes L.: "Arm problems and psychological distress after surgery for breast cancer". *Can. J. Surg.*, 1993, *36*, 315.
[14] Hack T.F., Cohen L., Katz J., Robson L.S., Goss, P.: "Physical and psychological morbidity after axillary lymph node dissection for breast cancer". *J. Clin. Oncol.*, 1999, *17*, 143.
[15] Velanovich V., Szymanski W.: "Quality of life of breast cancer patients with lymphedema". *Am. J. Surg.*, 1999, *177*, 184.
[16] Veronesi U., Paganelli G., Viale G., Luini A., Zurrida S., Galimberti V., *et al*.: "A randomized comparison of sentinel-node biopsy with routine axillary dissection in breast cancer". *N. Engl. J. Med.,* 2003, *349*, 546.
[17] Lucci A., McCall L.M., Beitsch P.D., Whitworth P.W., Reintgen D. S., Blumencranz P.W. *et al.*: "Surgical complications associated with sentinel lymph node dissection (SLND) plus axillary lymph node dissection compared with SLND alone in the American College of Surgeons Oncology Group Trial Z0011". *J. Clin. Oncol.*, 2007, *25*, 3657.
[18] Krag D.N., Anderson S.J., Julian T.B., Brown A.M., Harlow S.P., Costantino J.P., *et al*.: "Sentinel-lymph-node resection compared with conventional axillary-lymph-node dissection in clinically node-negative patients with breast cancer: overall survival findings from the NSABP B-32 randomised phase 3 trial". *Lancet Oncol.,* 2010, *11*, 927.
[19] Davies G.C., Millis R.R., Hayward J.L.: "Assessment of axillary lymph node status". *Ann. Surg.*, 1980, *192*, 148.
[20] Lyman G.H., Giuliano A.E., Somerfield M.R., Benson A.B. 3rd, Bodurka D.C., Burstein H.J. *et al.*: "American Society of Clinical Oncology guideline recommendations for sentinel lymph node biopsy in early-stage breast cancer". *J. Clin. Oncol.*, 2005, *23*, 7703.
[21] Edge S.B., Byrd D.R., Compton C.C., Fritz A.G., Greene F.L. Trotti A., (eds): "AJCC Cancer Staging Handbook", 7th ed. New York: Springer, 2011.
[22] Greene F.L., Page D.L., Fleming I.D., Fritz A., Balch C.M., Haller D.G., Morrow M., (eds): "AJCC Cancer Staging Manual", 6th ed. New York: Springer, 2002.
[23] Sobin L.H., Gospodarowicz M.K., Wittekind C., (eds): "International Union Against Cancer. TNM Classification of Malignant Tumours", 6th ed. New York: Wiley-Blackwell, 2009.
[24] Bilimoria K.Y., Bentrem D.J., Hansen N.M., Bethke K.P., Rademaker A.W., Ko C.Y., *et al*.: "Comparison of sentinel lymph node biopsy alone and completion axillary lymph node dissection for node-positive breast cancer". *J. Clin. Oncol.,* 2009, *27*, 2946.
[25] Mann R.M., Kuhl C.K., Kinkel K., Boetes C.: "Breast MRI: guidelines from the European Society of Breast Imaging". *Eur. Radiol.*, 2008, *18*, 1307.
[26] Giuliano A.E., McCall L., Beitsch P., Whitworth P.W., Blumencranz P., Leitch A.M., *et al.:* "Locoregional recurrence after sentinel lymph node dissection with or without axillary dissection in patients with sentinel lymph node metastases: the American College of Surgeons Oncology Group Z0011 randomized trial". *Ann. Surg.*, 2010, *252*, 426.
[27] Diaconu C., Livadariu R.M., Dogaru C.: "The risk of lymphedema after breast cancer surgical treatment". *Rev. Med. Chir. Soc. Med. Nat. Iasi.*, 2012, *116*, 1081.
[28] Hayes S. C., Johansson K., Stout N.L., Prosnitz R., Armer J.M., Gabram S., *et al*.: "Upper-body morbidity after breast cancer: incidence and evidence for evaluation, prevention, and management within a prospective surveillance model of care". *Cancer*, 2012, *118*, 2237.
[29] Sayko O., Pezzin L. E., Yen T.W.F., Nattinger A.B.: "Diagnosis and treatment of lymphedema after breast cancer: a population-based study". *PM R.*, 2013, *5*, 915. doi: 10.1016/j.pmrj.2013.05.005. Epub 2013 May 17.
[30] Kvistad K.A., Rydland J., Smethurst H.B., Lundgren S., Fjøsne H.E., *et al*.: "Axillary lymph node metastases in breast cancer: preoperative detection with dynamic contrast-enhanced MRI". *Eur. Radiol.*, 2000, *10*, 1464,
[31] Scaranelo A.M., Eiada R., Jacks L.M., Kulkarni S.R., Crystal P.: "Accuracy of unenhanced MR imaging in the detection of axillary lymph node metastasis: study of reproducibility and reliability". *Radiology*, 2012, *262*, 425.
[32] Matsuoka A., Minato M., Harada M., Kubo H., Bandou Y., Tangoku A., *et al.*: "Comparison of 3.0-and 1.5-tesla diffusion-weighted imaging in the visibility of breast cancer". *Radiat. Med.*, 2008, *26*, 15.

Address reprint requests to:
M.L. MEGGIORINI, M.D.
Department of Gynaecological Sciences,
University of Rome "Sapienza"
Viale del Policlinico, 155
00161 Rome (Italy)
e-mail: marialetizia.meggiorini@uniroma1.it