EJGO European Journal of Gynaecological Oncology

Ultrasound and X-ray performance of breast carcinosarcoma

Zhi-Ying Jia[1], Xiu-Qing Ai[2], Yin-Hua Zhang[3], Li Li[4], Fu-Cheng Ma[1]

[1]Department of Ultrasound, [2]Department of Breast Radiotherapy, [3]Department of Pathology, [4]Department of Radiology, The Affiliated Tumor Hospital of Xinjiang Medical University, Urumqi (China)

Summary

Objective: In this study, the authors investigated the ultrasonic and X-ray performance of this disease, and evaluated the value of routine imaging methods in the diagnosis of breast carcinosarcoma. *Materials and Methods:* Nine female patients with breast carcinosarcoma were enrolled. Ultrasound and X-ray are commonly used imaging methods for the diagnosis of breast diseases. Hence, the ultrasonic appearance and X-ray features of these nine cases of breast carcinosarcoma were retrospective analyzed, and the imaging features of carcinosarcoma were summarized based on pathological changes. *Results:* The pathological histology and immunohistochemical findings of these nine cases of breast carcinosarcoma revealed that five cases were epithelium-derived malignant tumors and four cases were mesenchymal metaplasia. Axillary lymph node metastasis was not found in any of these cases. Before surgery, ultrasound diagnoses included six cases of breast cancer, one case of phyllodes tumor, and two cases of fibroadenoma; while breast X-ray diagnoses included one case of fibroadenoma, two cases of suspected malignant tumors, four cases of breast cancer, and two cases of phyllodes tumor. Furthermore, ultrasound imaging revealed tumors with irregular shapes in six cases, internal liquefaction necrosis in four cases, internal calcification in two cases, and posterior echo enhancement in seven cases; while breast X-ray revealed lobulated changes on the margins in six cases, irregular tumors with horn-shaped protrusions in three cases, and internal calcification in six cases. *Conclusion:* It is difficult to diagnose breast carcinosarcoma by imaging methods, and puncture biopsy is an important method for preoperative diagnosis.

Key words: Breast; Carcinosarcoma; Ultrasonography; Mammography.

Introduction

The incidence of breast cancer has annually increased, and is the main malignant tumor that threatens the life and health of women in recent years. The etiology of this disease remains unknown, and its incidence is only second to cervical cancer [1, 2], accounting for 23.3% of all malignant tumors in women [3]. According to one report, in 2015, approximately 40,000 people died of breast cancer in the United States [4]. Pathological types of breast cancer are complex, in which most are epithelium-derived and 70-80% of cases are invasive ductal carcinoma [5]. The final diagnosis depends on histopathology and immunohistochemistry results [6].

Ultrasound and X-ray has been widely used in breast cancer screening and diagnosis worldwide. Before surgery, majority of breast cancers can be correctly diagnosed solely by ultrasound or X-ray examination [6], and the combination of these two methods can improve the detection rate of breast cancer [7]. The accuracy rate of X-ray for the diagnosis of breast cancer is 80-90%, allowing to detect more early breast cancers, compared with ultrasound [8]. However, through this method, it is easy to overestimate the tumor size [9]. The accuracy rate of ultrasound diagnosis for breast cancer is 80-85%, allowing it to more accurately estimate the tumor size [5]. Thus, this method is especially suitable for the examination of dense breasts [10]. Since the 1980s, with the rapid development of medical science and technology, the clinical treatment of breast cancer has become more mature [11]; and many breast cancer patients are able to survive for a long period of time after treatment.

Metaplastic carcinoma with mesenchymal metaplasia is a subtype of non-special metaplastic carcinoma of the breast, which is also called breast carcinosarcoma, and is a rare malignant tumor of the breast [12]. It is characterized by the differentiation of the neoplastic epithelium into squamous cells and mesenchymal components, has a high degree of malignancy, and is easy to be confounded with breast phyllodes tumor, invasive breast cancer, and metastatic tumor. Hence, preoperative diagnostic accuracy is low. In this study, the data of nine cases of breast carcinosarcoma were collected, and ultrasound and X-ray performance were retrospectively analyzed.

Materials and Methods

The data of nine cases of hospitalized patients in the present hospital during 2010-2016 were collected; all these cases were primary breast carcinosarcoma. Among these cases, five cases were of Han origin, three cases were of Uyghur origin, and one case was of Hui origin. The age of these patients ranged between 42-78 years old, with an average age of 56.89 ± 10.59 years old. The clinical complaint was painless breast phyma, and the duration of the disease ranged between three days to eight months. In seven cases, the phymas was found to be hard by palpation, and

Revised manuscript accepted for publication September 19, 2017

7847050 Canada Inc.
www.irog.net

were tough in two cases. All patients had no skin ulceration, no local irritation, and no nipple discharge.

Ultrasound examination: A color Doppler ultrasound diagnostic apparatus was used, and the probe frequency was set at 5-12 MHz. Patients were laid in the supine position. The bilateral breast and axilla were fully exposed, and extensive scanning was performed. Conventional indexes such as lesion size, location, shape, boundaries, internal echo, calcification, posterior echo changes, and internal blood flow signals were recorded, and the data were stored on a hard disk. The blood flow of the breast tumor was divided into grades (0-III), according to the Adler classification: grade 0, no blood flow signal, grade I, 1-2 spotty blood flows, grade II, one main blood flow with a length of over the radius of the lesion or few small vessels, and grade III, rich blood flow, more than four vessels were interconnected to form a network. The retrospective analysis of the ultrasound images obtained from all cases was completed by two senior doctors.

X-ray examination methods. The X-ray machine used was a full-field digital mammography camera. The bilateral breast tails, the internal and external oblique sections, or external-internal oblique section was photographed, and the images were stored into the PACS system. Two senior doctors read the films and drew the final diagnosis.

The double-blind reading of the films was performed by the two senior pathology physicians. All specimens were tested for cancer and sarcoma, and were finally tested by immunohistochemistry, thereby arriving to the conclusion.

Results

All nine patients had carcinosarcoma present in a single breast tumor. The maximum diameter of these tumors were 2.2 cm, 2.8 cm, 5.9 cm, 4.2 cm, 2.8 cm, 3.0 cm, 6.5 cm, 1.3 cm, and 3.5 cm, respectively, and the average size was approximately 3.58 ± 1.69 cm. Before surgery, ultrasound diagnoses included six cases of breast cancer, one case of phyllodes tumor, and two cases of fibroadenoma. Furthermore, among these cases, five patients had tumors with clear boundaries, and four patients had tumors with unclear boundaries. Moreover, among these patients, six patients had irregular tumors and three patients had oval tumors. In addition, among these patients, five patients had tumors with lobulated margins (Figure 1A), three patients had tumors with angular margins, and one patient had tumors with smooth margins. It was also found that two patients had internal calcification and four patients had internal liquefaction necrosis. Among these patients, seven patients had posterior echo enhancement and two patients had attenuated posterior echoes. In addition, six patients had Adler grades II-III of internal blood flow, and ipsilateral axillary lymph node enlargement was detected in one patient by ultrasonography.

X-ray detection revealed that a tumor was located in dense glands in one patient, tumors were located in adipose glands in five patients, and tumors were located in inhomogeneous and dense glands in three patients. In seven patients, the tumors were round or similar to a round in shape, and were irregular in shape in two patients, and the phymas were of high density or were relatively of high density (Figure 1B). Before surgery, one patient was diagnosed with fibroadenoma by X-ray, two patients were diagnosed with suspected malignant tumors, four patients were diagnosed with breast cancer, and two patients were diagnosed with phyllodes tumor. Breast X-ray revealed lobulated changes on the margins of the breasts in six cases, smooth margins in one patients, blurred edges and horn-shaped protrusions in two patients, and internal calcification in six patients (round calcification in three patients, cluster calcification in one patient, and polymorphy calcification in two patients).

Histopathological and immunohistochemical findings revealed the diagnosis of metaplastic carcinoma of the breast. These tumors consisted of two components: one type was epithelium-derived malignant tumors, which included two cases of invasive ductal carcinoma, five cases of squamous cell carcinoma, and two cases of spindle cell carcinoma; another type was mesenchyma-derived malignant tumors, which included four cases of cartilage differentiation, one case of bone-like differentiation, and four cases of chondrosarcoma. All cases were confirmed to have no lymph

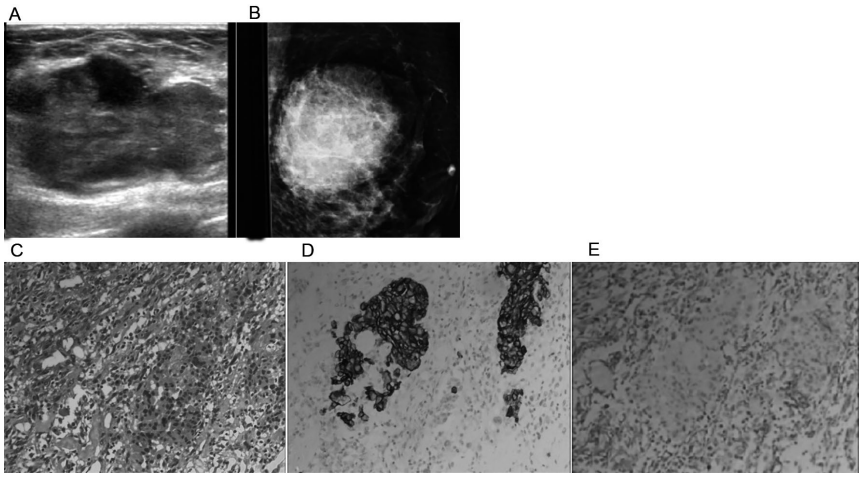

Figure 1. — A) Female, 51-year-old, sonographic imaging showing a solid hepoechic mass in the left quadrant breast, irregular shaped, lobulated edge, liquefied area in the tumor, and misdiagnosed as breast cancer before operation. B) The mass presenting oval high density and inner tiny point microcalcification on mammography. C) HE, ×100, the epithelioid cell-like nests and fusiform sarcomatoid areas are found in the pathological sections. D) IHC, ×100, the epithelioid area AE1/3 was positive, and the sarcomatoid area was negative. E) IHC, ×100, VIM was negative in epithelioid areas and positive in sarcomatoid areas.

node metastasis by postoperative pathology, while axillary lymph node enlargement was detected in one patient and diagnosed as reactive hyperplasia of the lymph node by pathology. Immunohistochemistry revealed negative results of ER, PR, and HER-2 in all nine cases of breast carcinosarcoma.

Discussion

For malignant tumors in the breast, carcinosarcoma accounts for only 0.08-0.2% [13,14]. Its incidence is extremely low, and this disease is most usually found in middle-aged and elderly women. Furthermore, patients often go to visit a doctor due to painless breast phyma, and the course of the disease is relatively long. Clinically, it often manifests as a single phyma with a relatively large size, and has rapid growth. There are often superficial varicose veins and ulceration in the skin of the phyma site [15]. The disease disseminates mainly through blood circulation. Few cases are accompanied with axillary lymph node metastasis. The disease easily relapses after surgery. The prognosis is poor [16]. The number of cases of breast carcinosarcoma is extremely small, and there is at present no specific treatment for this disease. Patients mainly receive comprehensive treatments of surgery, chemotherapy, and radiotherapy.

In the 2012 edition of the World Health Organization (WHO) Breast Tumor Classification, breast carcinosarcoma is a subtype of cancer with mesenchymal differentiation in non-specific metaplastic cancer of the breast. The tumor is a mixture of malignant epithelial and mesenchymal components that can differentiate into cartilage-like and bone-like tissues, or is combined with mesenchymal differentiation. Most studies have suggested that cancer and sarcoma are derived from the same breast cancer stem cell. Cancer occurs first and induces the occurrence of sarcoma [17], and cancer and sarcoma can be mixed at any proportion [18] (Figures 1C-E). Due to its complex structure, preoperative diagnostic accuracy is low, and misdiagnosis often occurs. Clinical diagnosis depends on histopathology and immunohistochemistry. The expression of CK and SMA are positive, and the expression of ER, PR, and HER-2 are often negative [19]. These are consistent with the results of this study.

Compared with the common breast-invasive ductal carcinoma, the volume of breast carcinosarcoma is larger [20]. Furthermore imaging findings may be different due to the different components of breast carcinosarcoma. If cancer is the main component, imaging diagnosis progresses to breast cancer, and if mesenchymal metaplasia is the main component, imaging diagnosis progresses to phyllodes tumors or benign lesions. In this study, among the five patients with carcinosarcoma that mainly consisted of cancer, ultrasound diagnosis results revealed cancer in four patients and fibroadenoma in one patient. Furthermore, X-ray diagnosis results revealed breast cancer in four patients and suspected malignant tumor in one patient. Among these four patients with lesions that mainly consist of sarcoma, ultrasound diagnosis results revealed cancer in two patients, phyllodes tumor in one patient, and fibroadenoma in one patient. Moreover, X-ray diagnosis results revealed phyllodes tumor in two patients, suspected malignant tumor in one patient, and fibroadenoma in one patient.

In this study, the imaging findings of breast carcinosarcoma were consistent with those of previous studies. Ultrasound often revealed a large lobulated mass, and solid low or cystic solid mixed echo in the mass could be present [21]. Liquefaction necrosis was commonly found [22]. Blood flow signals were abundant, and posterior echoes were often enhanced. There were few malignant signs such as burr sign, microcalcification, and posterior echo attenuation [23]. X-ray could reveal two morphologies: carcinoma and sarcoma. The former manifests as an irregular mass with lobulated or burr-like edges and a calcified internal part. The latter manifested a large lobulated mass with smooth margins and calcification was rare. Sometimes, these two morphologies can also coexist [24]. Wang *et al.* [16] concluded that the calcification in breast carcinosarcoma revealed by X-ray detection was mostly an irregular calcification, and diagnostic specificity was low. In this study, no matter what component of breast carcinosarcoma was dominant, imaging performance revealed no significant difference, and often revealed signs of both epithelial and mesenchymal tumors. Based on both the growth pattern of tumors derived from different tissues and the imaging findings of the cases in this study, it remains unknown whether carcinosarcoma, which mainly consists of cancer, exhibits a relatively large number of malignant signs in ultrasound performance due to the growth characteristics of invasive ductal carcinoma, such as irregular morphology and angular boundaries. For cancers that mainly consist of sarcoma, ultrasound revealed relatively considerable clear boundaries, edge lobes, and internal liquefaction necrosis. Since the number of cases in this study is small, the relationship between the histopathology and imaging findings needs to be further evaluated in studies with expanded sample sizes.

Patients with breast carcinosarcoma often develop hematogenous metastasis and the easily affected organs are the lung, liver, and bone, and the metastasis rate of the axillary lymph node is low [25]. In this study, no lymph node metastasis occurred in any of the patients. This is significantly different from that invasive ductal carcinoma of the breast that often induces lymph node metastasis in the draining area. Yang *et al.* [15] collected the data of 94 cases of breast carcinosarcoma, where the metastasis rate of the axillary lymph node was 29.8%. Histopathology revealed that all were cancer metastases in the lymph nodes, and no sarcoma cells were observed.

Breast carcinosarcoma has the characteristics of both

cancer and sarcoma, and ultrasound and X-ray easily cause misdiagnosis. The common imaging performance of breast carcinosarcoma is the large lobulated mass in the unilateral breast. Furthermore, ultrasound often reveals internal liquefaction necrosis and X-ray reveals clear boundaries, and calcification are often observed. On the basis of medical history and clinical manifestations, imaging physicians should consider the possibility of breast carcinosarcoma, and preoperative ultrasound-guided puncture biopsy can improve the accuracy of diagnosis.

Acknowledgement

This study was funded by the Natural Science Foundation of Mutual Funds of the Xinjiang Uygur Autonomous Region, Project number: 2016D01C346.

References

[1] Ferlay J., Soerjomataram I., Dikshit R., Eser S., Mathers C., Rebelo M., et al.: "Cancer incidence and mortality worldwide: sources, methods and major patterns in GLOBOCAN 2012". *Int. J. Cancer*, 2015, *136*, E359.

[2] Kumar S.S., Prateek A., Vishu M.: "Breast cancer diagnosis using digital image segmentation techniques". *Indian J. Science Tech.*, 2016, *9*, 1.

[3] Panesar S., Neethirajan S.: "Microfluidics: Rapid Diagnosis for Breast Cancer". *Nano-Micro Letters*, 2016, *8*, 1.

[4] McCullough L.E., Chen J., Cho Y.H., Khankari N.K., Bradshaw P.T., White A.J., *et al.*: "DNA methylation modifies the association between obesity and survival after breast cancer diagnosis". *Breast Cancer Res. Treat.*, 2016, *156*, 183.

[5] Stein R.G., Wollschläger D., Kreienberg R., Janni W., Wischnewsky M., Diessner J., *et al.*: "The impact of breast cancer biologicalsubtyping on tumor size assessment by ultrasound and mammography - aretrospective multicenter cohort study of 6543 primary breast cancer patients". *BMC Cancer*, 2016, *16*, 459.

[6] McDonald E.S., Clark A.S., Tchou J., Zhang P., Freedman G.M.: "Clinical Diagnosis and Management of Breast Cancer". *J. Nucl. Med.*, 2016, *57*, 9S.

[7] Berg W.A., Zhang Z., Lehrer D., Jong R.A., Pisano E.D., Barr R.G., *et al.*: "Detection of breast cancer with addition of annual screening ultrasound or a single screening MRI to mammography in women with elevated breast cancer risk". *JAMA*, 2012, *307*, 1394.

[8] Nieciecki M., Dobruch-Sobczak K., Wareluk P., Gumińska A., Białek E, Cacko M., Królicki L.: "The role of ultrasound and lymphoscintigraphy in the assessment of axillary lymph nodes in patients with breast cancer". *J. Ultrason.*, 2016, *16*, 5.

[9] Dummin L.J., Cox M., Plant L.: "Prediction of breast tumor size by mammography and sonography–A breast screening experience". *Breast*, 2007, *16*, 38.

[10] Bandos A.I.: "Breast cancer detection rate using ultrasound is shown to be comparable to mammography". *J. Natl. Cancer Inst.*, 2016, *108*, 408.

[11] Evans D.G., Kesavan N., Lim Y., Gadde S., Hurley E., Massat N.J., et al.: "Erratum to: MRI breast screening in high-risk women: cancer detection and survival analysis". *Breast Cancer Res. Treat.*, 2014, *145*, 663.

[12] Al Sayed A.D., El Weshi A.N., Tulbah A.M., Rahal M.M., Ezzat A.A.: "Metaplastic carcinoma of the breast Clinical presentation, treatment results and prognostic factors". *Acta Oncol.*, 2006, *45*, 188.

[13] Esses K.M., Hagmaier R.M., Blanchard S.A., Lazarchick J.J., Riker A.I.: "Carcinosarcoma of the breast:two case reports and review of literature". *Cases J.*, 2009, *2*, 15.

[14] Zhang Y., Cao M.Z.: "Clinical characteristic of breast carcinosarcoma in pathology and biology". *Chinese Archives of General Surgery (electronic version)*, 2009, *3*, 499.

[15] Yang Y.X., Zhang L.P., Guo G.C.: "Analysis of clinicopathological features and prognosis of 94 patients with breast carcinosarcoma". *Tumor*, 2013, *33*, 63.

[16] Wang Y.X., Lu S., Wang T., Liu H.: "Breast Carcinosarcoma:A Clinicopathological Analysis of 23 Cases". *Chinese J. Clin. Oncol.*, 2012, *39*, 656.

[17] Gogas J., Kouskos E., Markopoulos C., Mantas D., Antonopoulou Z., Kontzoglou K., et al.: "Carcinosarcoma of the breast:report of two cases". *Eur. J. Gynaecol. Oncol.*, 2003, *24*, 93.

[18] Beatty J.D., Atwood M., Tickman R., Reiner M.: "Metaplastic breast cancer: clinical significance". *Am. J. Surg.*, 2006, *191*, 657.

[19] Lim K.H., Oh D.Y., Chie E.K., Han W., Im S.A., Kim T.Y., et al.: "Metaplastic breast carcinoma:clinicalpathologic features and prognostic value of triple negativity". *Jpn. J. Clin. Oncol.*, 2010, *40*, 112.

[20] Kitada M., Yasuda S., Takahashi N., Okazaki S., Ishibashi K., Hayashi S.: "Clinicopathological study of epithelial metaplastic breast cancer". *J. Cancer Ther.*, 2016, *7*, 1039.

[21] Yang W.T., Hennessy B., Broglio K., Mills C., Sneige N., Davis W.G., et al.: "Imaging differences in metaplastic and invasive ductal carcinomas of the breast". *AJR Am. J. Roentgenol.*, 2007, *189*, 1288.

[22] Sun K., Chen K.M., Chai W.M., He N.Y., Yan F.H.: "Multimodality imaging of metaplastic breast carcinoma". *J. Pract. Radiol.*, 2013, *29*, 1221.

[23] Chen X.S., Zhang X.J., Lin L.W., Xue E.S., Yu L.Y., He Y.M.: "Application value of color Doppler ultrasound in metaplastic breast carcinoma. *Ultrasonography*, 2016, *25*, 223.

[24] Shi X.X., Liu X.H., Fang Y.Y.: " A case: breast carcinosarcoma". *Radiol. Prtact.*, 2013, *28*, 783.

[25] Yakan S., Sarı E., Erkan N., Yıldırım M., Vardar E., Coskun A., *et al.*: "Breast Carcinosarcomas". *Meme Sagligi Dergisi*, 2014, 10, 161.

Corresponding Author:
ZHI-YING JIA, M.D.
Department of Ultrasound,
the Affiliated Tumor Hospital of Xinjiang Medical University
No. 789 of Suzhou East Street, Xinshi District
Urumqi 830011 (China)
e-mail: jiazy364@sina.com