

Oncology cytology and HPV DNA testing in women with cervical ectopy

S.M.S. Fernandes¹, J.C.L. Ribalta¹, N.M.G. Speck¹, Y. Yamamura²

¹Department of Gynecology, Federal University of São Paulo, São Paulo

²Department of Orthopedics and Traumatology-Gynecological Acupuncture, Federal University of São Paulo, São Paulo (Brazil)

Summary

Objective: To analyse women with ectopy, conventional Pap smear (CPS) and liquid-based cytology (LBC), high-risk HPV (HR-HPV) and its relationship to ectopic size. **Materials and Methods:** The authors selected 51 women with ectopy, without therapy, negative CPS, and no HPV-induced effect. The authors performed colposcopy, LBC, and HPV testing. They performed computerized planimetry to calculate the percentage of the ectopic area (PEA). The data were analyzed statistically. **Results:** The mean age was 25.6 years. LBC confirmed CPS predominating metaplastic and/or glandular epithelia, negative deviation to BV, and reactive/inflammatory conclusion. The authors detected atypical squamous cells of undetermined significance (ASCUS) and low-grade squamous intraepithelial lesions (LSIL) in 17.6% in LBC. HR-HPV was positive in 33% ($p = 0.320$), with a mean age of 22.8 years and with predominance of HPV other types (OT) in 25.5%. The mean PEA in HPV positive patients was 34.57% ($p = 0.664$). **Conclusion:** LBC confirmed the CPS. HPV OT predominated in the age group younger than 25 years. There was no relationship between HR-HPV and ectopic size.

Key words: Ectopy; Conventional Pap smear; Liquid- based cytology; HPV-HR.

Introduction

The uterine cervix is covered by squamous epithelium in the ectocervix and by columnar epithelium in the endocervix. Ectopy is the presence of the columnar epithelium on the ectocervix, exposing the squamocolumnar junction (SCJ) to the vaginal environment. This condition is physiological, originating from embryogenesis, and the location of SCJ may be influenced by sex steroids [1].

Under the influence of hormones and triggered by vaginal acidity, squamous re-epithelialization of the columnar epithelium occurs spontaneously through metaplasia, for months or years, and the resulting area is known as the transformation zone (TZ) [2].

Although often asymptomatic, ectopy can cause mucorrhea, pelvic pain, and post-coital bleeding [1]. The incidence is 20% in gynecological clinics rising to 50% when associated with the presence of TZ [3].

The diagnosis is clinical by anamnesis and specular examination, confirmed by colposcopy, with emphasis on differential diagnosis with cancer. The screening of cervical cancer and its precursor lesions in this country is performed with conventional Pap smear (CPS), beginning at age 25 years, with triennial intervals after two negative annual exams [4].

The cytological results commonly found in women with ectopy are represented, mostly by inflammatory process, associated with vaginal flora deviation by bacterial vaginosis (BV) and cytologic atypia [5, 6]. Nowadays the treat-

ment is still controversial and it is indicated only in cases of exuberant symptomatology [1].

The main risk factors involved in the persistence of ectopy are BV, hormonal contraceptive (HC), and smoking [5, 7, 8]. There is also an association between ectopy and infection by *Chlamydia trachomatis*, human immunodeficiency virus (HIV), high-risk HPV (HR-HPV), and possible relationship with cervical intraepithelial neoplasia [1, 2, 9].

The predisposition to HR-HPV infection deserves special attention because of its relation to the genesis of cervical cancer [10]. Likewise, there is a relationship between higher rates of HR-HPV positivity with greater extension of ectopy [11,12].

The present authors' objective was to evaluate the CPS and liquid-based cytology (LBC) results in healthy women with ectopy, with HR-HPV test and its relationship with ectopic size.

Materials and Methods

From November 2010 to December 2015, the authors selected 51 women in reproductive age, with ectopy, confirmed by colposcopy, virgin treatment, with negative CPS, without signs of the HPV-induced effect. Pregnant, nursing, and immunosuppressed women in general were excluded.

The authors collected cervical samples, in ThinPrep bottles for LBC and HPV DNA PCR detection of HPV 16, 18 and other types (OT) (31, 33, 35, 39, 45, 51, 52, 56, 58, 59, 66, and 68). The cytological reports followed the nomenclature of the Bethesda 2001

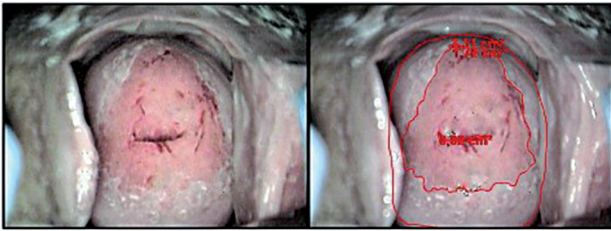


Figure 1. — Computerized planimetry.

System [13]. Next, they performed colposcopy with jpeg-format image captured by the Diagnose Pro 7.5 program. They selected the photos with 3% acetic acid solution, according to the visualization of at least 75% of the ectocervical surface, cervical orifice, cervical curvature, and the best focus obtained for the identification of anatomical structures [14]. The authors checked photos for brightness, contrast, and sharpness using the Nero PHOTO-SNAPVIEWER program. They also perform computerized planimetry [2, 11, 14-20] using the AxioVision LE 4.8.2.0 sp3 Software, with a standardized scale in cm, to delimit the total area of the cervix, external orifice, and ectopy [12]. The results were expressed as percentage of ectopic area (PEA) (Figure 1).

Statistical analysis of CPS and LBC reports on the conclusion, epithelial representation, BV deviation, and HR-HPV positivity were described through mean and frequency in percentage. The authors used the Pearson χ^2 test in the HR-HPV distribution by age group and Student's *t*-test for independent samples in the comparison between the mean ages of HR-HPV positive and negative patients, and the relation between HR-HPV positivity and PEA, with an alpha significance level of 5% ($p = 0.05$). The study was approved by the institution's Ethics and Research Committee, and a free and informed consent form was offered.

Results

The population was Caucasian (70.6%), nulliparous (62.7%), mean age 25.6 years, menarche at 12.2 years, and first sexual experience at 16.9 years. The use of HC was reported by 80.4%, 51% were symptomatic and non-smokers.

LBC reports confirmed CPS's regarding the negative/inflammatory finding in 80.4%, however, the authors detected atypical squamous cells of undetermined significance (ASCUS) and low-grade squamous intraepithelial lesions (LSIL) in 17.6% of reports in LBC. There was adequate representation of the epithelia in both techniques, predominating the metaplastic and/or glandular epithelia. The deviation for BV was negative in 98% of the samples in the CPS and 88.2% in the LBC (Table 1).

HPV-HR was positive in 33% of cases ($p = 0.320$), with HPV OT occurring in 25.5%, followed by HPV16 in 5.9% and HPV18 in 2%. The mean age of HR-HPV patients was 22.8 years ($p = 0.023$), with 35.3% in the age group ≥ 25 years (Table 2). When the authors analyzed by age group, they observed a uniform distribution in the sample between positive and negative HR-HPV ($p = 0.166$). They found no relation between HR-HPV positivity and ectopic

Table 1. — Results of the CPS, LBC, and HR-HPV research.

		Method			
		CPS		LBC	
		n	(%)	n	(%)
Conclusion	Normal	2	3.9	0	0
	N/I	49	96.1	42	82.4
	ASCUS	0	0	8	15.6
	LSIL	0	0	1	2
	Total	51	100	51	100
Epithelia	Squamous	9	17.6	10	19.6
	M and/or C	42	82.1	41	80.4
	Total	51	100	51	100
Deviation of flora	Positive	1	2	6	10.7
	Negative	50	98	45	88.2
	Total	51	100	51	100
HPV	16	0	0	1	2
	OT	0	0	13	25.5
	16/OT	0	0	2	3.9
	18/OT	0	0	1	2
	Positive	0	0	17	33.3
	Negative	0	0	34	66.7
	Total	0	0	51	100

Legend: CPS: conventional Pap smear; LBC: liquid-based cytology; N/I: Negative/inflammatory; M and/or C: metaplastic and/or columnar; OT: other types;

Table 2. — Distribution of HR-HPV and age.

		HPV+		HPV-		Total		<i>p</i>
		n	Average	n	Average	n	Average	
Age		17	22.8	34	27.0	51	25.6	0.023 ^a
Age group	Up to 24	11	64.7	15	44.1	26	51	
	≥ 25	06	35.3	19	55.9	25	49	
	Total	17	100	34	100	51	100	

Student *t*-test for independent samples (a); Pearson test χ^2 (b): $p = 0.05$.

Legend: n = number of patients.

Table 3. — HR-HPV and average of the percentages of ectopic area.

HPV-HR	Ae		<i>p</i>
	n	Average (%)	
Positive	17	34.57	0.664
Negative	34	37.54	
Total	51	36.55	

Student *t*-test for independent samples: $p = 0.05$. Legend: n = number of patient; Ae: ectopy area.

size ($p = 0.664$), since the mean PEA in HR-HPV positive patients was 34.57%, compared to 37.54% of HR-HPV negative patients (Table 3).

Discussion

The main issue related to ectopy refers to the differential diagnosis with cancer. Oncotic cytology and colposcopy are starting points for investigation of precursor lesions, considering the possibility of deviations in the HPV-in-

duced metaplastic process [2, 12].

According to the ATHENA study, the primary screening for cervical cancer with DNA HPV screening in women ≥ 25 years is as effective as a hybrid screening strategy that uses cytology in patients aged 25-29 years and co-testing if aged ≥ 30 years [21]. The present authors chose cytology and co-testing, despite different age groups, in order to confront CPS and LBC, besides HPV research.

Ectopy, although considered a physiological phenomenon, has been the object of research over time. Nowadays, it still raises questions about its actual nosological role. The cytological and infectious correlations assist in the therapeutic decision although there is still no consensus [1].

In the present study, the authors confirmed the incidence of ectopy in young women, with a mean age of 25.6 years according to previous studies in this country [5, 6]. The persistence of ectopy is observed in sexually active women with a higher risk of exposure to infectious agents, which could result from late diagnosis or a tendency towards conservative behavior towards treatment.

Of the risk factors involved with persistence, the present authors observed only the use of HC, without smoking interference and deviation for BV. The results of the LBC confirmed those of the CPS, which leads us to consider both feasible and reliable methods in patients with ectopy, obeying protocols of population screening.

The reports in the LBC were conclusive for negative/inflammatory in 80.4% of the cases, such as CPS and compatible with those already described in previous studies [5, 6]. The authors detected cytologic atypias in LBC in 17.6%, ASCUS in 15.6% and LSIL in 2% of the cases, confirming a study in this country that identified intraepithelial atypias in 12.7% [6]. The metaplastic and or columnar epithelia had the same frequency, 82.4% in CPS vs. 80.4% in LBC, reinforcing that there is no correlation between the presence or size of an ectopy with the adequacy of the cytological sample [22]. The negative deviation to BV predominated in both techniques.

The HR-HPV study was positive in 33.3%. The mean age of the positive women was lower than 25 years ($p = 0.023$), confirming the fact that the younger population, due to the greater exposure, is at higher risk of HPV infection; however, they present a greater tendency to spontaneous resolution [12]. Only 35.6% HPV positive patients were aged ≥ 25 years. HPV OT was the most frequent, alone or in combination. The present data disagree with previous studies that associated ectopia had a higher risk of infection by HPV 16 and 18 [23,24].

The acquisition of HR-HPV has been attributed to a greater extension of ectopic area [11], however the present authors did not find a relationship between HR-HPV positivity and ectopic size, according to a previous study with adolescents [12].

Although CPS and LBC have equivalent results in sensitivity and specificity [25], the association with the HPV

DNA test could be considered in patients with persistent ectopy, especially in those older than 25 years, in the decision for an interventional approach.

Conclusion

In healthy women with ectopy, LBC confirmed CPS regarding the representation of metaplastic and/or glandular epithelia, negative BV, and to the reactive/inflammatory report, and cytological atypia, when present, was represented by low-grade lesions. HPV OT was the most prevalent among women younger than 25 years. There was no relationship between HR-HPV positivity and ectopic size.

References

- [1] Machado Junior L.C., Dalmaso A.S.W., Carvalho H.B.: "Evidence for benefits from treating cervical ectopy: literature review". *São Paulo Med. J.*, 2008, 126, 132.
- [2] Hwang L.Y., Ma Y., Benningfield S.M., Clayton L., Hanson E.N., Jay J., et al.: "Factors that influence the rate of epithelial maturation in the cervix of healthy young women". *J. Adolesc. Health*, 2009, 44, 103.
- [3] Miyatake T., Ueda Y., Yoshino K., Shroyer K.R., Kanao H., Sun H., et al.: "Clonality analysis and human papillomavirus infection in squamous metaplasia and atypical immature metaplasia of uterine cervix: is atypical immature metaplasia a precursor to cervical intraepithelial neoplasia 3?". *Int. J. Gynecol. Pathol.*, 2007, 26, 180.
- [4] www.ans.gov.br/...oncologia/gt_oncorede_reuniao7_diretrizes_cancer_colo.pdf: "Diretrizes brasileiras para o rastreamento do câncer do colo uterino. / Instituto Nacional de Câncer José Alencar Gomes da Silva. Coordenação de Prevenção e Vigilância. Divisão de Detecção Precoce e Apoio à Organização de Rede". – 2. ed. rev. atual. – Rio de Janeiro: INCA, 2016. Access 20/04/2017.
- [5] Coser J., Fontoura F., Belmonte C., Vargas V.R.A.: "Relation between risk factors and cervical cancer precursor lesion in women with and without cervical ectopy". *RBAC.*, 2011, 44, 50.
- [6] Eleutério Jr J., Giraldo P.C., Gonçalves A.K.S., Amaral R.I.G., Linhares I.M.: "Uterine Cervical Ectopy During Reproductive Age: Cytological and Microbiological Findings". *Diagn. Cytopathol.*, 2014, 42, 401.
- [7] Jacobson D.L., Peralta L., Graham N.M.H., Zenilman J.: "Histologic development of cervical ectopy. Relationship to reproductive hormones". *Sex. Trans. Dis.*, 2000, 27, 252.
- [8] Morrison C.S., Bright P., † Wong E.L., Kwok C., Yacobson I., Gaydos C.A., et al.: "Hormonal contraceptive use, cervical ectopy, and the acquisition of cervical infections". *Sex. Trans. Dis.*, 2004, 31, 561.
- [9] Moscicki A.B., Ma Y., Holland C., Vermund S.H.: "Cervical Ectopy in Adolescent Girls with and without Human Immunodeficiency Virus Infection". *J. Inf. Dis.*, 2001, 183, 865.
- [10] Appleby P., Beral V., Berrington de Gonzalez A., Colin D., Franceschi S., Goodill A., et al.: "Carcinoma of the cervix and tobacco smoking: Collaborative reanalysis of individual data on 13,541 women with carcinoma of the cervix and 23,017 women without carcinoma of the cervix from 23 epidemiological studies. International Collaboration of Epidemiological Studies of Cervical Cancer". *Int. J. Cancer.*, 2006, 11, 1481.
- [11] Castle P.E., Jeronimo J., Schiffman M., Herrero R., Rodriguez A.C., Bratti M.C., et al.: "Age-related changes of the cervix influence human papillomavirus type distribution". *Cancer Res.*, 2006, 66, 1218.
- [12] Hwang L.Y., Lieberman J.A., Ma Y., Farhat S., Moscicki A-B., et al.: "Cervical Ectopy and the Acquisition of Human Papillomavirus

- in Adolescents and Young Women". *Obst. Gynecol.*, 2012, 119, 1164.
- [13] Apgar B.S., Zoschnick L., Wright Jr T.C.: "The 2001 Bethesda System Terminology". *Am. Fam. Phy.*, 2003, 69, 1992.
- [14] Kleppa E., Holmen S.D., Lillebø K., Kjetland E.F., Gundersen S.G., Taylor M., *et al.*: "Cervical ectopy: associations with sexually transmitted infections and HIV". *Sex. Transm. Infect.*, 2015, 91, 124.
- [15] Jacobson D.L., Peralta L., Farmer M., Graham N.M., Wright T.C., Zenilman J.: "Cervical ectopy and the transformation zone measured by computerized planimetry in adolescents". *Int. J. Gynecol. Obstet.*, 1999, 66, 7.
- [16] Jacobson D.L., Peralta L., Farmer M., Graham N.M., Wright T.C., Zenilman J.: "Relationship of hormonal contraception and cervical ectopy as measured by computerized planimetry to chlamydial infection in adolescents". *Sex. Transm. Dis.*, 2000, 27, 313.
- [17] Moscicki A.B., Burt V.G., Kanowitz S., Darragh T., Shiboski S.: "The significance of squamous metaplasia in the development of low grade squamous intraepithelial lesions in young women". *Cancer*, 1999, 85, 1139.
- [18] Morison C.S., Bright P., Blumenthal P.D., Yacobson I., Kwok C., Zdenek S., Pan Z.: "Computerized planimetry versus clinical assessment for the measurement of cervical ectopy". *Am. J. Obstet. Gynecol.*, 2001, 184, 1170.
- [19] Bright P.L., Turner A.N., Morrison C.S., Wong E.L., Kwok C., Yacobson I., *et al.*: "Hormonal contraception and area of cervical ectopy: a longitudinal assessment". *Contraception*, 2011, 84, 512.
- [20] Walter J., Fraga L., Orin M.J., Decker W.D., Gipps T., Stek A., Al-drovandi G.M.: "Immunomodulatory factors in cervicovaginal secretions from pregnant and non-pregnant women: A cross-sectional study". *BMC Infectious Diseases*, 2011, 11, 263.
- [21] Wright C.T., Stoler M.H., Behrens C.M., Sharma A., Zhang G., Wright T.L.: "Primary cervical cancer screening with human papillomavirus: end of study results from the ATHENA study using HPV as the first-line screening test". *Gyn. Oncol.*, 2015, 136, 189.
- [22] Buntinx F., Essed G.G., Van der Putten H.W., Buchholz R.F., Arends J.W., Knottnerus J.A.: "Composition of cervical smears in patients with and without a cervical ectropion". *J. Clin. Pathol.*, 1995, 4, 408.
- [23] Rocha-Zavaleta L., Yescas G., Cruz R.M., Cruz-Talonia F.: "Human papillomavirus infection and cervical ectopy". *Int. J. Gynecol. Obstet.*, 2004, 85, 259.
- [24] Monroy O.L., Aguilar C., Lizano M., Cruz-Talonia F., Cruz R.M., Rocha-Zavaleta L.: "Prevalence of human papillomavirus genotypes, and mucosal IgA anti-viral responses in women with cervical ectopy". *J. Clin. Virol.*, 2010, 47, 43.
- [25] Singh V.B., Gupta N., Nijhawan R., Srinivasan R., Suri V., Rajwanshi A.: "Liquid- based cytology versus conventional cytology for evaluation of cervical Pap smears: Experience from the first 1000 split samples". *J. Pathol. Microbiol.*, 2015, 58, 17.

Corresponding Author:

S.M. SILVA FERNANDES, M.D.

Martiniano de Carvalho Street, 836 - fit 73 block 4.

Bela Vista. São Paulo

01321-000 (Brazil)

e-mail: silvanamsfernandes@uol.com.br