

A case of fertility sparing surgery of low-Grade endometrial stromal sarcoma in young female

Jiyeon Seong^{1,2}, Yong Jung Song^{1,2}, Yong Jin Na^{1,2}, Hwi Gon Kim^{1,2}

¹Department of Obstetrics and Gynecology, Pusan National University Yangsan Hospital, Yangsan

²Research Institute for Convergence of Biomedical Science and Technology, Pusan National University Yangsan Hospital (South Korea)

Summary

Low-grade endometrial stromal sarcoma (LGESS) is a rare malignancy. Total hysterectomy and bilateral salpingo-oophorectomy (BSO) were included in the main treatment. The present authors evaluate the feasibility of fertility-sparing management in a patient with low-grade ESS who desired childbearing. The patient aged 24 years presented without symptom. She received laparoscopic myomectomy with endobag morcellation of local resection of the mass with uterine reconstruction. The postoperative pathohistologic analysis showed estrogen receptor (±), progesterone receptor (+), then the adjuvant hormonal therapy was given with megestrol acetate 320 mg/day for six months. She received close follow-up which included clinical examination, tumor markers, abdominal and pelvic ultrasound, and yearly pelvic MRI. Thirty-five months after surgery, no evidence of recurrence was observed throughout this period. The authors propose that consider that fertility-sparing treatment is suitable in selected in young LGESS patients, especially for those whose lesion was with a clear borderline. Adjuvant endocrine therapy is recommended for about six months after operation.

Key words: Low-grade endometrial stromal sarcoma (LGESS); Laparoscopic myomectomy; Endobag morcellation; Fertility-sparing treatment.

Introduction

Endometrial stromal sarcoma (ESS) is a rare uterine mesenchymal neoplasm representing approximately 0.2% of all uterine cancers [1]. Histopathologically, ESS is subdivided into distinct low- and high-grade entities by WHO Classification of Tumors of Female Reproductive Organs. Low-grade endometrial stromal sarcoma (LGESS) shows minimal to no cytological atypia and low mitotic activity (usually <5 mitosis per 10 high-power fields (HPFs). High-grade endometrial stromal sarcoma (HGEES) shows high mitotic activity (typically >10 per 10 HPFs). LGESS is generally a slow-growing malignancy with an indolent clinical course, but with a tendency for late recurrence, while HGEES is more aggressive, frequently metastasizes, and has an extremely poor outcome. Because of its rarity and heterogeneous morphological appearance, LGESS is often misdiagnosed as a different uterine neoplasm, for example, benign leiomyoma [2, 3]

Because of the malignant nature of disease, the current mainstay of treatment for LGESS is hysterectomy with bilateral salpingo-oophorectomy (BSO). However, A standard treatment is not established, so women may undergo lymphadenectomy, hormone treatment, chemotherapy or radiation as salvage therapy and there is no consensus on the role of ovarian preservation [4].

Unfortunately, some of patients were young and desired

childbearing eventually. Fertility-sparing management of ESS has been demonstrated, while reports of pregnancy after such management is rare. Herein, we report the case of fertility sparing surgery in LGESS patient who desired childbearing in the future.

Case Report

A 24-year-old woman (gravida 0, para 0), with no prior medical and surgical history was referred to Pusan National Univer-

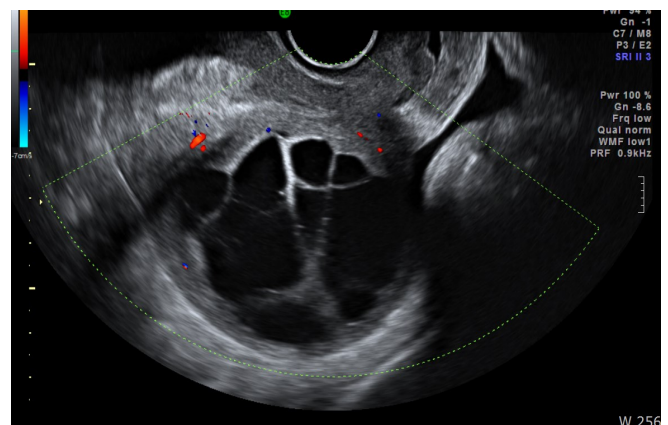


Figure 1. — At posterior corpus of uterus, a 6.3×5.6-sized homogenous hypoechoic lesion is shown with multiseptated cystic degeneration on transvaginal ultrasonography.

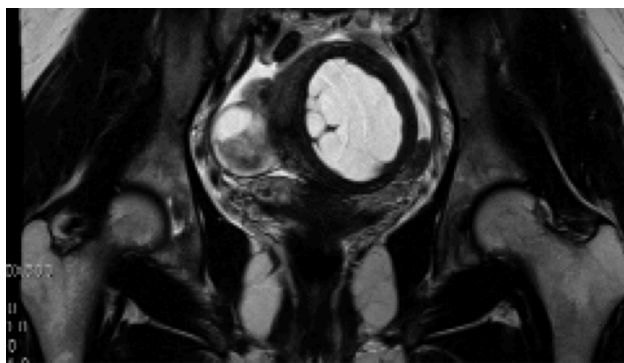


Figure 2. — Subserosal myoma (6.3 cm) with cystic degeneration is observed on MRI.

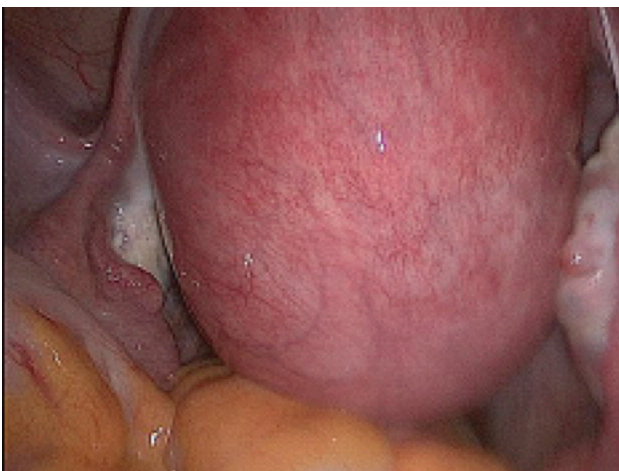


Figure 3. — Laparoscopic findings. The posterior wall of uterus is seen as irregular and it appears as an intramural myoma.

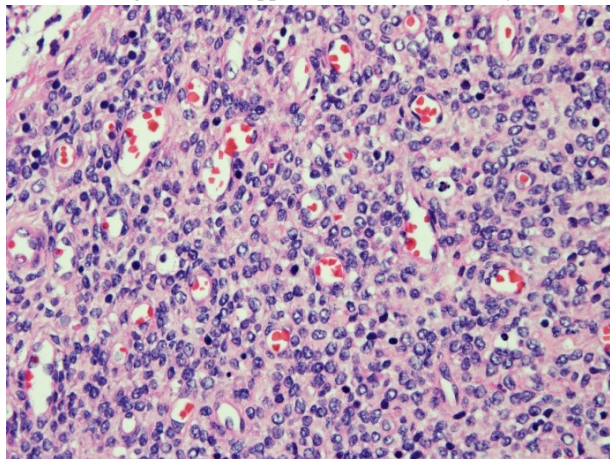


Figure 4. — Histopathology of LGESS (×400/HPF). It is mixed endometrial stromal and smooth muscle tumor with multiple foci of myometrial invasion.

sity Yangsan Hospital due to the incidental pelvic mass. She had a regular menstrual cycle during the last four months with dysmenorrhea, gradually increasing in intensity. No other symptoms including vaginal bleeding, abdominal pain, amenorrhea, and

leukorrhea were seen. On physical examination, the uterus was enlarged to 14 weeks in size. Blood samples were collected for laboratory tests. White blood cell count was $5,890/\text{mm}^3$ with 60% bands. Pancreas and liver function tests were all normal. The levels of serum CA 19-9 was 7.83 (0-35) U/mL and CA 125 was 41.9(0-35) U/mL.

Transvaginal ultrasonography revealed a large uterus with a well-defined multicystic mass of 6.3×5.6 cm along the posterior wall (Figure 1). Subserosal myoma (6.3 cm) with cystic degeneration was observed on MRI (Figure 2). As a result of the test, it was estimated to be a cystic degeneration of leiomyoma, therefore the authors decided to perform laparoscopic myomectomy. On laparoscopy, the posterior wall of uterus was visualized as irregular and it appeared like an intramural myoma (Figure 3). In an effort to avoid the spread of cells to other areas inside the abdomen can be prevented, laparoscopic myomectomy with endobag morcellation was performed. The myometrium was repaired with two-layered barbed sutures. Histologic findings confirmed a mixed endometrial stromal and smooth muscle tumor with multiple foci of myometrial invasion (Figure 4). It was confined to uterine corpus and mitotic activity was 0/10 HPF, which indicated a LGESS. Lymphovascular invasion was not identified.

The present authors recommend total laparoscopic hysterectomy with BSO for conventional treatment. However, she insisted on maintaining her fertility on account of her young age and virginity. The postoperative pathohistologic analysis showed estrogen receptor (\pm), Progesterone receptor (+), then the adjuvant hormonal therapy was given to them with megestrol acetate 320 mg/day for six months. She received close follow up which included clinical examination, tumor markers, abdominal and pelvic ultrasound and yearly pelvic MRI. Thirty-five months after surgery, no evidence of recurrence was observed throughout this period.

Discussion

LGESS is a hormone-sensitive low-grade malignancy that generally follows an gradual course with a tendency for late recurrence, while HGEES is characterized by an aggressive clinical course [5]. LGESS has an infiltrating margin and commonly exhibits extensive worm-like lymphatic and venous vessel invasion histologically. The overall disease-specific five- and ten-year survival rates are 80-90% and 70%, respectively. However, the risk of recurrence is believed to be more than 50%, although such tumors usually grow slowly and the recurrence occurs late [6]. The conventional treatment for LGESS includes total hysterectomy and BSO [7, 8]. Because most of the cases of LGESS were misdiagnosed as leiomyoma, the patients would be given the surgery as myomectomy. Especially in young women, leiomyoma is suspected first. In this case, there was no specific findings other than dysmenorrhea and MRI revealed cystic degeneration of myoma.

Histologically ESS may be confused with leiomyoma, uterine leiomyosarcoma (LMS), or other sarcomas. In addition, the immunohistochemical profile of ESS may have similarities with leiomyoma and LMS, with expression of muscle-specific actin (MSA), SMA and desmin. Diffuse CD10 immunoreactivity has proven to be a useful positive predictive marker for ESS. Most cellular leiomyomas are completely negative for CD10 [9].

Some cases reported that the LGEES patients treated with fertility-preserving procedures and revealed completely opposite outcomes. Koskas *et al.* reported a 34-year-old woman treated conservatively after hysteroscopic resection of the LGEES. However, she had severe peritoneal recurrence after several years [10]. Jin *et al.* reported five cases underwent local resection of the LGEES [11]. The patient was given high-dose daily megestrol acetate therapy. All the patients survived. Three of them underwent an uncomplicated pregnancy. Four of them is alive without disease recurrence. The other one found disease recurred during the megestrol acetate treatment and received hysterectomy [12]. In this case, the adjuvant hormonal therapy was given to her with megestrol acetate 320 mg/day for six months. She remained disease-free for 35 months.

References

- [1] Fekete P.S., Vellios F.: "The clinical and histologic spectrum of endometrial stromal neoplasms: a report of 41 cases". *Int. J. Gynecol. Pathol.*, 1984, 3, 198.
- [2] Clement P.B., Young R.H.: "Diffuse leiomyomatosis of the uterus: a report of four cases". *Int. J. Gynecol. Pathol.*, 1987, 6, 322.
- [3] Whitlatch S.P., Meyer R.L.: "Recurrent endometrial stromal sarcoma resembling intravenous leiomyomatosis". *Gynecol. Oncol.*, 1987, 28, 121.
- [4] Ma S.K., Zhang H.T., Wu L.Y., Liu L.Y., Li B.: "Treatment and prognosis of low-grade malignant endometrial stromal sarcoma". *Zhonghua Zhong Liu Za Zhi*, 2007, 29, 74.
- [5] Sciallis A.P., Bedroske P.P., Schoolmeester J.K., Sukov W.R., Keeney G.L., Hodge J.C., *et al.*: "High-grade endometrial stromal sarcomas: a clinicopathologic study of a group of tumors with heterogenous morphologic and genetic features". *Am. J. Surg. Pathol.*, 2014, 38, 1161.
- [6] Styron S.L., Burke T.W., Linville W.K.: "Low-grade endometrial stromal sarcoma recurring over three decades". *Gynecol. Oncol.*, 1989, 35, 275.
- [7] Delaney A.A., Gubbels A.L., Remmenga S., Tomich P., Molpus K.: "Successful pregnancy after fertility-sparing local resection and uterine reconstruction for low-grade endometrial stromal sarcoma". *Obstet. Gynecol.*, 2012, 120, 486.
- [8] Bai H., Yang J., Cao D., Huang H., Xiang Y., Wu M., *et al.*: "Ovary and uterus-sparing procedures for low-grade endometrial stromal sarcoma: a retrospective study of 153 cases". *Gynecol. Oncol.*, 2014, 132, 654.
- [9] Park J.Y., Kim K.R., Nam J.H.: "Immunohistochemical analysis for therapeutic targets and prognostic markers in low-grade endometrial stromal sarcoma". *Int. J. Gynecol. Cancer*, 2013, 23, 81.
- [10] Koskas M., Morice P., Yazbeck C., Duvillard P., Walker F., Madeleine P.: "Conservative management of low-grade endometrial stromal sarcoma followed by pregnancy and severe recurrence". *Anticancer Res.*, 2009, 29, 4147.
- [11] Jin Y., Li Y., Deng C.Y., Tian Q.J., Chen H., Pan L.Y.: "Fertility-sparing treatment of low-grade endometrial stromal sarcoma". *Int. J. Clin. Exp. Med.*, 2015, 8, 5818.
- [12] Nakamura K., Nakayama K., Ishikawa M., Ishikawa N., Katagiri H., Katagiri A., *et al.*: "Letrozole as second-line hormonal treatment for recurrent low-grade endometrial stromal sarcoma: A case report and review of the literature". *Oncol. Lett.*, 2016, 12, 3856.

Corresponding Author:

HWI GON KIM, M.D., PH.D.

Department of Obstetrics and Gynecology

Pusan National University Yangsan Hospital

20 Geumo-ro, Mulgeum-eup

Yangsan, 50612 (South Korea)

e-mail: yangandshin@gmail.com