

# Diagnostic value of different colposcopy evaluation methods for high-grade squamous intraepithelial lesions and cervical cancer

Fang Liu<sup>1,\*</sup>, Yufang Zhang<sup>1</sup>, Xinyi Xia<sup>1</sup>, Jin Han<sup>1</sup>, Danhong Hu<sup>1</sup>

<sup>1</sup>Department of Gynecology, The Second Affiliated Hospital of Jiaxing University, 314000 Jiaxing, Zhejiang Province, China

\*Correspondence: [lilyliufang@163.com](mailto:lilyliufang@163.com) (Fang Liu)

DOI: [10.31083/j.ejgo.2021.03.2347](https://doi.org/10.31083/j.ejgo.2021.03.2347)

This is an open access article under the CC BY 4.0 license (<https://creativecommons.org/licenses/by/4.0/>).

Submitted: 12 December 2020 Revised: 7 February 2021 Accepted: 3 February 2021 Published: 15 June 2021

**Objective:** This study aimed to compare the diagnostic value of R-way, the 2011 International Federation for Cervical Pathology and Colposcopy (IFCPC), and Reid colposcopy evaluation system for high-grade squamous intraepithelial lesions and cervical cancer (HSIL+). **Methods:** A total of 987 cases were referred for vaginal microscopic examination, using R-way system, IFCPC and Reid examination, and diagnostic capabilities of the methods for detecting HSIL+ were compared. **Results:** Using cervical biopsy or conization as the gold standard, in total 170 women (17.2%) had histologically confirmed HSIL+ including 36 women (3.6%) with invasive cervical cancer. The sensitivity for HSIL+ using the three different colposcopy evaluation methods were 74.7% (127/170), 78.2% (133/170) and 62.9% (107/170) for IFCPC, R-way and Reid. Consistency with histopathology was 69.00%, 75.28% and 55.32%, Kappa values were 0.517, 0.599 and 0.310, respectively. Based on HSIL, sensitivity, specificity, PPV and NPV of IFCPC and R-way pair for HSIL+ were better than those of Reid. McNemar test results revealed significant differences between R-way and IFCPC and between Reid and IFCPC for HSIL+ ( $\chi^2 = 19.558$ ,  $\chi^2 = 17.876$ ,  $P < 0.001$ ); however, the consistency rate was better for R-way and IFCPC than for Reid and IFCPC (Kappa = 0.826 vs 0.127, agreement rate: 94.6% vs 70.62%). **Conclusion:** All three evaluation methods can be used for colposcopy diagnosis of HSIL+, and the diagnostic value of IFCPC and R-way is better than Reid. There is good agreement between R-way colposcopy evaluation and histopathology. Considering the characteristics of easy operation, the R-way evaluation system is worthy of popularization and application in primary hospitals.

## Keywords

Colposcopy; Cervical screening; High-grade squamous intraepithelial lesions (HSIL); IFCPC; Reid

## 1. Introduction

Cervical cancer is the fourth most common cancer in women. In 2018, an estimated 570,000 women were diagnosed with cervical cancer worldwide and about 311,000 women died from the disease [1]. It has a long precancerous period. During this period, early screening and diagnosis can be carried out by means of various screening methods. The implementation of screening programmes in developed countries has reduced the mortality rate of cervical cancer

by 70%, but the mortality rate of cervical cancer in China is still very high. Current estimates indicate that every year 106,430 women are diagnosed with cervical cancer in China and 47,739 die from the disease [2].

Because a high-grade squamous intraepithelial lesion (HSIL) can develop into invasive cervical cancer, HSIL detection plays a vital role in preventing cervical cancer [1]. Colposcopy is subjective and has limited sensitivity for high grade lesions (HSIL+). The National Health Service Cervical Screening Programme (NHSCSP) Guidelines for Colposcopy and Programme Management, which guides British practice, ask for evidence of a colposcopic accuracy of 65% [3]. Zuchna *et al.* [4] reported 66.2% sensitivity of HSIL+ when up to three guided cervical biopsies were taken regarded as a diagnostic test with the cone specimen as reference standard. Using digitized cervical images from 919 women referred for equivocal or minor cytologic abnormalities into the ASCUS-LSIL Triage Study, Massad *et al.* [5] reported 39% sensitivity for HSIL+. The precise positioning of HSIL+ under colposcopy is not only a guarantee of a correct pathological diagnosis but also a key technical problem encountered in cervical cancer screening. Accurate determination of the locations of HSIL+ lesions can provide a technical guarantee of reducing the incidence and mortality of cervical cancer.

Colposcopy has been widely used worldwide since the 1960s, and during this time period, the colposcopy-based evaluation system has been continuously developed and changed. Examples of modifications include the acetic acid test method, Reid classification method, Swede method, and multiple-versions of International Federation for Cervical Pathology and Colposcopy (IFCPC) terminology. Although there are a variety of evaluation methods for identifying high-grade squamous intraepithelial neoplasia and cervical invasive carcinoma (HSIL+) under colposcopy, each evaluation method has its own characteristics, but there are reports on these evaluation methods. Studies that perform comprehensive and objective comparisons of the advantages and disadvantages of the various colposcopy evaluation methods would be very useful in helping for colposcopy physicians to select an appropriate evaluation method.

The most widely used scoring systems include the 2011 edition of the IFCPC terminology and Reid scoring systems. Compared with previous versions, the 2011 version of IFCPC provides an overall evaluation of colposcopy, refines and details some newly introduced markers, and introduces for the first time the recommended type of excision [6], which represents the latest global understanding of precancerous lesions of the lower genital tract in women. Reid sets the threshold for different grades of cervical lesions, simplifying the assessment and making it easy to learn. Reid has demonstrated its effectiveness in diagnosing high-grade lesions in terms of sensitivity and specificity [7]. R-way (R: red, w: white, a: abnormal blood vessels, y: yellow) established by Zhao *et al.* [8], is an evaluation system based on the standard colposcopy procedure of histopathology. By observing the staining of cervical epithelium in response to different solutions, colposcopy physicians can accurately identify high-grade lesions or suspicious cancers. According to what evaluation method is more advantageous, this study aimed to compare the diagnostic value of three evaluation methods in the colposcopy detection of HSIL+.

## 2. Materials and methods

### 2.1 Study design and participants

From January 2015 to August 2019, patients who underwent colposcopy and cervical biopsy or cervical conization in the colposcopy clinic of the Second Affiliated Hospital of Jiaxing Medical College were analyzed retrospectively. Indications for colposcopy included the following: positivity for cervical fluid-based cytology (TCT), positivity for high-risk human papillomavirus (hr-HPV), negativity for both TCT and hr-HPV, and obvious clinical symptoms: such as contact bleeding, irregular neoplasm on the cervical surface, cervical stenosis or barrel cervix. The exclusion criteria were as follows: pregnancy, previous cervical lesions or surgery, hysterectomy or incomplete data. All patients signed informed surgical consent forms before undergoing colposcopy and were informed of the purpose of the study. The study was approved by the hospital ethics committee (JXEY-2020JX009).

Colposcopy specialists have obtained the certification of colposcopy qualification and received training in these three practical techniques (IFCPC, Reid and R-way). Colposcopy was performed by 5 colposcopy specialists using R-way evaluation method, and targeted cervical biopsy was performed on abnormal areas under colposcopy. For inconclusive diagnosis, it is reviewed by another qualified senior colposcopy expert to determine the final colposcopy diagnosis.

Reid and 2011 IFCPC evaluation methods were applied for colposcopy image description and diagnosis. Each patient's colposcopy digital photos were reviewed by trained colposcopy experts who were unaware of the patient's previous colposcopy diagnosis. Researchers and pathologists were aware of the results of cytology or HPV testing. As shown in Fig. 1.

### 2.2 Colposcopy

For colposcopy, photoelectric integrated digital electronic colposcopy (Shenzhen Libang Precision Instrument Co., Ltd., Shenzhen, China) was performed by colposcopy specialists using routine 5% acetic acid tests and 5% Lugol liquid iodine staining procedure. The patient was placed in the bladder lithotomy position to expose the cervix and vaginal fornix; 0.9% sodium chloride solution was used to remove mucus secretions from the cervical surface; 5% cotton wool was used to wet the cervical surface for 50 seconds; and images were captured at 60 seconds, 90 seconds, and 120 seconds and observed within 2 minutes to assess changes after application of acetic acid and Lugol's solution.

### 2.3 R-way colposcopic evaluation system

The R-way system evaluation method [9] is as follows: (1) The transformation zone type is evaluated. (2) The current image is captured with and without the green filter to evaluate the "red" (R), namely, the area on the surface of the cervix with the appearance of blood vessels, including physiological and abnormal new blood vessels. (3) Cotton balls containing 5% acetic acid are used to wet the cervix for 50 seconds. Images are then, captured at 60 seconds, 90 seconds, 120 seconds, and the appearance of aceto-white epithelium is observed within 2 minutes. If the whiteness persists or thickens, this feature is defined as "white" (W). (4) Abnormal blood vessels are checked according to a rough mosaic, namely, whether large blood vessels and atypical blood vessels appear in the aceto-white area; this is referred to as "A". (5) Lugol's iodine solution is applied to the cervix to check iodine uptake; yellow (Y) means no iodine uptake.

The R-way evaluation system aims to diagnose HSIL+ based on the principle of collecting colposcopy examination images according to the above characteristics for correlative comparison, based on the pathological "comparison database" intelligence analysis. The four diagnostic criteria for HSIL+ evaluation with the R-way system, as shown in Fig. 2a–d are as follows: red thick white, red white A, red white yellow, and bleeding.

### 2.4 2011 IFCPC

The 2011 IFCPC classification of colposcopy diagnosis is as follows: (1) In the general assessment of colposcopy images: categories include sufficient or inadequate, squamous junctions (fully visible, partially visible or invisible) and transformation zone type 1, 2 or 3. (2) Descriptions of colposcopy images include primitive squamous epithelium, columnar epithelium, metaplastic squamous epithelium, decidualization during pregnancy, and the location and size of the lesion. (3) The findings of colposcopy image grading include a thin aceto-white epithelium; small mosaic and small punctate vessels, suggesting low-grade lesions; a thick aceto-white epithelium, coarse mosaic and thick punctate vessels, with clear boundaries, suggesting high-grade lesions; lymphocytes, erosion, and negative iodine staining as non-specific changes; atypical blood vessels and other signs (ex-

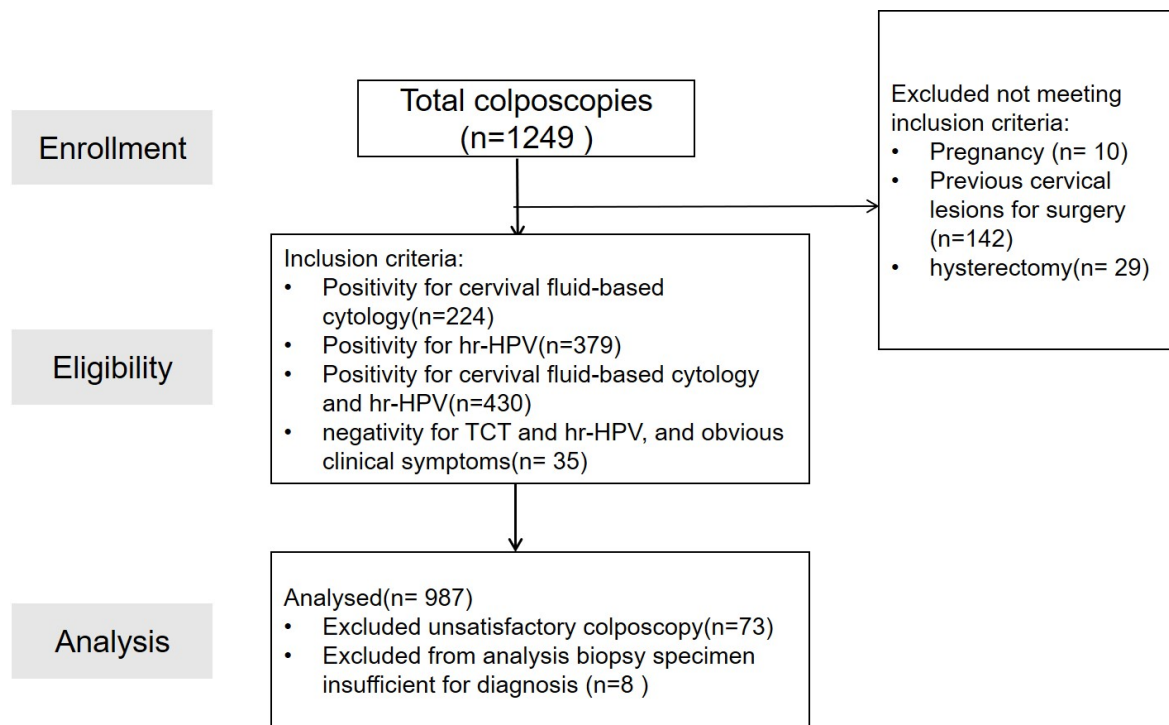


Fig. 1. Flow-chart: the patient's flow through the study.

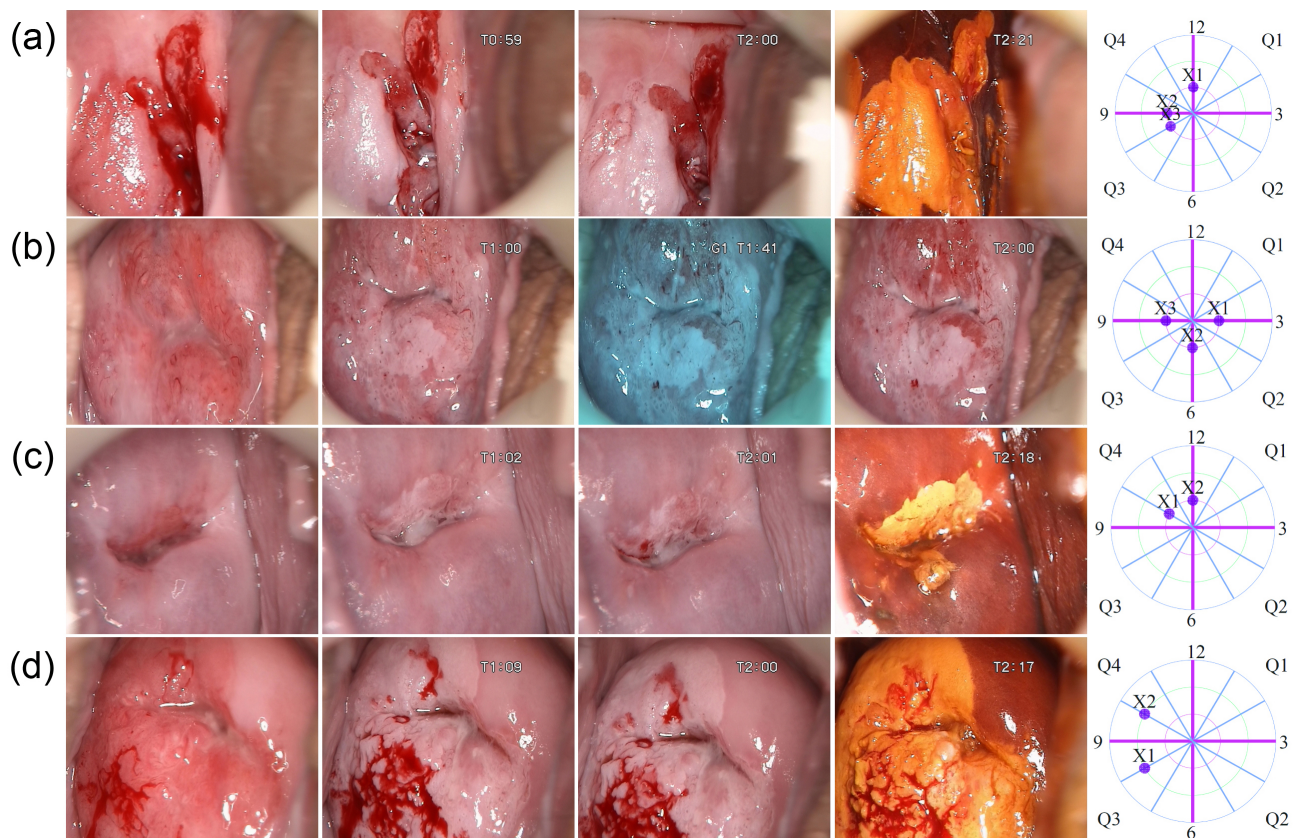


Fig. 2. The diagnostic criteria of the R-way system in the evaluation of HSIL+. (a), (b), (c), and (d) indicate the diagnostic criteria of the R-way system in the evaluation of HSIL+: (a), red thick white; (b), red white A; (c), red white yellow; and (d), bleeding.



ogenous lesions, necrosis, ulcers, etc.), suggestive of suspected invasive cancer changes; and miscellaneous features including condyloma acuminatum, polyps, and other obvious contact bleeding. (4) According to the above characteristics, the diagnosis of colposcopy is normal or inflammation, low-grade squamous intraepithelial lesion (LSIL), HSIL or invasive carcinoma [6, 9].

### 2.5 Reid colposcopy evaluation system

The overall evaluation scores for Reid's colposcopy range from 0–8 points, and the lesion is assigned a score from 0–2 points for each of the following features: the edge of the lesion, the colour of the acetic acid test, the shape of the blood vessel, and the results of the iodine test. Reid scores of 3–4 are usually associated with CIN1–2, and scores of 5–8 are usually associated with HSIL [7].

### 2.6 Pathological examination

Regardless of the final score, biopsy forceps were used to perform colposcopy-directed biopsy and/or cervical scraping of all abnormal areas. Routinely cervical biopsies are obtained from 3, 6, 9, or 12 o'clock positions of the cervix in cases of colposcopy imaging and endocervical curettage without abnormalities, if colposcopy was unsatisfactory and squamous junctions invisible or partially visible. If colposcopy was satisfactory, squamous junctions fully visible and no abnormal lesions were found, the patient may not undergo biopsy and be excluded from the analysis. According to the 2013 American Colposcopy and Cervical Pathology (ASCCP) guidelines, the pathological diagnosis was classified as follows: normal or inflammation; LSIL; HSIL; or cervical invasive carcinoma [5].

### 2.7 Statistical analysis

SPSS 21.0 software (SPSS Inc., Chicago, IL, USA) was used for statistical analysis. The analysis of consistency between the colposcopy diagnosis and pathological diagnosis was performed with the Kappa test.  $Kappa < 0.4$  meant poor consistency;  $0.4 > Kappa$  (0.75 meant medium consistency; and  $Kappa > 0.75$  meant good consistency. The sensitivity, specificity, positive predictive value (PPV) and negative predictive value (NPV) and the Youden index were used to evaluate the authenticity and predictive value of the diagnosis. The difference between the three evaluation methods was analysed with the McNemar test.  $P < 0.05$  was considered statistically significant.

## 3. Results

### 3.1 Consistency evaluation of colposcopy diagnosis and histopathology

The evaluation of consistency between the colposcopy diagnosis and histopathology included a total of 987 patients, with an average age of  $41.94 \pm 12.45$  years. The colposcopy diagnosis and pathological diagnosis of the R-way system were in agreement 69.00% (681/987) of the time, and the consistency of the test results showed a  $Kappa = 0.517$  ( $P < 0.001$ , 95% CI: 0.472–0.562). In patients with pathologi-

cal diagnoses of normal cervix or inflammation, LSIL, HSIL or cervical cancer, the consistency rates of colposcopy with the pathological diagnosis were 67.43% (352/522), 68.81% (203/295), 73.13% (98/134) and 77.77% (28/36), respectively. The rate of overestimation with the HSIL+ diagnosis was 1.18% (2/170), and that of the underestimation with the LSIL+ diagnosis was 21.51% (100/465). Table 1 shows the consistency of different colposcopy diagnostic methods and cervical histopathology. The consistency rate of the IFCPC diagnosis with histopathology was 75.28% (743/987), with  $Kappa = 0.599$  ( $P < 0.001$ , 95% CI: 0.556–0.642), and the consistency rate of the Reid diagnosis with histopathology was 55.32% (546/987), with  $Kappa = 0.310$  ( $P < 0.001$ , 95% CI: 0.263–0.357). The consistency levels of the R-way and IFCPC diagnose with the pathological diagnosis were medium, while that of the Reid diagnosis was poor.

### 3.2 Diagnostic value analysis of three colposcopy evaluation methods

In total 170 women (17.2%) had histologically confirmed HSIL+ including 36 women (3.6%) with invasive cervical cancer. The sensitivity for HSIL+ using the three different colposcopy evaluation methods were 74.7% (127/170), 78.2% (133/170) and 62.9% (107/170) for IFCPC, R-way and Reid. Table 2 summarizes the diagnostic value of colposcopy as a predictive indicator of a lesion histological diagnosis of HSIL+ and LSIL+. When HSIL was used as the critical value, the sensitivity, specificity, PPV and NPV of IFCPC and R-way for HSIL+ were better than those of the Reid system. The sensitivity and NPV of both R-way and IFCPC were better, but IFCPC had higher specificity and PPV. When LSIL was used as the critical value, the sensitivity of each method improved, the specificity was reduced, and the Youden index was not as high as that of HSIL as the critical value.

### 3.3 Comparison among three evaluation methods: R-way, Reid and IFCPC

Table 3 compares the accuracy of the three colposcopy assessment methods for HSIL+. The McNemar test results showed that the difference between R-way and IFCPC in the diagnosis of HSIL+ was statistically significant ( $\chi^2 = 19.558$ ,  $P < 0.001$ ); with  $Kappa = 0.826$ , the agreement rate was 94.6% (934/987). The difference between the Reid score and IFCPC for the diagnosis of HSIL+ was also statistically significant ( $\chi^2 = 17.876$ ,  $P < 0.001$ ); with  $Kappa = 0.127$ , the agreement rate was 70.62% (697/987).

## 4. Discussion

Colposcopy plays a very important role in the screening of cervical cancer. It can be used to identify precancerous lesions and early cervical cancer that are not recognized by the naked eye, thereby leading to timely treatment of cervical diseases, and can effectively prevent the occurrence and development of cervical cancer [10]. Colposcopy diagnostic methods have made great progress in many ways to date.

**Table 1. Consistency of different colposcopy diagnostic methods and cervical histopathology.**

Colposcopy method	Pathological diagnosis				Total
	Normal or inflammation	LSIL	HSIL	Cervical cancer	
R-way					
Normal inflammation	352 (35.66)	68 (6.89)	8 (0.81)	1 (0.10)	429
LSIL	125 (12.66)	203 (20.57)	26 (2.63)	2 (0.20)	356
HSIL	42 (4.26)	23 (2.33)	98 (9.93)	5 (0.51)	168
Cervical cancer	3 (0.30)	1 (0.10)	2 (0.20)	28 (2.84)	34
IFCPC					
Normal inflammation	419 (42.45)	70 (7.09)	9 (0.91)	1 (0.10)	499
LSIL	76 (7.70)	206 (20.87)	30 (3.04)	3 (0.30)	315
HSIL	25 (2.53)	18 (1.82)	92 (9.32)	6 (0.61)	141
Cervical cancer	2 (0.20)	1 (0.10)	3 (0.30)	26 (2.63)	32
Reid					
Normal inflammation	306 (31.00)	91 (9.22)	16 (1.62)	3 (0.30)	416
LSIL	138 (13.98)	144 (14.59)	39 (3.95)	5 (0.51)	326
HSIL	72 (7.29)	56 (5.67)	76 (7.7)	8 (0.81)	212
Cervical cancer	6 (0.61)	4 (0.41)	3 (0.30)	20 (2.03)	33

LSIL, low grade squamous intraepithelial lesion; HSIL, high grade squamous intraepithelial lesion; IFCPC, international federation for cervical pathology and colposcopy.

**Table 2. Accuracy of cervical histopathological diagnosis when colposcopy diagnosis is performed with different critical values.**

Diagnostic method	Critical value	Accuracy			Predictability		Comprehensive Youden index
		sensitivity%	Specificity%	Accuracy%	PPV	NPV	
IFCPC	HSIL+	74.71	94.37	90.98	73.41	94.72	0.691
	LSIL+	82.80	80.27	81.46	78.89	83.97	0.631
R-way	HSIL+	78.24	91.55	89.26	65.84	95.29	0.698
	LSIL+	83.44	67.43	74.97	69.53	82.05	0.509
Reid	HSIL+	62.94	83.11	79.64	43.67	91.51	0.461
	LSIL+	76.34	58.62	66.97	62.17	73.56	0.350

LSIL, low grade squamous intraepithelial lesion; HSIL, high grade squamous intraepithelial lesion; IFCPC, international federation for cervical pathology and colposcopy.

**Table 3. Comparison between IFCPC, R-way and Reid.**

	IFCPC		Total
	HSIL+	LSIL-	
R-way			
HSIL+	161 (16.31)	41 (4.15)	202
LSIL-	12 (1.22)	773 (78.32)	785
Reid			
HSIL+	64 (6.48)	181 (18.34)	245
LSIL-	109 (11.04)	633 (64.13)	742

LSIL, low grade squamous intraepithelial lesion; HSIL, high grade squamous intraepithelial lesion; IFCPC, international federation for cervical pathology and colposcopy.

The 2011 version of the IFCPC is the latest and most well-known international colposcopy guidance, representing the most recent global understanding of female precancerous lesions of the lower genital tract. The Reid colposcopy index (RCI) was first reported by Reid and Scalzi in 1985, and previous reports of the RCI [11–13] have shown good

correlation with histopathology, with values of 0.66–0.73. However, with the widespread popularity of cervical screening, typical precancerous colposcopy has become increasing less common, and the accuracy of colposcopy as a standard method has been questioned [14]. Many more recent studies have shown that the relationship between Reid colposcopy and histopathology is unsatisfactory, with values of 0.20–0.34 [15, 16]. The results of this study showed that the correlation of IFCPC and R-way with cervical histopathology was moderate but better than Reid. The correlation between the colposcopy diagnosis and histopathology was superior in previous reports of IFCPC by Li [17], with Kappa = 0.436, and Fan [18], with Kappa = 0.480.

In 2015, Zhao [8] compared the ability of the R-way system and conventional colposcopy to detect HSIL+. The R-way diagnosis of HSIL+ had a sensitivity of 77.8%, specificity of 94.5%, PPV of 85.5%, and NPV of 91.11%. In this study, the sensitivity, specificity, PPV and NPV of R-way and IFCPC for detecting HSIL+ were better than those of Reid. The sensitivity and NPV of both R-way and IFCPC were better,

but IFCPC had higher specificity and PPV. Reid's diagnosis of HSIL+ has high specificity and NPV, but the sensitivity is not high. Different studies have reported that the sensitivity, specificity, PPV and NPV of Reid's diagnosis of HSIL+ are quite different, suggesting that the Reid score is not consistent [11–13, 19, 20]. When LSIL is used as the critical value, the Youden index for the three evaluation methods is not as high as that when HSIL is used as the critical value, which shows that regardless of which evaluation system is used, colposcopy is most accurate in identifying HSIL+.

The results of the McNemar analysis of the three evaluation methods for colposcopy-based diagnosis of HSIL+ showed that the differences between R-way and IFCPC and between the Reid score and IFCPC were statistically significant; however, the consistency between R-way and IFCPC was better than that between the Reid score and IFCPC. The 2011 IFCPC replaces all previous versions of the terminology, synthesizes and refines multiple colposcopy diagnoses, adds multiple new terms and descriptions of vaginal lesions, and scientifically recategorizes some signs, and other items, for consistency among different hospitals and health care providers. The inspection level is similar to that of R-way, but the evaluation system requires technical support and trained personnel to master the operation. Therefore, the specificity of IFCPC for HSIL+ is high and the rate of missed diagnosis is low. The advantage of R-way is that it is easy to operate, and the diagnostic ideas are streamlined. By performing comparisons of captured images with a computer, the diagnostic path is made more clear, and the formula is established: red thick white, red white yellow, and red white A. Repeated training, combined with disease-based the objective analysis of the R-way system from Rigaku, leads to the diagnosis by colposcopy. This model is more suitable for promotion in primary-level hospitals to meet the demand driven by the high number of colposcopy physicians with varying skill levels in the vast areas of China, to improve the ability of colposcopy physicians to diagnose HSIL, and to meet the requirements of primary-level hospitals for cervical cancer screening.

In our study we performed biopsies from all four quadrants of the cervix in women with normal colposcopy. Regardless of skill, performing more biopsies increases the sensitivity of colposcopy [21], and eliminates validation bias. Dynamic Spectral Imaging System (DySIS) colposcopy seemed inferior to conventional colposcopy in detecting high-grade lesions and cannot replace conventional colposcopy with random biopsies [22]. The observed high sensitivity of the punch biopsy derived from all studies is probably the result of verification bias [23]. In a study from Norway, women with negative or low-grade cervical biopsies (normal/CIN1) were followed up after six months in order to decide on further follow-up or recall for screening at three-year intervals. Of 520 women with negative or low-grade biopsy, 124 women (23.8%) had CIN2+ on follow-up biopsy, including 7 cases of invasive cervical cancer [24]. Hence, all

women with negative colposcopy and biopsies after abnormal cytology and/or HPV-testing have to be followed.

The main advantage of this study is that regardless of whether the lesion was found on colposcopy, all subjects were biopsied, eliminating verification bias. This study also has certain limitations. First, 987 cases were included in the study. Second, it was a single-centre study, and no comparison with studies in other regions and medical institutions were made, which leads to some bias. Third, the case data included in this study are retrospective, thus, the 2011 version of IFCPC and the Reid scores were determined through colposcopy photos, and they do not fully represent real-life colposcopy.

In summary, the three colposcopy evaluation methods have high clinical diagnostic value and can be used for cervical cancer screening for HSIL+. Objective evaluation of cervical cancer screening for HSIL is necessary and can guide the clinical utility of IFCPC, whose sensitivity is highest, followed by R-way, and Reid, whose sensitivity is lowest. However, for mastery of IFCPC, a long training time is required. R-way is easy to learn and carry out. Therefore, when an evaluation method is to be chosen, it is necessary to consider the actual clinical circumstances during the decision process. The number of cases in this study is small, and the study has certain limitations. Studies with larger sample size are needed. and the sample size needs to be expanded for discussion in the future.

## Author contributions

FL and YXX planned the study. YXX, JH, and YFZ contributed in data collection. FL, YXX, and JH contributed and supervised the manuscript preparation. FL and YXX and DHH reviewed the statistical accuracy of analysis. All authors read and approved the final manuscript.

## Ethics approval and consent to participate

All patients signed informed surgical consent forms before undergoing colposcopy and were informed of the purpose of the study. The study was approved by the Second Affiliated Hospital of Jiaxing University ethics committee (JXEY-2020JX009).

## Acknowledgment

We would like to express my gratitude to all those who helped me during the writing of this manuscript.

## Funding

This research received no external funding.

## Conflict of interest

The authors declare no conflict of interest.

## References

- [1] World Health Organization. Cervical cancer. Overview. 2020. Available at: <https://www.who.int/health-topics/cervical-cancer>

r#tab=tab\_1 (Accessed: 22 April 2020).

- [2] HPV Information Centre. Human Papillomavirus and Related Cancers, Fact Sheet 2018. 2019. Available at: [https://hpvcentre.net/statistics/reports/CHN\\_FS.pdf](https://hpvcentre.net/statistics/reports/CHN_FS.pdf) (Accessed: 22 April 2020).
- [3] Luesley D, Leeson S, Desai M, Hadden P, Kitchener H, Martin-Hirsch P, *et al.* Colposcopy and programme management: guidelines for the NHS cervical screening programme. NHS CSP. Publication No.20. 2nd edn. 2010. Available at: <https://www.gov.uk/government/publications/cervical-screening-programme-and-colposcopy-management> (Accessed: 22 April 2020).
- [4] Zuchna C, Hager M, Tringler B, Georgouloupoulos A, Ciresa-Koenig A, Volgger B, *et al.* Diagnostic accuracy of guided cervical biopsies: a prospective multicenter study comparing the histopathology of simultaneous biopsy and cone specimen. *American Journal of Obstetrics and Gynecology*. 2010; 203: 321.e1–321.e6.
- [5] Massad LS, Jeronimo J, Katki HA, Schiffman M. The accuracy of colposcopic grading for detection of high-grade cervical intraepithelial neoplasia. *Journal of Lower Genital Tract Disease*. 2009; 13: 137–144.
- [6] Bornstein J, Bentley J, Bösze P, Girardi F, Haefner H, Menton M, *et al.* 2011 Colposcopic terminology of the international federation for cervical pathology and colposcopy. *Obstetrics & Gynecology*. 2012; 120: 166–172.
- [7] Ranga R, Rai S, Kumari A, Mathur S, Kriplani A, Mahey R, *et al.* A Comparison of the strength of association of reid colposcopic index and swede score with cervical histology. *Journal of Lower Genital Tract Disease*. 2017; 21: 55–58.
- [8] Zhao J, Zhang X, Chen R, Zhao Y, Wang T, He S, *et al.* Performance of the R-way colposcopic evaluation system in cervical cancer screening. *Asian Pacific Journal of Cancer Prevention*. 2015; 16: 4223–4228.
- [9] Quaas J, Reich O, Frey Tirri B, Küppers V. Explanation and use of the colposcopy terminology of the IFCPC (International Federation for Cervical Pathology and Colposcopy) Rio 2011. *Geburtshilfe. Frauenheilkd*. 2013; 73: 904–907.
- [10] Vercellino GF, Erdemoglu E, Chiantera V, Vasiljeva K, Malak A, Schneider A, *et al.* Clinical relevance of objectifying colposcopy. *Archives of Gynecology and Obstetrics*. 2015; 291: 907–915.
- [11] Durdi GS, Sherigar BY, Dalal AM, Desai BR, Malur PR. Correlation of colposcopy using Reid colposcopic index with histopathology- a prospective study. *Journal of the Turkish-German Gynecological Association*. 2009; 10: 205.
- [12] Shojaei H, Yarandi F, Ghazati L, Yarandi N, Izadi-Mood N, Eftekhari Z. Acceptable predictive accuracy of histopathology results by colposcopy done by Gynecology residents using Reid index. *Archives of Gynecology and Obstetrics*. 2013; 287: 345–349.
- [13] Boonlikit S. Performance of the abbreviated Reid colposcopic index in prediction of high-grade lesions. *International Journal of Gynaecology and Obstetrics*. 2016; 134: 41–44.
- [14] Apgar BS, Kaufman AJ, Bettcher C, Parker-Featherstone E. Gynecologic procedures: colposcopy, treatments for cervical intraepithelial neoplasia and endometrial assessment. *American Family Physician*. 2013; 87: 836–843.
- [15] Akhter S, Bari A, Hayat Z. Variability study between Pap smear, Colposcopy and Cervical Histopathology findings. *The Journal of the Pakistan Medical Association*. 2015; 65: 1295–1299.
- [16] Petousis S, Christidis P, Margioulas-Siarkou C, Sparangis N, Athanasiadis A, Kalogiannidis I. Discrepancy between colposcopy, punch biopsy and final histology of cone specimen: a prospective study. *Archives of Gynecology and Obstetrics*. 2018; 297: 1271–1275.
- [17] Li Y, Duan X, Sui L, Xu F, Xu S, Zhang H, *et al.* Closer to a uniform language in colposcopy: study on the potential application of 2011 international federation for cervical pathology and colposcopy terminology in clinical practice. *BioMed Research International*. 2017; 2017: 8984516.
- [18] Fan A, Wang C, Zhang L, Yan Y, Han C, Xue F. Diagnostic value of the 2011 International Federation for Cervical Pathology and Colposcopy Terminology in predicting cervical lesions. *Oncotarget*. 2018; 9: 9166–9176.
- [19] Kaban I, Cengiz H, Kaban A, Yildiz S, Ekin M, Avci E. Agreement between colposcopy results using the Reid Colposcopic Index and histopathology. *Ginekologia Polska*. 2015; 86: 537–540.
- [20] Suwanthananon C, Inthasorn P. A comparison of the associations of Reid Colposcopic Index and Swede Score with cervical histology. *Journal of Obstetrics and Gynaecology Research*. 2020; 46: 618–624.
- [21] Pretorius RG, Belinson JL, Burchette RJ, Hu S, Zhang X, Qiao Y. Regardless of skill, performing more biopsies increases the sensitivity of colposcopy. *Journal of Lower Genital Tract Disease*. 2011; 15: 180–188.
- [22] Roensbo MT, Hammer A, Blaakaer J. Can Dynamic Spectral Imaging System colposcopy replace conventional colposcopy in the detection of high-grade cervical lesions? *Acta Obstetrica et Gynecologica Scandinavica*. 2015; 94: 781–785.
- [23] Underwood M, Arbyn M, Parry-Smith W, De Bellis-Ayres S, Todd R, Redman CWE, *et al.* Accuracy of colposcopy-directed punch biopsies: a systematic review and meta-analysis. *BJOG: An International Journal of Obstetrics and Gynaecology*. 2012; 119: 1293–1301.
- [24] Sorbye SW, Arbyn M, Fismen S, Gutteberg TJ, Mortensen ES. HPV E6/E7 mRNA testing is more specific than cytology in post-colposcopy follow-up of women with negative cervical biopsy. *PLoS ONE*. 2011; 6: e26022.