

Retrospective review of sentinel lymph node mapping in endometrial cancer using indocyanine green and near infra-red fluorescence imaging during minimally invasive surgery

Woraphot Chaowawanit^{1,2,*}, Vicki Campbell¹, Emily Wilson¹, Naven Chetty¹, Lewis Perrin¹, Nisha Jagasia¹, Sinead Barry¹

¹Gynaecologic Oncology Unit, Mater Hospital, Brisbane, 4101 Queensland, Australia

²Gynecologic Oncology Unit, Department of Obstetrics and Gynecology, Faculty of Medicine, Navamindradhiraj University, 10300 Bangkok, Thailand

*Correspondence: woraphot@nmu.ac.th (Woraphot Chaowawanit)

DOI: [10.31083/j.ejgo4204106](https://doi.org/10.31083/j.ejgo4204106)

This is an open access article under the CC BY 4.0 license (<https://creativecommons.org/licenses/by/4.0/>).

Submitted: 3 February 2021 Revised: 25 February 2021 Accepted: 3 March 2021 Published: 15 August 2021

Objectives: To determine the feasibility of sentinel lymph node (SLN) mapping in early-stage endometrial cancer and to evaluate the impact of the SLN result on adjuvant therapy prescription. **Materials and methods:** 140 women with histologically confirmed endometrial cancer, treated with a minimally invasive hysterectomy, bilateral salpingo-oophorectomy and SLN mapping were included. All mapped SLNs were confirmed by histopathology. Where the SLN was negative on H&E staining, ultra-staging with IHC was performed. **Results:** From January 2017 to May 2019, 122 patients were analysed. The overall and bilateral SLN detection rates were 86% (105/122) and 73% (89/122), respectively. The detection rates were not significantly different between low and high-risk disease. SLN metastasis was found in 15% (3/20) of patients in the high-risk group and 5.7% (5/87) in the low-risk group. Six of the 8 cases were identified by ultra-staging. Fourteen of 103 patients had their adjuvant treatment reduced based on SLN status after ultra-staging. **Conclusion:** SLN mapping can reliably detect the SLN in low and high-risk disease. The advantage for SLN mapping is in low-risk patients that allowed them to receive appropriate adjuvant therapy. Ultra-staging with IHC increased the detection of positive SLNs and decreased the prescribed adjuvant therapy in 14% of our patients.

Keywords

Sentinel lymph node mapping; Endometrial cancer; Indocyanine green; Detection; Ultra-staging; Adjuvant treatment

1. Introduction

Endometrial cancer is the sixth most common cancer in females, worldwide. There were an estimated 382,000 new cases and 90,000 deaths in 2018. In Australia, endometrial cancer is the fifth most common cancer with 3040 new cases and 582 deaths in 2018 [1]. The majority of endometrial cancers are diagnosed as early stage, low grade tumours and have an excellent prognosis with 5-year survival rates exceeding 90% [2]. 5-year survival for node positive advanced stage disease in contrast is 50–58% [3, 4], with lymph node status being prognostic for recurrence and survival.

Pre-operative diagnosis is an important step to obtain a

cell type and histologic grade and make a decision of treatment plan. Currently, the diagnostic methods of endometrial cancer include dilatation and curettage (D&C), suction biopsy (Pipelle), vacuum aspiration biopsy random essay (Novak curette and Vabra aspirator), hysteroscopic endometrial biopsy, etc. Outpatient endometrial biopsy (Pipelle, Novak curette and Vabra aspirator) is a non-invasive technique comparing with D&C. Although this method has a high overall accuracy in diagnosing endometrial cancer [5], this is a blinded technique. An inadequate specimen causes a decrease in the diagnostic accuracy. Preoperative hysteroscopic biopsy can provide an adequate tissue. Grasp endometrial biopsy is one of a technique providing more accurate diagnosis of histology type and tumour grade when in presence of endometrioid type tumour compared to blind endometrial biopsy obtained using the Novak curette [6].

Standard treatment for early-stage endometrial cancer includes extrafascial hysterectomy with bilateral salpingo-oophorectomy [7]. For patients with disease apparently confined to the uterus and cervix, knowledge of pelvic and para-aortic lymph node status is important for accurate surgical staging, and for guiding adjuvant radiation therapy. Two randomized controlled trials have however failed to demonstrate a therapeutic advantage for systematic lymphadenectomy, although neither trial had a consistent policy with respect to the management of the paraaortic lymph nodes and did not utilize nodal status to direct adjuvant therapy [8, 9].

Low-risk patients, defined as grade 1 or 2 endometrioid histology, $\leq 50\%$ myometrial invasion and tumour diameter ≤ 2 cm, have $<1\%$ risk of lymph node metastasis, compared to intermediate- or high-risk patients who have a 20–25% risk. The risk of lymph node metastasis is up to 40% in those with non-endometrioid histology [10]. With such a low incidence of lymph node metastasis in the low-risk patients, the risks of exposing such patients to systematic lymphadenectomy are not justified.

Studies of systematic pelvic and para-aortic lymphadenectomy have consistently shown that patients with positive pelvic nodes have a 50% incidence of positive para-aortic nodes [11, 12]. In those with confirmed stage 3 disease, Mariani and colleagues concluded that both adequacy of pelvic and para-aortic dissection and delivery of adjuvant radiation to nodal beds independently reduced pelvic and paraaortic failures [13]. Hence knowledge of pelvic lymph node status is integral for the appropriate prescription of adjuvant treatment, especially in the node-positive patients, where the addition of systemic chemotherapy to radiation has also demonstrated an improvement in survival [2, 14].

Sentinel lymph node (SLN) mapping is an alternative technique that enables assessment of lymph node status and avoids the surgical complications associated with complete pelvic and para-aortic lymphadenectomy such as blood vessel or nerve injury, lymphocyst formation and lymphedema [15–17]. The techniques for lymphatic mapping are colorimetric mapping with coloured dyes, radionuclear mapping with technetium 99 (Tc99) and near-infrared fluorescence (NIRF) imaging with indocyanine green dye (ICG). A systematic review and meta-analysis of SLN mapping in endometrial cancer showed a pooled SLN detection rate of 81%, sensitivity of 96% and negative predictive value (NPV) of 99.7% [18]. The use of ICG with NIRF imaging, intracervical tracer injection, a SLN mapping algorithm and an ultra-staging protocol are all associated with improved detection rates, increased sensitivity to detect node positive patients and improved NPV [18–20].

At Mater Hospital Brisbane, we have been using ICG with NIRF imaging for SLN mapping as a part of surgical staging in all women with clinically uterus-confined endometrial cancer undergoing laparoscopic or robotic surgery since 2017. We conducted this pilot study to determine our detection rate and localization of mapped SLNs, to assess the safety of the technique within our institution as well as to assess the utilization of SLN biopsy results in informing decisions on adjuvant therapy compared to our existing staging and adjuvant therapy protocols.

2. Materials and methods

This retrospective study was approved by Mater Misericordiae Ltd Human Research Ethics Committee (HREC). From January 2017 to May 2019, all patients with histologically confirmed endometrial cancer were consented for laparoscopic or robotic hysterectomy, bilateral salpingo-oophorectomy and SLN mapping with ICG at Mater Hospital Brisbane, Queensland, Australia. The inclusion criteria were all patients with histologically confirmed endometrial cancer and radiologically confirmed FIGO stage I disease. Patients with extra-uterine disease on imaging were excluded. We further excluded any case where ICG injection was omitted or abandoned for any reason and any cases with incomplete medical records.

All surgeons were gynaecologic oncologists with significant experience in endoscopic surgery including lymphadenectomy and SLN mapping. KARL STORZ Image1 S OPAL1 for NIR/ICG was used in laparoscopic surgery and Firefly® NIRF on da Vinci Xi was used in robotic surgery. ICG, a soluble tricarboyanine dye, was diluted in 20 mL of sterile water (final concentration 1.25 mg/mL). After anaesthetic induction, a total of 4 mL (5 mg) of ICG was injected into the ectocervix: 1 mL superficially (3–4 mm into cervix) and 1 mL deep (1 cm into cervix) at the 3 and 9 o'clock positions. After exploration of abdominal cavity and peritoneal washing, the pelvic retroperitoneum was opened bilaterally. Mapped SLNs were visualized by a camera detecting NIRF light. The first mapped lymph node (first lymph node detected with fluorescence nearest to the uterine body) was defined as a SLN and was resected. Any suspicious or bulky lymph nodes were removed regardless of mapping and labelled non-SLN.

A comprehensive pelvic lymph node dissection was performed selectively in cases where SLN mapping failed to detect a SLN in either hemi-pelvic, only in those patients with intermediate and high-intermediate risk uterine features (grade 3 endometrioid, deep myoinvasion or bulky tumour), as per current institutional practice (**Supplementary Fig. 1**). Low risk patients (grade 1–2 endometrioid with superficial myoinvasion) were not staged further if SLN mapping failed because of a very low risk of nodal metastasis. Patients with deeply invasive high grade or invasive non-endometrioid tumours i.e., serous, clear cell, carcinosarcoma, were also not subjected to side specific systematic lymphadenectomy if SLN mapping failed, as under or institutional protocol these patients received adjuvant therapy with 4 cycles of chemotherapy and external beam pelvic radiation irrespective of nodal dissection. After SLN dissection, routine hysterectomy, bilateral salpingo-oophorectomy (BSO) was performed.

All specimens were analysed by pathologists specialized in gynaecologic cancers. All SLNs were sectioned and stained with haematoxylin and eosin (H&E). Ultra-staging was performed if the SLN was negative on initial H&E staining. Serial sectioning was performed with 250 μ m intervals. One H&E and 2 unstained slides were taken from each 5 levels. When additional H&E stained slides were negative, immunohistochemistry (IHC) staining for cytokeratin was used on unstained sections to detect microscopic metastasis (**Supplementary Fig. 2**). Non-SLNs were evaluated by H&E staining only. According to the American Joint Committee on Cancer definitions, macro-metastasis is defined as a tumour focus larger than 2 mm [21]. Tumour foci between 0.2 and 2 mm. are considered as micro-metastasis. Isolated tumour cells (ITCs) are defined as tumour deposits less than 0.2 mm. Mater Hospital Multi-Disciplinary Tumour Board Meeting made recommendations for adjuvant therapy for patients based on the final histopathology including SLN status utilising the adjuvant therapy protocol of Queensland Centre

for Gynaecological Cancer (QCGC) (**Supplementary Fig. 3**). All patients attended for follow up at 6 and 12 months after surgery.

All statistical analysis was performed using IBM SPSS Statistics for Windows, Version 22.0. (IBM Corp Armonk, NY, USA). Descriptive data were presented as mean with standard deviation (SD) for continuous variables and percentage for categorical variables. A Chi-square test was used to analyse the differences between two variables. Overall detection rate was defined as the percentage of patients undergoing SLN mapping in which at least one SLN was pathologically identified in either hemipelvis. Bilateral detection rate was defined as the percentage of patients with at least one SLN pathologically identified in each hemipelvis. A *p*-value of <0.05 was considered statistically significant.

3. Results

From January 2017 to May 2019, 140 patients with histologically confirmed endometrial cancer were consented for a minimally invasive hysterectomy, BSO and SLN mapping. ICG injection was cancelled due to patient factors in 9 cases (Fig. 1). Three cases had an extra-uterine disease, 3 cases had some surgical technique and anatomical problems, 1 case underwent full pelvic lymphadenectomy, 1 case had a suspicious synchronous vulvar cancer and 1 case did not record any reason. A further 9 cases were omitted due to incomplete medical records. SLN mapping was abandoned intra-operatively (despite prior ICG injection) in a further 11 cases due to morbid obesity (BMI ≥ 40 kg/m²), technical difficulty and advanced disease. We included these 11 patients in the failed bilateral SLN detection group. Decision regarding the abandonment of SLN mapping in these cases was made by the operating surgeons where the risk of potential complications associated with the technique exceeded the foreseeable benefit of the procedure.

The characteristics of the remaining 122 patients who were included in the analysis are summarized in Table 1. Eighty-five patients (70%) had a laparoscopic procedure and 37 patients (30%) had robotic surgery. Endometroid adenocarcinoma was the most common cell type diagnosed in pre- and post-operative histologic results.

3.1 SLN detection

Of the 122 cases who had ICG injected, SLNs mapped intra-operatively in 103 cases on the right side and 97 cases on the left. Pathologic results confirmed the presence of nodal tissue in 100 cases (82%) on the right and 94 cases (77%) on the left. The overall and bilateral detection rate, based on pathologically confirmed nodal tissue, was 86.1% and 73%, respectively (Table 2). The median number of SLNs removed was one (range 0–6 nodes). External iliac vessels were the most common detection site for the SLN.

In thirty cases (24.6%), the SLN was mapped to an at uncommon site (a site that is not included as part of routine pelvic lymph node dissection) including the high common iliac vessels, internal iliac vessels, parametria, infra-mesenteric

Table 1. Characteristics of 122 patients with endometrial cancer.

	Patients, N = 122 (%)
Mean age (years) \pm SD	62 \pm 11 (35–88)
Mean BMI (kg/m ²) \pm SD	33.5 \pm 7.4 (18–49)
Previous abdominal surgery	
- No	61 (50.0)
- Yes	61 (50.0)
Modality of surgery	
- Laparoscopic surgery	85 (69.7)
- Robotic surgery	37 (30.3)
Pre-operative histologic result	
- Endometrioid	111 (91.0)
- grade 1	83 (68.0)
- grade 2	19 (15.6)
- grade 3	9 (7.4)
- Non-endometrioid	11 (9.2)
- Serous	6 (4.9)
- Clear cell	1 (0.8)
- Mucinous	1 (0.8)
- Mixed	2 (1.6)
- Others	1 (0.8)
Post-operative histologic result	
- Atypical hyperplasia/No residual cancer	15 (12.3)
- Endometrioid	95 (77.9)
- grade 1	69 (56.6)
- grade 2	17 (13.9)
- grade 3	9 (6.6)
- Non-endometrioid	12 (10.0)
- Serous	10 (8.2)
- Carcinosarcoma	1 (0.8)
- Mucinous	1 (0.8)
Stage*	
- IA	87 (71.3)
- IB	21 (17.2)
- II	4 (3.3)
- IIIA	2 (1.6)
- IIIB	2 (1.6)
- IIIC1	4 (3.3)
- IVB	2 (1.6)
LVSI	
- Absent	97 (79.5)
- Present	25 (20.5)
Depth of myometrial invasion	
- <50%	93 (76.2)
- \geq 50%	29 (23.8)
Peritoneal washing cytology	
- Negative	100 (82.0)
- Positive	14 (11.5)

SD, standard deviation; BMI, body mass index; LVSI, lymphovascular space invasion.

* FIGO 2009 classification.

para-aortic and presacral regions. Six cases had non-SLN tissue removed due to suspicious or bulky nodes detected at time of procedure. One case of presumed non-SLN node tissue

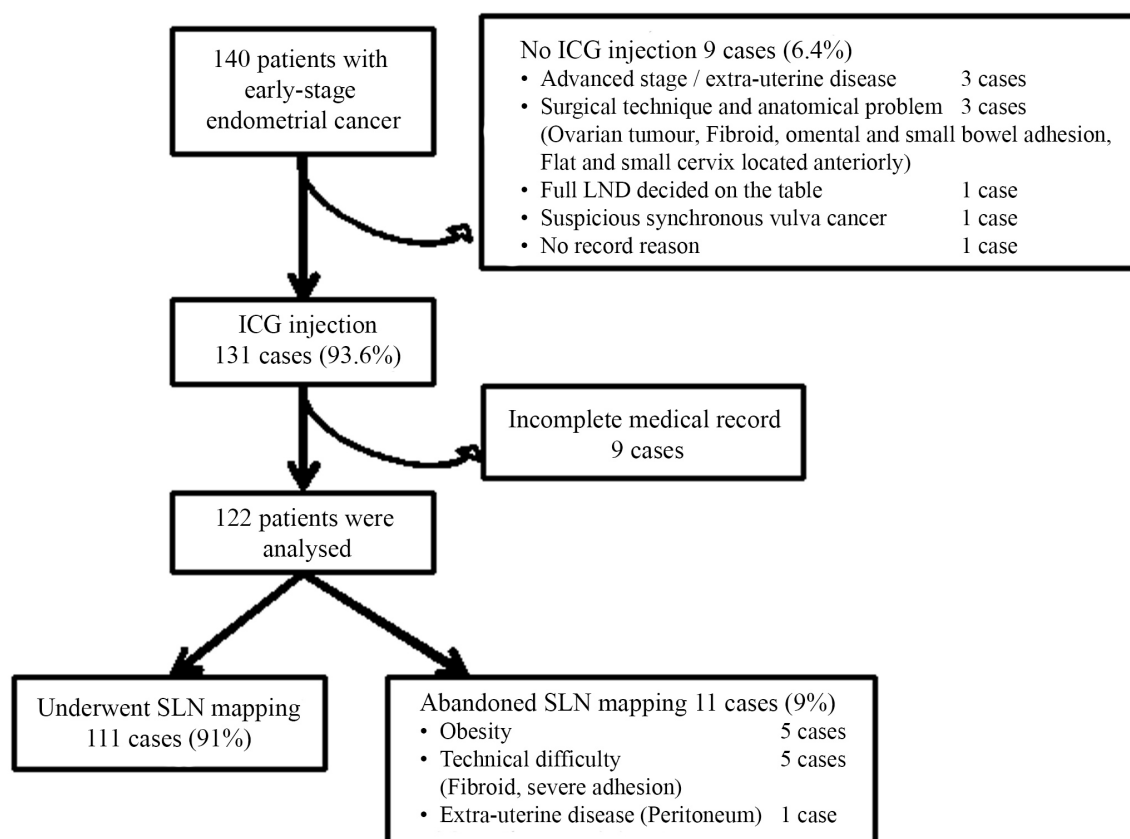


Fig. 1. Study profile.

Table 2. Sentinel lymph node characteristics.

Patients, N = 122 (%)		
SLN detection (Pathologic detection)		
- Overall detection	105 (86.1)	
- Bilateral detection	89 (73.0)	
- Unilateral detection	16 (13.1)	
- No detection	17 (13.9)	
	Right hemipelvis	Left hemipelvis
Hemipelvic detection	100 (82.0)	94 (77.0)
Median number of lymph nodes (range)	1 (0–4)	1 (0–6)
Site of SLN detection		
- External iliac	58 (47.5)	60 (49.2)
- Obturator	22 (18.0)	16 (13.1)
- Internal iliac	1 (0.8)	9 (7.4)
- Common iliac	15 (12.3)	9 (7.4)
- Parametrial	1 (0.8)	0 (0)
- Infra-mesenteric para-aortic	2 (1.6)	0 (0)
- Presacral	1 (0.8)	0 (0)

SLN, sentinel lymph node.

was not nodal tissue on final histopathology but a deposit of serous carcinoma. The other 5 cases were confirmed as nodal tissue and were all negative for metastasis.

In subgroup analysis of high-risk histology (endometrioid grade 3, serous, clear cell and carcinosarcoma), the overall and bilateral detection rates were 90.9% and 81.8%, respec-

tively. Although the patients with low-risk histology had lower overall and bilateral detection rates (85% and 71%, respectively), there was no significant difference between low and high-risk disease with a p -value = 0.47 for overall detection and a p -value = 0.30 for bilateral detection. Pathologic factors including depth of myometrial invasion, LVSI,

Table 3. Characteristics of 8 patients with positive sentinel lymph node.

Case NO.	Age (years)	BMI (kg/m ²)	Positive SLN	Site of positive SLN	Pre-operative histology	Post-operative histology	Stage*	GOG-99 risk	Adjuvant treatment
1	70	24	Isolated tumour cells	Internal iliac	Mixed high-grade	Serous	IB	High	CMT/RT
2	56	40	Macro-metastasis	External iliac	Endometrioid grade 1	Endometrioid grade 1	IIIC1	High-intermediate	CMT/RT
3	73	35	Isolated tumour cells	External iliac	Mucinous grade 1	Mucinous grade 1	II	Low-intermediate	RT
4	62	37	Isolated tumour cells	Common iliac	Endometrioid grade 2	Endometrioid grade 2	IB	High-intermediate	RT
5	55	40	Macro-metastasis	External iliac	Endometrioid grade 2	Endometrioid grade 3	IIIC1	High-intermediate	CMT/RT
6	51	43	Isolated tumour cells	Obturator	Endometrioid grade 1	Atypical hyperplasia	IA	Low-intermediate	No
7	66	28	Micro-metastasis	External iliac	Endometrioid grade 3	Endometrioid grade 3	IIIC1	High-intermediate	CMT/RT
8	79	46	Micro-metastasis	External iliac	Endometrioid grade 1	Endometrioid grade 1	IIIC1	Low-intermediate	CMT/RT

NO., number; BMI, body mass index; SLN, sentinel lymph node; CMT/RT, chemotherapy/radiation therapy; RT, radiation therapy.

* FIGO 2009 classification.

cell type, histologic grade, tumor size and peritoneal washing cytology were not predictors of SLN detection based on univariate analysis.

In terms of both overall and bilateral detection, BMI <30 kg/m² was a significant predictor of successful detection with p -value = 0.001 for overall detection and a p -value = 0.021 for bilateral detection. A previous history of abdominal surgery and modality of surgery (laparoscopic or robotic) did not affect the overall and bilateral detection rate.

3.2 SLN metastasis

SLN metastasis was found in 8 out of 122 patients (6.6%) who had ICG injected for the purposes of SLN mapping, or 7.2% of 111 patients who had SLN mapping performed. The characteristics of 8 patients with positive SLNs are shown in Table 3. The most common site of SLN metastasis was the external iliac region. Two positive SLNs were found at the internal iliac and high common iliac regions, areas not routinely dissected in systematic pelvic lymphadenectomy.

Three of 20 (15%) patients with high-risk histology (grade 3, serous or carcinosarcoma) had positive SLNs involved with metastatic disease, compared with 5 of 87 (5.7%) patients with low risk histology (grade 1 or 2 endometrioid, one case of low grade mucinous). Of the 105 patients who had at least one SLN detected, the ultra-staging protocol with IHC was used in 103 of these (98.1%). 1 of the 5-low risk, SLN positive patients, had a macro-metastasis, while 4 patients had SLN showing micro-metastasis or ITCs which were detected by the SLN ultra-staging protocol. In the three high-risk histology patients with SLN metastasis, one had macro-metastasis, one micro-metastasis and one patient had ITCs. Hence, 6 of the 8 (75%) positive SLNs were detected due to the ultra-staging technique.

3.3 Complication of SLN mapping

There were no intra-operative or post-operative complications associated with SLN mapping. Two patients had an intra-operative complication which was not related to SLN mapping. The first case had bladder injury during robotic surgery. She did not have a history of previous abdominal surgery and her BMI was 43 kg/m². SLN mapping was abandoned after ICG injection because of morbid obesity. The second case had a small area of thermal burn to the small bowel during laparoscopic surgery which was recognized and repaired. She did not have a history of previous abdominal surgery and her BMI was 30 kg/m². There were no other post-operative complications reported. Fifty patients have been seen at a 6-month post-operative surveillance visit and 28 patients have been followed to 12-months. There have been no cases of recurrent disease to date and no reported cases of symptomatic nor clinically significant lymphocyst or lymphedema.

3.4 Alteration of adjuvant treatment based on SLN status

After surgery, the adjuvant therapy was prescribed based on the adjuvant therapy protocol of Queensland Centre for Gynaecological Cancer (QCGC) (**Supplementary Fig. 3**). Without knowledge of lymph node status (based on uterine features alone) 37 of 122 patients (30.3%) would receive adjuvant treatment. Using the adjuvant therapy protocol, it was predicted that radiation therapy (RT) would be prescribed in 37 cases (30.3%), with the addition of chemotherapy (CMT/RT) in 27 cases (22.1%), based on high-risk features.

Based on SLN status, predicted adjuvant therapy as per uterine features was altered in 16 out of the 103 patients (15.5%) that underwent successful SLN mapping. This represents 13% of the entire cohort of patients (Fig. 2). Case NO.4 would have been prescribed CMT/RT based on the lo-

[24]. This information may be helpful for counselling patients about the success rate of SLN mapping.

Recent literature reports SLN mapping as having a good detection of positive lymph nodes. Fifteen percent (range 10–30%) of all mapped SLNs were positive and 50% of positive SLNs were diagnosed after ultra-staging [19]. In our study, 6.6% of all patients had positive SLN which is consistent with 80% of our participants having a low to moderately differentiated endometrioid adenocarcinoma and 70% having disease confined to the inner half of the myometrium, putting this group at low risk of lymph node involvement.

Ultra-staging was required for the diagnosis of metastatic disease (in the form of micro-metastasis or ITCs) in 6 of the 8 patients with positive SLNs (75%). This is relevant as despite a comprehensive pelvic lymphadenectomy, these 6 patients would not have had their LN metastasis detected by standard H&E staining methods, confirming the value of an ultra-staging protocol is confirmed in our series.

In our series 5.7% of low risk patients, who would not have undergone lymph node assessment according to our pre-existing staging algorithm, were found to have positive SLNs and were upstaged. This allowed these patients to have adjuvant therapy to reduce their risk of recurrence.

Our study reported high detection rates (90.9% for overall detection and 81.8% for bilateral detection) for patients with high-risk histological subtypes. Several studies in patients with high-risk histology have confirmed excellent performance of SLN mapping using cervical injection with bilateral detection in the order of 60% and NPV exceeding 98% [32–34]. In this cohort, 21–30% of mapped SLNs are positive, with a low false negative rate (2–5%) [32, 33]. In our study 15% of patients with high-risk histology had positive SLNs. This percentage may be an underestimation as our study population only included 20 patients with high-risk histology and we did not perform full lymphadenectomy following SLN mapping in our high-risk patients.

Large retrospective data review from the Surveillance, Epidemiology, and End Results (SEER) Program showed a survival benefit from more extensive lymphadenectomy in the high-risk group [3]. It is likely that the same survival benefits can be achieved from SLN mapping, with SLN status used to prescribe chemotherapy and pelvic +/- para-aortic radiation to patients with positive pelvic nodes.

The limitations of this study are that this is a retrospective study susceptible to biases, including surgical bias to abandon SLN mapping in difficult cases, and bias in prescription of adjuvant therapy based on various patient factors. We did not perform full pelvic lymphadenectomy in patients after SLN mapping and hence cannot provide sensitivity, specificity or false negative rate for our institution. These are the major disadvantage of our study so we cannot conclude that SLN mapping can replace full lymphadenectomy in high-risk group. However, in our unit, prior to SLN mapping, selective pelvic lymphadenectomy was performed in those with intermediate and high intermediate risk features on frozen section

and our series does demonstrate that SLN mapping was effectively implemented into the existing staging paradigm as the vast majority of patients in the intermediate and high-risk groups were able to avoid comprehensive staging lymphadenectomy. Further limitations include incomplete medical records which resulted in patient exclusion. An additional limitation is that long-term survival data is not yet available on all participants treated.

The strengths of this study are that it was conducted in a tertiary centre with a high incidence of endometrial cancer. The study has captured the majority of sentinel lymph node mapping cases from the introduction of the technique into our institution's staging protocol. This study is the first to our knowledge that illustrates the potential impact of SLN status on recommendations for adjuvant therapy in apparent early stage endometrial cancer compared with a protocol that prescribed adjuvant therapy based on uterine features. Long term survival data would be required to validate this approach however our high bilateral SLN detection rates and detection of SLN metastasis are equivocal to published reports indicating reliable detection of node positive patients.

5. Conclusions

Despite no prior experience with the technique, our detection rates were comparable with those in the literature showing effective implementation of the SLN mapping technique at our institution. We have shown that SLN mapping can be incorporated into the treatment protocol for endometrial cancer without compromising operative safety. Positive nodes located outside the standard lymphadenectomy field may be missed without SLN mapping. Ultra-staging with IHC increased the detection of positive SLNs.

The clear advantage for sentinel node mapping is in low-risk patients, who would not otherwise have a lymphadenectomy. The detection of occult nodal metastasis in 5.7% of these patients in our study allowed them to receive appropriate adjuvant therapy.

Knowledge of the SLN status in our cohort resulted in a reduction in the amount of adjuvant therapy required in a subgroup of patients, hence reducing treatment related morbidity. We await longer follow-up to observe the impact of this on patient recurrence risk and survival. Further studies should be conducted prospectively to evaluate the impact of SLN mapping on prescribed adjuvant therapy, patterns of disease recurrence and disease free and overall survival.

Author contributions

WC collected the data, managed the database and wrote the manuscript. VC and EW collected the data. NC and LP performed the staging surgery and sentinel lymph node mapping. NJ designed the study, performed the staging surgery and sentinel lymph node mapping and edited the manuscript. SB designed the study, and edited the manuscript. All authors read and approved the final manuscript.

Ethics approval and consent to participate

This retrospective study was approved by Mater Misericordiae Ltd Human Research Ethics Committee (HREC). Approval number is HREC/MML/46596.

Acknowledgment

We thank to professor Neville Hacker for his opinion and suggestions during preparation of the manuscript.

Funding

This study received no external funding.

Conflict of interest

The authors declare no conflict of interest.

Supplementary material

Supplementary material associated with this article can be found, in the online version, at <https://ejgo.imrpress.com/EN/10.31083/j.ejgo4204106>.

References

- [1] Ferlay J, Colombet M, Soerjomataram I, Mathers C, Parkin DM, Piñeros M, *et al.* Estimating the global cancer incidence and mortality in 2018: GLOBOCAN sources and methods. *International Journal of Cancer*. 2019; 144: 1941–1953.
- [2] Amant F, Moerman P, Neven P, Timmerman D, Van Limbergen E, Vergote I. Endometrial cancer. *Lancet*. 2005; 366: 491–505.
- [3] Chan JK, Cheung MK, Huh WK, Osann K, Husain A, Teng NN, *et al.* Therapeutic role of lymph node resection in endometrioid corpus cancer. *Cancer*. 2006; 107: 1823–1830.
- [4] Lewin SN, Herzog TJ, Medel NIB, Deutsch I, Burke WM, Sun X, *et al.* Comparative performance of the 2009 international federation of gynecology and obstetrics' staging system for uterine corpus cancer. *Obstetrics & Gynecology*. 2010; 116: 1141–1149.
- [5] Clark TJ, Mann CH, Shah N, Khan KS, Song F, Gupta JK. Accuracy of outpatient endometrial biopsy in the diagnosis of endometrial cancer: a systematic quantitative review. *BJOG: An International Journal of Obstetrics and Gynaecology*. 2002; 109: 313–321.
- [6] Di Spizio Sardo A, De Angelis MC, Della Corte L, Carugno J, Zizolfi B, Guadagno E, *et al.* Should endometrial biopsy under direct hysteroscopic visualization using the grasp technique become the new gold standard for the preoperative evaluation of the patient with endometrial cancer? *Gynecologic Oncology*. 2020; 158: 347–353.
- [7] Amant F, Mirza MR, Koskas M, Creutzberg CL. Cancer of the corpus uteri. *International Journal of Gynecology & Obstetrics*. 2018; 143: 37–50.
- [8] Panici PB, Basile S, Maneschi F, Lissoni AA, Signorelli M, Scambia G, *et al.* Systematic pelvic lymphadenectomy vs no lymphadenectomy in early-stage endometrial carcinoma: randomized clinical trial. *Journal of the National Cancer Institute*. 2008; 100: 1707–1716.
- [9] Kitchener H, Swart AMC, Qian Q, Amos C, Parmar MKB. Efficacy of systematic pelvic lymphadenectomy in endometrial cancer (MRC ASTEC trial): a randomised study. *Lancet*. 2009; 373: 125–136.
- [10] Mariani A, Dowdy SC, Cliby WA, Gostout BS, Jones MB, Wilson TO, *et al.* Prospective assessment of lymphatic dissemination in endometrial cancer: a paradigm shift in surgical staging. *Gynecologic Oncology*. 2008; 109: 11–18.
- [11] Nomura H, Aoki D, Suzuki N, Susumu N, Suzuki A, Tamada Y, *et al.* Analysis of clinicopathologic factors predicting para-aortic lymph node metastasis in endometrial cancer. *International Journal of Gynecological Cancer*. 2006; 16: 799–804.
- [12] Kumar S, Podratz KC, Bakkum-Gamez JN, Dowdy SC, Wever AL, McGree ME, *et al.* Prospective assessment of prevalence of pelvic, paraaortic and high paraaortic lymph node metastasis in endometrial cancer. *Gynecologic Oncology*. 2014; 132: 38–43.
- [13] Mariani A, Dowdy SC, Cliby WA, Haddock MG, Keeney GL, Lesnick TG, *et al.* Efficacy of systematic lymphadenectomy and adjuvant radiotherapy in node-positive endometrial cancer patients. *Gynecologic Oncology*. 2006; 10: 200–208.
- [14] de Boer SM, Powell ME, Mileschkin L, Katsaros D, Bessette P, Haie-Meder C, *et al.* Adjuvant chemoradiotherapy versus radiotherapy alone for women with high-risk endometrial cancer (PORTEC-3): final results of an international, open-label, multicenter, randomised, phase 3 trial. *Lancet Oncology*. 2018; 19: 295–309.
- [15] Bohrer JC, Walters MD, Park A, Polston D, Barber MD. Pelvic nerve injury following gynecologic surgery: a prospective cohort study. *American Journal of Obstetrics and Gynecology*. 2009; 201: 531.e1–531.e7.
- [16] Abu-Rustum NR, Alektiar K, Iasonos A, Lev G, Sonoda Y, Aghajanian C, *et al.* The incidence of symptomatic lower-extremity lymphedema following treatment of uterine corpus malignancies: a 12-year experience at Memorial Sloan-Kettering Cancer Center. *Gynecologic Oncology*. 2006; 103: 714–718.
- [17] Frost JA, Webster KE, Bryant A, Morrison J. Lymphadenectomy for the management of endometrial cancer. *Cochrane Database of Systematic Reviews*. 2017; 10: CD007585.
- [18] Bodurtha Smith AJ, Fader AN, Tanner EJ. Sentinel lymph node assessment in endometrial cancer: a systematic review and meta-analysis. *American Journal of Obstetrics and Gynecology*. 2017; 216: 459–476.e10.
- [19] Holloway RW, Abu-Rustum NR, Backes FJ, Boggess JF, Gotlieb WH, Jeffrey Lowery W, *et al.* Sentinel lymph node mapping and staging in endometrial cancer: a society of gynecologic oncology literature review with consensus recommendations. *Gynecologic Oncology*. 2017; 146: 405–415.
- [20] Barlin JN, Khoury-Collado F, Kim CH, Leitao MM, Chi DS, Sonoda Y, *et al.* The importance of applying a sentinel lymph node mapping algorithm in endometrial cancer staging: beyond removal of blue nodes. *Gynecologic Oncology*. 2012; 125: 531–535.
- [21] Edge SB, Compton CC. *AJCC Cancer Staging Manual*. 7th edn. New York: Springer. 2010.
- [22] National Comprehensive Cancer Network. Uterine Neoplasm (Version 1.2021). 2021. Available at: https://www.nccn.org/professionals/physician_gls/pdf/uterine.pdf (Accessed: 21 February 2021).
- [23] Ianieri MM, Della Corte L, Campolo F, Cosentino F, Catena U, Bifulco G, *et al.* Indocyanine green in the surgical management of endometriosis: a systematic review. *Acta Obstetrica et Gynecologica Scandinavica*. 2021; 100: 189–199.
- [24] Jewell EL, Huang JJ, Abu-Rustum NR, Gardner GJ, Brown CL, Sonoda Y, *et al.* Detection of sentinel lymph nodes in minimally invasive surgery using indocyanine green and near-infrared fluorescence imaging for uterine and cervical malignancies. *Gynecologic Oncology*. 2014; 133: 274–277.
- [25] Papadia A, Imboden S, Siegenthaler F, Gasparri ML, Mohr S, Lanz S, *et al.* Laparoscopic indocyanine green sentinel lymph node mapping in endometrial cancer. *Annals of Surgical Oncology*. 2016; 23: 2206–2211.
- [26] Buda A, Crivellaro C, Elisei F, Di Martino G, Guerra L, De Ponti E, *et al.* Impact of indocyanine green for sentinel lymph node mapping in early stage endometrial and cervical cancer: comparison with conventional radiotracer ^{99m}Tc and/or blue dye. *Annals of Surgical Oncology*. 2016; 23: 2183–2191.
- [27] Plante M, Touhami O, Trinh X, Renaud M, Sebastianelli A, Grondin K, *et al.* Sentinel node mapping with indocyanine green and endoscopic near-infrared fluorescence imaging in endometrial cancer: a pilot study and review of the literature. *Gynecologic Oncology*. 2015; 137: 443–447.

- [28] Rossi EC, Kowalski LD, Scalici J, Cantrell L, Schuler K, Hanna RK, *et al.* A comparison of sentinel lymph node biopsy to lymphadenectomy for endometrial cancer staging (FIRES trial): a multicentre, prospective, cohort study. *Lancet Oncology*. 2017; 18: 384–392.
- [29] Hagen B, Valla M, Aune G, Ravlo M, Abusland AB, Araya E, *et al.* Indocyanine green fluorescence imaging of lymph nodes during robotic-assisted laparoscopic operation for endometrial cancer: a prospective validation study using a sentinel lymph node surgical algorithm. *Gynecologic Oncology*. 2016; 143: 479–483.
- [30] Taşkın S, Şükür YE, Altın D, Ersöz CC, Turgay B, Kankaya D, *et al.* Laparoscopic near-infrared fluorescent imaging as an alternative option for sentinel lymph node mapping in endometrial cancer: a prospective study. *International Journal of Surgery*. 2017; 47: 13–17.
- [31] Taşkın S, Sarı ME, Altın D, Ersöz CC, Gökçe A, Yüksel S, *et al.* Risk factors for failure of sentinel lymph node mapping using indocyanine green/near-infrared fluorescent imaging in endometrial cancer. *Arch Gynecol Obstet*. 2019; 299: 1667–1672.
- [32] Touhami O, Grégoire J, Renaud M, Sebastianelli A, Plante M. Performance of sentinel lymph node (SLN) mapping in high-risk endometrial cancer. *Gynecologic Oncology*. 2017; 147: 549–553.
- [33] Soliman PT, Westin SN, Dioun S, Sun CC, Euscher E, Munsell MF, *et al.* A prospective validation study of sentinel lymph node mapping for high-risk endometrial cancer. *Gynecologic Oncology*. 2017; 146: 234–239.
- [34] Ehrisman J, Secord AA, Berchuck A, Lee PS, Di Santo N, Lopez-Acevedo M, *et al.* Performance of sentinel lymph node biopsy in high-risk endometrial cancer. *Gynecologic Oncology Reports*. 2016; 17: 69–71.