

Abnormal magnetic resonance imaging of the sellar region and its surroundings in patients with pituitary abscess

Zhifeng Wu¹, Yanwu Qiu¹, Haiqing Lin¹, Shousen Wang^{2,*}

¹Department of Neurosurgery, Fujian Armed Police Corps Hospital, 350003 Fuzhou, Fujian Province, China

²Department of Neurosurgery, The 900th Hospital, Fuzong Clinical School of Fujian Medical University, 350025 Fuzhou, Fujian Province, China

*Correspondence: wshsen@126.com (Shousen Wang)

DOI: [10.31083/j.jin2002045](https://doi.org/10.31083/j.jin2002045)

This is an open access article under the CC BY 4.0 license (<https://creativecommons.org/licenses/by/4.0/>).

Submitted: 16 December 2020 Revised: 3 March 2021 Accepted: 22 March 2021 Published: 30 June 2021

Pituitary abscess is a rare disease with a high preoperative misdiagnosis rate. Magnetic resonance imaging is the primary method for confirming pituitary abscesses before surgery. We reported magnetic resonance imaging findings of four cases of pituitary abscess (three males and one female) aged from 33 to 72 years old. All four cases underwent transnasal sphenoid surgery and had a good prognosis. The findings on magnetic resonance imaging were analyzed. Three cases showed ring enhancement of the capsule wall. Four cases showed thickened pituitary stalk, with the diameter of the lower end larger than that of the upper end. The position of the pituitary stalk where it was inserted into the upper edge of the pituitary was located at the middle and posterior 1/3 junction of the upper edge of the pituitary two cases were with the enhancement of the dura mater at the bottom of the temporal lobe. Two cases were with the enhancement of the dura mater of the petroclival region, and one case was with the enhancement of the cavernous sinus. There are few articles concerning abnormal magnetic resonance imaging around the sellar region of pituitary abscess. The findings of the four cases in this article suggest that the pituitary abscess has characteristic abnormal magnetic resonance imaging of the sellar region and its surroundings.

Keywords

Pituitary abscess; Brain imaging; Clinical endocrinology; Neurovascular structures

1. Introduction

Pituitary abscess is a clinically rare but life-threatening inflammatory disease of the pituitary gland [1]. More than 300 patients have been reported so far were misdiagnosed before surgery [2]. Before surgery, a preliminary diagnosis is essential for formulating surgical plans and perioperative management [3]. Imaging is the primary method to confirm the diagnosis of pituitary abscess before surgery. Magnetic resonance imaging (MRI) has a rich imaging series. It can provide imaging clues that computerized tomography (CT) and other examinations cannot provide. On enhanced pituitary MRI scan, the ring enhancement in the sellar region is a characteristic imaging manifestation of pituitary abscess [4]. However, some pituitary abscesses do not have a characteristic imaging manifestation of ring enhancement [5]. Therefore, more characteristic imaging manifestation should be explored by

using MRI and other methods.

2. Case one

A 72-year-old female underwent transnasal resection of pituitary adenoma in sellar in 2013. In July 2014, she was referred to our hospital due to a recurrence of pituitary adenoma. After admission, MRI plain scan and an enhanced scan showed a cystic lesion in the sellar region with the size of $1.2 \times 0.9 \times 2.1$ cm (Fig. 1A–D). The lesion extended to the suprasellar and parasellar, with iso intensity on both T1WI and T2WI. The upper clinoid process of the bilateral internal carotid arteries shifted out, and part of them was embedded. The sellar bone was thinned due to bone absorption, while the nasal septum mucosa was thickened. After enhanced scanning, the lesion showed ring enhancement, with an uneven thickness of the enhanced cystic wall. The pituitary stalk was thickened and strengthened. The dura mater on bilateral temporal lobes and petroclival region were enhanced (Table 1). Serum hormone levels: free triiodothyronine (FT3) of 3.22 pmol/L (normal value 3.5–6.5 pmol/L), thyroid stimulating hormone (TSH) of 0.151 μ IU/mL (normal value 0.55–4.78 μ IU/mL), and estradiol of 22.51 pg/mL (normal value 28–156 pg/mL). The levels of other hormones were in a normal range. The results of routine blood tests were normal. Thus, the preoperative diagnosis was a recurrence of a pituitary tumor. A transnasal pituitary removal surgery was performed on 19 July 2014. After the sellar bottom was opened, pale-yellow viscous pus was observed. After removing of pus, no tumor tissue was detected. Many neutrophils and blood residues were observed on the pus smear, but no tumor cells were seen. The postoperative diagnosis was confirmed as a pituitary abscess. After surgery, ceftriaxone sodium, tazobactam sodium and levothyroxine sodium were administered. Re-examination by head CT (Fig. 1E) was performed three months after surgery, showing no recurrence of the pituitary abscess. Serum hormone levels were in the normal range.

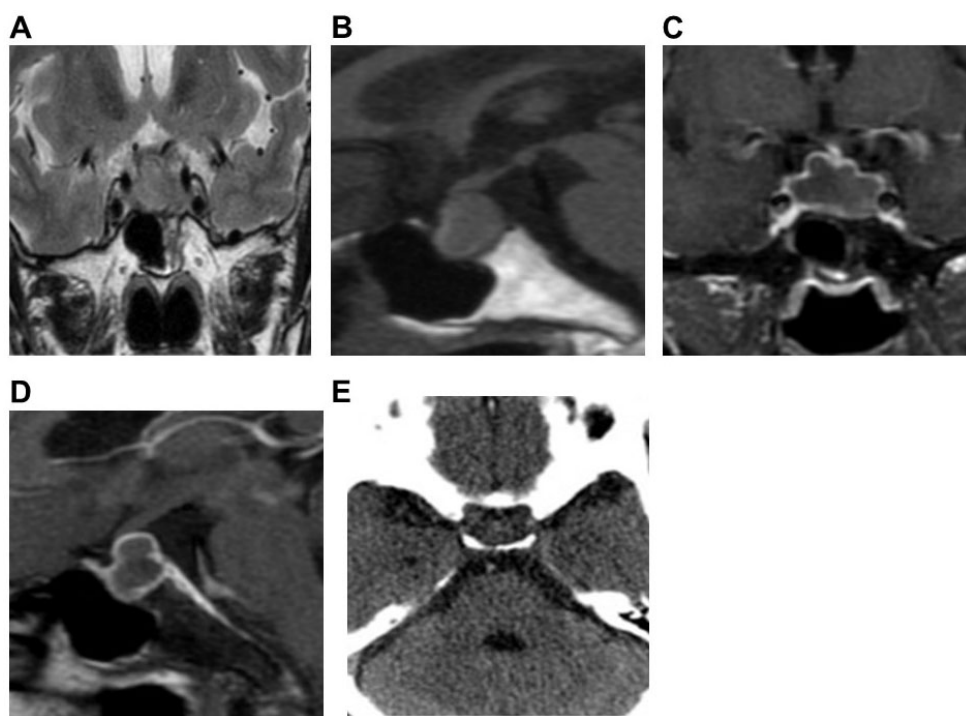


Fig. 1. Preoperative pituitary MRI and postoperative CT of Case 1. Preoperative coronal (A) and sagittal (B) MRI scans showed cystic lesions in the sellar. Both T1WI and T2WI were isointensity. There were sellar bone resorption and thickening of nasal septum mucosa. Preoperative coronal (C) and sagittal (D) enhanced MRI scan showed ring enhancement of the cyst wall, thickening and enhancement of the pituitary stalk, enhancement of the dura mater on both sides of the temporal lobe and petroclival region. Postoperative CT (E) showed no recurrence of the pituitary abscess.

3. Case two

A 45-year-old male was admitted to a local clinic in February 2009 due to headache, fever and weakness of the limbs. After admission, he had a body temperature as high as 39.5 °C and received anti-infection treatment. Then, the body temperature was returned to normal, but the headache had not been improved. Pituitary MRI imaging (plain and enhanced scan) (Fig. 2A–D) showed sellar nodular lesions sized about $1.8 \times 1.6 \times 1.7$ cm. There was a low signal on T1WI and a slightly high signal on T2WI. After enhanced scanning, there was ring enhancement, thickened and enhanced pituitary stalk and bilateral cavernous sinus enhancement. Serum hormone levels: FT3 2.18 pmol/L, follicle-stimulating hormone (FSH) 0.75 mIU/mL (normal value 1.4–18.1 mIU/L), cortisol 0.6 µg/dL (normal value 4.3–22.4 µIU/mL), luteinizing hormone (LH) 0.01 mIU/mL (normal value 1.5–9.3 mIU/L), and testosterone 0.01 µg/L (normal value 14–76 µg/L). The results of blood routine tests were normal. Lumbar puncture showed the pressure of cerebrospinal fluid was 120 mm H₂O. The biochemistry analysis results of the cerebrospinal fluid showed a total protein level of 0.46 g/L (normal value 0.15–0.45 g/L), normal glucose level, and normal chloride level. The bacterial culture showed negative results. Preoperative diagnosis was confirmed as a pituitary abscess. A transnasal pituitary abscess removal was performed on 7 July 2009. During the operation, the pus was pale yellow and thick, and the abscess wall consisted of white thickened pitu-

itary tissue. Cefoperazone sodium, tazobactam sodium, and prednisone tablets were administrated postoperatively. Pituitary MRI was reviewed six months after surgery (Fig. 2E–G). No recurrence of the pituitary abscess was found.

4. Case three

A 49-year-old male was admitted in 2013 due to headache and sexual dysfunction lasting half a year and worsening one week. Pituitary MRI imaging (plain and enhanced scan) (Fig. 3A–D) showed cystic lesions in the sellar, about $2.0 \times 1.2 \times 0.8$ cm in size, with fluid level visible inside, uneven and slightly high signal on T1WI, and slightly high signal on T2WI. The optic chiasm was compressed and degenerated. On the enhanced scan, there was ring enhancement of the posterior cystic wall. The pituitary stalk was thickened and enhanced (Table 1). Serum hormone levels: increased growth hormone 1.26 ng/mL (normal value <1 ng/mL), TSH 0.144 µIU/mL, adrenocorticotrophic hormone 2.33 pg/mL (normal value 4.7–48.8 pg/mL), FSH 1.11 mIU/mL, LH 0.11 mIU/mL, and cortisol 0.73 µg/dL. Preoperative diagnosis was made as pituitary adenoma. A transnasal pituitary removal surgery was performed on 26 August 2013. During the operation, the mucosa of the sphenoid sinus was thickened. After opening the dura of the sellar floor, yellow-green pus gushed out. The intraoperative diagnosis was made as a pituitary abscess. After treatment with meropenem, rifampicin, and levothyroxine sodium tablets,

Table 1. MRI characteristics of pituitary abscess and its surrounding sellar region.

Case	1	2	3	4
T1 signal	Isointense	Low	Slightly high	Low
T2 signal	Isointense	Slightly high	Slightly high	High
Ring enhancement	Thickened wall, uneven	Thickened wall, uneven	Thickened wall, uneven	N/A
The position of pituitary stem inserted into the upper edge of the pituitary gland	The middle and posterior 1/3 junction of the upper edge of the pituitary gland	The middle and posterior 1/3 junction of the upper edge of the pituitary gland	The middle and posterior 1/3 junction of the upper edge of the pituitary gland	The middle and posterior 1/3 junction of the upper edge of the pituitary gland
Pituitary stalk				
Diameter of upper end (mm)	1.6	5.1	3.1	2.1
Diameter of lower end (mm)	4.4	6.2	3.7	3.6
Length (mm)	9.0	8.6	7.3	6.7
Shape	Right deviation, uniform thickening	Right deviation, uniform thickening	Right deviation, uniform thickening	Bend and thickened evenly
Meningeal enhancement	Clivus, bilateral temporal lobe dura enhancement	Clivus, dura enhancement	Bilateral temporal lobe dura enhancement	N/A
Cavernous sinus involvement	N/A	Bilateral cavernous sinus enhancement	N/A	N/A
Peritumoral enhancement	N/A	N/A	N/A	N/A
Paranasal sinus inflammation	N/A	N/A	Thickening of sphenoid sinus mucosa	Thickening of sphenoid sinus mucosa, submucosal empyema
Others	Thinning of the sellar bone and thickening of the mucosa of the nasal septum	N/A	Intrasaccular fluid level	N/A

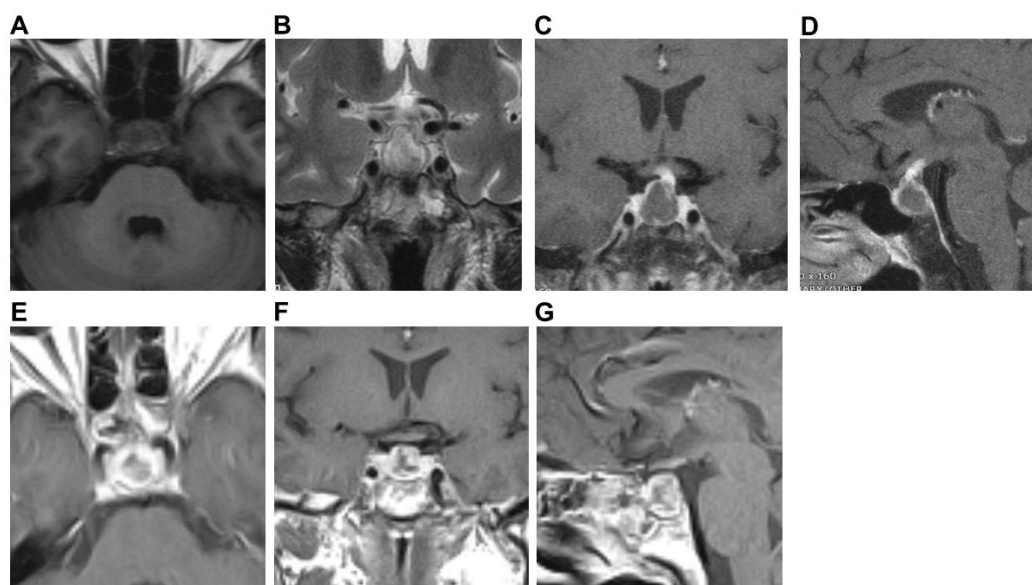


Fig. 2. Preoperative pituitary MRI and postoperative MRI of Case 2. Preoperative axial (A) and coronal (B) MRI scans showed cystic lesions in the sellar, T1WI low signal, and T2WI slightly high signal. Preoperative coronal (C) and sagittal (D) MRI enhanced scan showed ring enhancement of the cyst wall, thickening and enhancement of the pituitary stalk, and bilateral cavernous sinus enhancement. Postoperative axial (E), coronal (F), and sagittal (G) MRI showed no recurrence of the pituitary abscess.

the headache was improved, and there was no diabetes insipidus. The recurrence of the pituitary abscess was found on MRI 1 year after operation (Fig. 3E–H). Serum hormone levels: cortisol 0.46 $\mu\text{g/dL}$, LH 0.58 mIU/mL, and testosterone 0.01 $\mu\text{g/L}$. He was referred to another hospital and underwent endoscopic transsphenoidal pituitary abscess removal

on December 20, 2014. Pituitary abscess was diagnosed during the surgery. Vancomycin, biapenem, and metronidazole were administered after the operation. There was no recurrence of pituitary abscess on the MRI examination for one and a half years after operation (Fig. 3I,J).

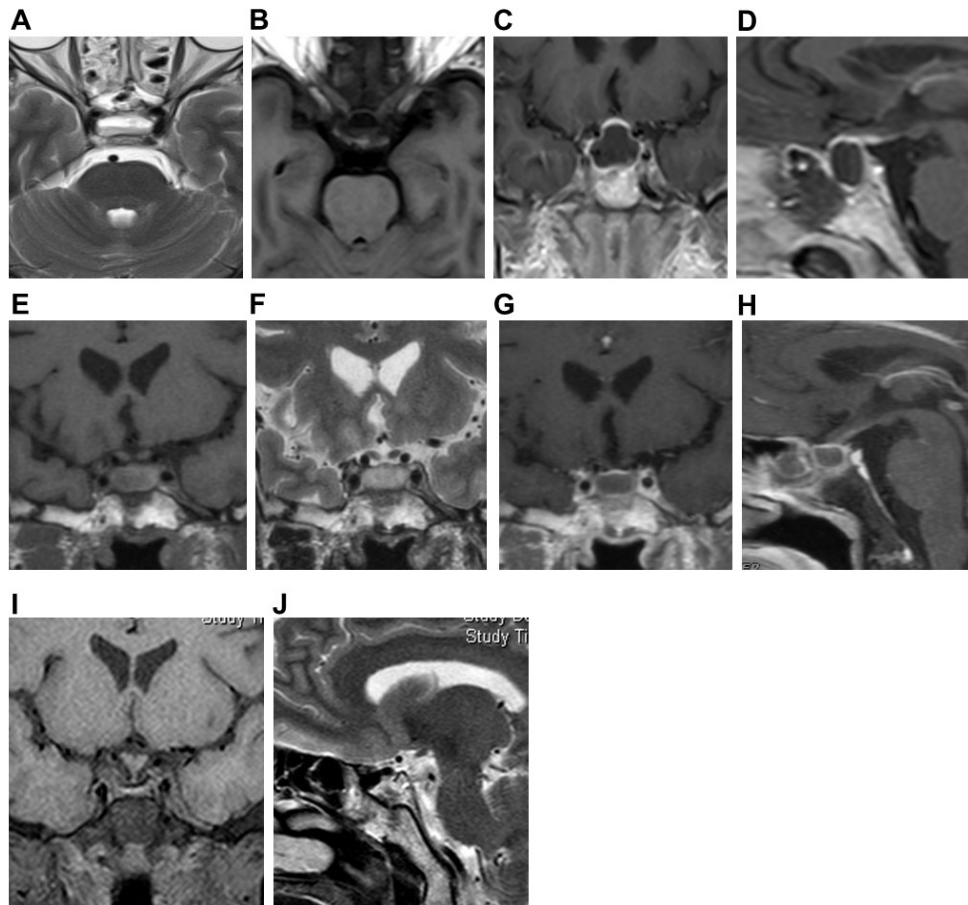


Fig. 3. Pituitary gland MRI of Case 3. Preoperative axial (A,B) MRI plain scans showed cystic lesions in the sellar region. T1WI showed uneven and slightly high signal, and T2WI showed a slightly high signal, with a fluid plane inside. Preoperative coronal (C) and sagittal (D) MRI enhanced scan showed ring enhancement of the cyst wall, thickened and enhanced pituitary stalk. Postoperative coronal (E,F) MRI plain scan showed cystic lesions in the sellar. T1WI showed a high signal, T2WI showed a slightly high signal. There was sphenoid Sinus mucosal thickening with effusion. Postoperative coronal (C) and sagittal (D) enhanced MRI scans showed ring enhancement of the capsule wall. Coronal (I) and sagittal (J) MRI plain scans after the second operation showed no recurrence of the pituitary abscess.

5. Case four

A 33-year-old male was admitted in February 2006 due to decreased libido for several years and headache for two months. Pituitary MRI imaging (plain and enhanced scan) (Fig. 4A–D) showed cystic lesions in the sellar, about $3 \times 1.8 \times 1.6$ cm in size, with low signal on T1WI and high signal on T2WI. There was apparent thickening of the sphenoid sinus mucosa at the sellar floor and submucosal effusion. On an enhanced scan, the posterior cystic wall was partly enhanced (Table 1) serum hormone level: testosterone $1.88 \mu\text{g/L}$. Preoperative diagnosis was made as a pituitary abscess. A transnasal pituitary abscess removal was performed on December 5, 2006. During the operation, the pus was yellow and viscous (Fig. 4E). After surgery, cefpiramide sodium was administrated. After three years, re-examination of head CT (Fig. 4F) showed no recurrence of the pituitary abscess.

6. Discussion

The incidence of pituitary abscess is extremely low, which accounted for no more than 1% of pituitary diseases [6, 7]. Moreover, pituitary abscess is slightly more common in females. Most of the published literature focusing on pituitary abscess were case reports [1, 3], with the most significant number of cases (66 cases) in [8]. It has been shown that preoperative diagnosis of a pituitary abscess is challenging [9, 10].

The characteristic clinical manifestations of a pituitary abscess include pituitary hypofunction (the adrenal axis, thyroid axis, and gonadal axis are simultaneously affected) and symptoms of the neurohypophysis and hypothalamus damage (such as diabetes insipidus, lethargy, abnormal behavior, etc.) [2, 11]. Among four patients, only one case had total hypopituitarism. No patient had symptoms of neurohypophysis or hypothalamus damage. However, three had a headache, one had a fever, and three had partial hypopituitarism. Therefore, while paying attention to the clinical manifestations of

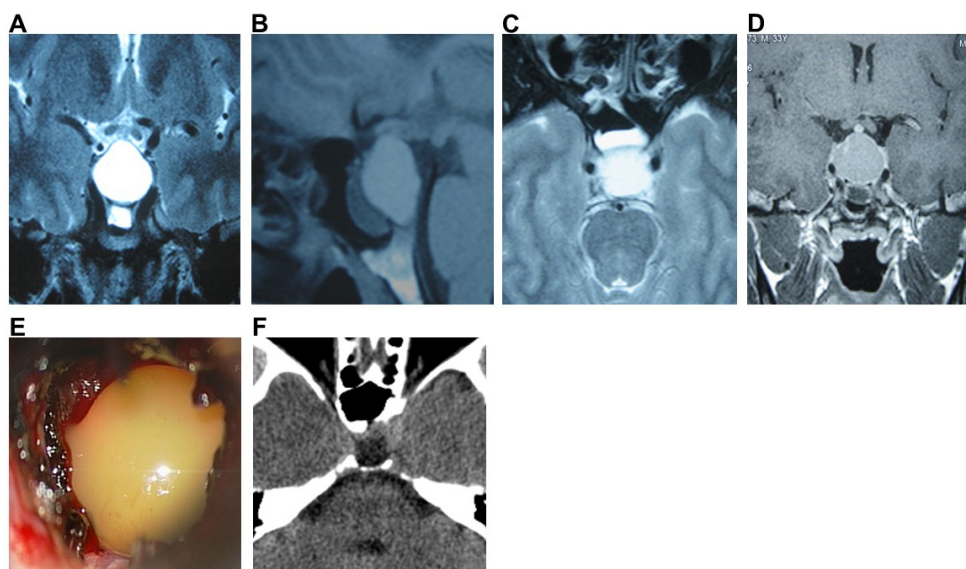


Fig. 4. Preoperative pituitary MRI, intraoperative image and postoperative CT of Case 4. Preoperative coronal (A), sagittal (B), and axial (C) MRI plain scans showed cystic lesions in the sellar region, low signal on T1WI, high signal on T2WI. The mucosa of the sphenoid sinus at the sellar floor was significantly thickened. Submucosal effusion was observed. Preoperative coronal (D) enhanced MRI scan showed partial enhancement of the cyst wall. During operation (E), the pus was yellow and viscous. Postoperative head CT (F) showed no recurrence of the pituitary abscess.

hypopituitarism, neurohypophysis and hypothalamus damage, a comprehensive analysis should be carried out in conjunction with the symptoms of headache, fever, and invasion of surrounding tissues caused by inflammation.

Recently, with the increase in the number of reported cases of pituitary abscess and the development of MRI technology, some characteristic MRI manifestations of pituitary abscess have been observed [12–14]. The pituitary abscess may show ring enhancement without internal enhancement during an enhanced scan. The abscess cavity may show a high signal in diffusion-weighted imaging, with a decreased apparent diffusion coefficient, and the abscess wall may show low signal. However, not all pituitary abscesses have characteristic imaging manifestations such as ring enhancement [15]. Among the four patients, one case did not have ring enhancement. In addition, some pituitary abscesses have atypical ring enhancement or only have small cysts [5, 16], which are not easily distinguished from cystic pituitary adenomas and Rathke cysts in the sellar. This highlights the importance of exploring other imaging features of the pituitary abscess.

Thickening of the pituitary stalk is also considered an essential imaging manifestation of a pituitary abscess. Still, no detailed characteristics of thickening of the pituitary stalk caused by pituitary abscess have been reported. We observed the shape of the pituitary stalk, the position of the pituitary stalk where it was inserted into the upper edge of the pituitary and measured the length, upper and lower diameter of the pituitary stalk. We found that the length of the pituitary stalk of these four patients ranged from 6.7 mm to 9.0 mm. Within the range of normal pituitary stalk length, 3 cases of the pituitary stalk were rightward, one case was bent, three cases were tapered and thickened, and 1 case was cylindrical.

In all four cases, the diameter of the lower end of the pituitary stalk was more significant than that of the upper end, which was different from the standard pituitary stalk and the thickened pituitary stalk related to the posterior pituitary ectopic, lymphoma, solid cancer metastasis and other diseases [17].

We observed for the first time that the diameter of the lower end of the pituitary stalk was larger than that of the upper end in patients with pituitary abscess regardless of the shape of the thickened pituitary stalk. This may be because the inflammatory damage of the pituitary stalk gradually starts from the lower end of the pituitary stalk. In normal anatomy, the position of the pituitary stalk where it is inserted into the upper edge of the pituitary is mainly at the junction of the middle and posterior 1/3 of the upper edge of the pituitary. There is no report on the influence of the pituitary abscess on the position of the pituitary stalk where it is inserted into the upper edge of the pituitary. In all four cases of this study, the position of the pituitary stalk where it is inserted into the upper edge of the pituitary was all at the middle and posterior 1/3 junction of the upper edge of the pituitary, which may suggest that the abscess has extensive damage to the pituitary tissue.

The enhancement of surrounding tissues of the sellar, including that of the dura mater at the base of the temporal lobe, the petroclival region, the cavernous sinus, the optic chiasm, etc., is caused by inflammation of the pituitary glands [15]. Two cases had temporal lobe base dura mater enhancement, two cases had petroclival region dura mater enhancement, and one case had cavernous sinus involvement and enhancement.

In this article, MRI images of one case showed severe inflammation in the mucosa of the sphenoid sinus at the bottom of the sellar. It has been reported that inflammation of the structures around the pituitary, such as sphenoid sinusitis, meningitis, and cavernous sinus thrombophlebitis, is one of the causes of pituitary abscess [18–21]. This type of abscess is called a primary pituitary abscess. Cases three and four had sphenoid sinusitis, which may be a causative factor for their pituitary abscess. The inflammatory manifestations of the sphenoid sinus and other parts have particular significance for diagnosing pituitary abscesses before surgery. In addition, pituitary adenomas, craniopharyngiomas, and Rathke's cysts secondary to sellar lesions after surgery are another major cause of the pituitary abscess. Abscesses that occur in the pituitary gland with lesions are called secondary pituitary abscesses. Here, case 1 had a history of pituitary adenoma surgery, which may cause her secondary pituitary abscess. However, the cause of secondary pituitary abscess in case 2 was unclear.

Although it has been reported that some patients have been cured by drug treatment [22], incision and drainage of the pituitary abscess through the sphenoid sinus approach combined with postoperative anti-inflammatory therapy is still the first choice. The four patients in this study were treated with incision and drainage of the pituitary abscess through the nasal sphenoid approach. Three cases did not have a recurrence, and one case relapsed one year after surgery and recovered. Recurrence is considered to be related to persistently low hormone levels and insufficient drainage [23].

7. Conclusions

In conclusion, there were 3 cases with ring enhancement of the capsule wall, 4 cases with a thickened pituitary stalk (with the diameter of the lower end larger than that of the upper end), two cases with enhancement of dura mater at the bottom of the temporal lobe, two cases with enhancement of dura mater of the petroclival region, and one case with enhancement of cavernous sinus. These abnormal imaging findings around the sellar region are reliable presentations for diagnosing a of pituitary abscess, often unavailable in other sellar lesions. Combined with the ring enhancement of the lesion, the medical history, and clinical manifestations, most cases of pituitary abscess can be confirmed before surgery.

Abbreviations

FSH, follicle-stimulating hormone; FT3, free triiodothyronine; LH, luteinizing hormone; TSH, thyroid stimulating hormone.

Author contributions

ZW and SW designed the research study. ZW and YQ performed the research. ZW and HL analyzed the data. ZW wrote the manuscript. All authors contributed to editorial changes in the manuscript. All authors read and approved

the final manuscript.

Ethics approval and consent to participate

The Ethics Committee approved this study of Fujian Armed Police Corps Hospital. Written informed consent was obtained from each patient.

Acknowledgment

Thanks to all the peer reviewers for their opinions and suggestions.

Funding

This research received no external funding.

Conflict of interest

The authors declare no conflict of interest.

References

- [1] Karagiannis AKA, Dimitropoulou F, Papatheodorou A, Lyra S, Seretis A, Vryonidou A. Pituitary abscess: a case report and review of the literature. *Endocrinology, Diabetes & Metabolism Case Reports*. 2016; 2016: 160014.
- [2] Cabuk B, Caklili M, Anik I, Ceylan S, Celik O, Ustun C. Primary pituitary abscess case series and a review of the literature. *Neuro Endocrinology Letters*. 2019; 40: 99–104.
- [3] Nordjoe YE, Aubin Igombe SR, Laamrani FZ, Jroundi L. Pituitary abscess: two case reports. *Journal of Medical Case Reports*. 2019; 13: 342.
- [4] Liu Y, Liu F, Liang Q, Li Y, Wang Z. Pituitary abscess: report of two cases and review of the literature. *Neuropsychiatric Disease and Treatment*. 2017; 13: 1521–1526.
- [5] Chaichana K, Larman T, Salvatori R. Pituitary abscess with unusual MRI appearance. *Endocrine*. 2016; 54: 837–838.
- [6] Kotani H, Abiru H, Miyao M, Kakimoto Y, Kawai C, Ozeki M, *et al*. Pituitary abscess presenting a very rapid progression. *The American Journal of Forensic Medicine and Pathology*. 2012; 33: 280–283.
- [7] Bangera S, Singh RK, Al Asousi AA, Chattopadhyay A, Joseph E. Primary pituitary abscess with coexisting pyogenic meningitis: an unexpected diagnosis. *The American Journal of the Medical Sciences*. 2013; 345: 75–77.
- [8] Gao L, Guo X, Tian R, Wang Q, Feng M, Bao X, *et al*. Pituitary abscess: clinical manifestations, diagnosis and treatment of 66 cases from a large pituitary center over 23 years. *Pituitary*. 2017; 20: 189–194.
- [9] Liu F, Li G, Yao Y, Yang Y, Ma W, Li Y, *et al*. Diagnosis and management of pituitary abscess: experiences from 33 cases. *Clinical Endocrinology*. 2011; 74: 79–88.
- [10] Wang L, Yao Y, Feng F, Deng K, Lian W, Li G, *et al*. Pituitary abscess following transsphenoidal surgery: the experience of 12 cases from a single institution. *Clinical Neurology and Neurosurgery*. 2014; 124: 66–71.
- [11] Zhang X, Sun J, Shen M, Shou X, Qiu H, Qiao N, *et al*. Diagnosis and minimally invasive surgery for the pituitary abscess: a review of twenty nine cases. *Clinical Neurology and Neurosurgery*. 2012; 114: 957–961.
- [12] Takayasu T, Yamasaki F, Tominaga A, Hidaka T, Arita K, Kurisu K. A pituitary abscess showing high signal intensity on diffusion-weighted imaging. *Neurosurgical Review*. 2006; 29: 246–248.
- [13] Takao H, Doi I, Watanabe T. Diffusion-weighted magnetic resonance imaging in pituitary abscess. *Journal of Computer Assisted Tomography*. 2006; 30: 514–516.
- [14] Shuster A, Gunnarsson T, Sommer D, Miller E. Pituitary abscess: an unexpected diagnosis. *Pediatric Radiology*. 2010; 40: 219–222.

- [15] Wang Z, Gao L, Zhou X, Guo X, Wang Q, Lian W, *et al.* Magnetic resonance imaging characteristics of pituitary abscess: a review of 51 cases. *World Neurosurgery*. 2018; 114: e900–e912.
- [16] Medić Stojanoska M, Kozić D, Bjelan M, Vuleković P, Vučković N, Vuković B, *et al.* Pituitary abscess with unusual clinical course. *Acta Clinica Croatica*. 2016; 55: 650–654.
- [17] Turcu AF, Erickson BJ, Lin E, Guadalix S, Schwartz K, Scheithauer BW, *et al.* Pituitary stalk lesions: the Mayo Clinic experience. *The Journal of Clinical Endocrinology and Metabolism*. 2013; 98: 1812–1818.
- [18] Muscas G, Iacoangeli F, Lippa L, Carangelo BR. Spontaneous rupture of a secondary pituitary abscess causing acute meningoencephalitis: case report and literature review. *Surgical Neurology International*. 2017; 8: 177.
- [19] Ovenden CD, Almeida JP, Oswari S, Gentili F. Pituitary abscess following endoscopic endonasal drainage of a suprasellar arachnoid cyst: case report and review of the literature. *Journal of Clinical Neuroscience*. 2019; 68: 322–328.
- [20] Liu J, Penn DL, Katznelson E, Safain MG, Dunn IF, Laws ER Jr. Demonstration of infectious transgression through the skull base occurring 9 years after pituitary adenoma resection. *World Neurosurgery*. 2018; 119: 215–219.
- [21] Vates GE, Berger MS, Wilson CB. Diagnosis and management of pituitary abscess: a review of twenty-four cases. *Journal of Neurosurgery*. 2001; 95: 233–241.
- [22] Uchida Y, Tsuchimochi N, Oku M, Fujihara N, Shimono N, Okada K, *et al.* Successful treatment of pituitary abscess with oral administration of sparfloxacin. *Internal Medicine*. 2008; 47: 1147–1151.
- [23] Furnica RM, Lelotte J, Duprez T, Maiter D, Alexopoulou O. Recurrent pituitary abscess: case report and review of the literature. *Endocrinology, Diabetes & Metabolism Case Reports*. 2018; 2018: 17–0162.