

# On clinical findings of Bickerstaff's brainstem encephalitis in childhood

Giulia Messina<sup>1</sup>, Sarah Sciuto<sup>1</sup>, Alessandra Fontana<sup>1</sup>, Filippo Greco<sup>2</sup>, Claudia F. Oliva<sup>1</sup>, Maria Grazia Pappalardo<sup>1</sup>, Annamaria Sapuppo<sup>1</sup>, Pierluigi Smilari<sup>2</sup>, Piero Pavone<sup>2,\*</sup>, Rosario Foti<sup>3</sup>

<sup>1</sup>Department of Clinical and Experimental Medicine, University of Catania, 95100 Catania, Italy

<sup>2</sup>Department of Clinical and Experimental Medicine, University Hospital "Policlinico-San Marco", 95123 Catania, Italy

<sup>3</sup>Rheumatology Operative Unit, University Hospital "Policlinico-San Marco", 95123 Catania, Italy

\*Correspondence: [ppavone@unict.it](mailto:ppavone@unict.it) (Piero Pavone)

DOI: [10.31083/j.jin2002054](https://doi.org/10.31083/j.jin2002054)

This is an open access article under the CC BY 4.0 license (<https://creativecommons.org/licenses/by/4.0/>).

Submitted: 26 January 2021 Revised: 9 March 2021 Accepted: 12 April 2021 Published: 30 June 2021

A short review on the clinical presentation of pediatrics cases of Bickerstaff brain encephalitis emphasizing the broad clinical spectrum of the disease. Cases of pediatric Bickerstaff's brainstem encephalitis collected on three electronic medical databases (PubMed, Cochrane Library and Scopus Web of Science) are reviewed. The inclusion criteria of the cases were based on the clinical characteristics of the disorder in the pediatric age. We reviewed 20 articles on Bickerstaff's brainstem encephalitis, identifying 40 pediatric cases focused on the clinical symptoms. We saw that the prevalence was higher in male subjects, and the median age at diagnosis was 8 years. The phenotype of pediatrics patients was similar to previously published literature. We identify three cases of overlapping forms between Bickerstaff brain encephalitis and Guillain-Barré Syndrome in patients with lower limbs weakness and typical signs of Bickerstaff brain encephalitis, suggesting a combined involvement of the central and peripheral nervous system. Although there is no defined data on incidence and prevalence in the literature, Bickerstaff's brainstem encephalitis appears to be a rare disorder, especially in children. The incidence of Bickerstaff brain encephalitis and Guillain-Barré Syndrome, and Miller Fisher Syndrome has been underrated in the past, primarily due to an underestimation of the forms with a Peripheral Nervous System involvement. Bickerstaff brain encephalitis usually has a rapid and acute onset within 2–4 weeks, characterized by a typical picture of ophthalmoplegia, hyperreflexia, cerebellar symptoms as ataxia. The subsequent manifestations of hyperreflexia or consciousness disturbances as drowsiness, sleepiness, or coma, indicative of central involvement, suggest a Bickerstaff brain encephalitis clinical diagnosis.

## Keywords

Clinical; Symptoms; Bickerstaff; Encephalitis; Pediatrics; Brainstem

## 1. Introduction

Bickerstaff brainstem encephalitis (BBE) is considered a rare [1], often postinfectious, autoimmune encephalitis, first described in 1951 and 1957 by Bickerstaff *et al.* [1, 2], characterized by ophthalmoplegia, ataxia, and altered consciousness. The disorder shares some features with other inflammatory demyelinating neuropathies: Miller Fisher Syn-

drome (MFS) and Guillain-Barré Syndrome (GBS); the three diseases form a continuous spectrum of autoimmune and postinfectious diseases [3]. The Guillain-Barré polyneuropathy is the most frequent of them, and it is characterized by acute onset, rapidly progressive, symmetrical muscular weakness, and hyporeflexia [2–4]. The MFS and BBE are reported to be less frequent than GBS. The MFS is characterized by a triad of ophthalmoplegia, ataxia and areflexia [5] and BBE by central nervous system (CNS) involvement with alteration of consciousness or long tract signs beyond the classical ophthalmoplegia and ataxia [5]. BBE occurs after a previous respiratory or gastro-enteric infection. After an apparent remission, the patient starts to show the main features: ophthalmoplegia, ataxia, hyperreflexia, loss of consciousness or drowsiness till coma.

However, the nosologic classification of Bickerstaff's brainstem encephalitis, Guillain-Barré syndrome and Miller Fisher syndrome remains uncertain. In addition, many patients with overlap between these conditions have been reported, and there is variable CNS and PNS involvement in the spectrum of these diseases [6, 7].

Diagnosis is founded upon clinical findings, history for recent upper tract infections, and laboratory and instrumental studies. Brain Magnetic Resonance Imaging (MRI) can help diagnose BBE when lesions are evident. In most cases, brain MRI documents abnormalities with hyperintensity in white matter, especially in thalamic regions. Anti-GQ1b IgG antibodies are positive in two-thirds of cases, but their detection could be possible even in MFS; despite this, its high specificity and sensitivity usually allow a correct diagnosis; a frequent observation is a raised protein level CSF with or without pleocytosis. Nerve conduction velocity (NCV) studies show a picture of demyelinating neuropathy with decreasing of NCV, presence of blockages, and other suggestive signs.

Standard treatment consists of Intravenous Immunoglobulin (IVIG) or steroid, single or as combined strategy, and plasmapheresis [8–12]. The diagnostically and therapeutical options are beyond the scope of our review. Moreover, in

the suspicion of BBE is necessary to consider the possibility of belonging to a more complex group of disorders such as ophthalmoplegia, ataxia, and areflexia (SOAA). Some Authors reported one case of transient coma following SOAA after a previous type B flu infection. In addition, an extensive brainstem injury including reticular formation was found, and evidence of cerebrospinal CSF antibodies serum IgG anti-GQ1b in the acute phase.

This review explores 40 cases of pediatric BBE from an extensive search of medical literature focused on clinical signs. We reviewed all cases of pediatric BBE in the literature to determine if any patient showed features suggestive for BBE/GBS. This analysis has the primary objective to identify the pediatric phenotype of BBE in order not to risk not diagnosing the overlapping form.

## 2. Material and methods

A literature review was performed on three electronic medical databases (PubMed, Cochrane Library and Scopus Web of Science) by three authors (G.M., C.O., S.S.), evaluating cases published in the period until June 2020. In the search bar, we first introduced the MeSH term “Bickerstaff” and “pediatric”, and several 43 manuscripts were collected. Adding the term “clinical symptoms”, we identify 20 articles. We select articles by excluding systematic reviews involving a similar topic and choosing those in which the term “Bickerstaff” was included in the title of the article’s main content. We also excluded articles in which adults were enrolled, studies without accessible data, or a full-text available. Finally, we excluded duplicate studies. English articles were chosen, so obtaining a total of 14 items and 40 cases. A descriptive summary was performed. It was not possible to perform a meta-analysis and statistical analysis due to the different nature of the studies and the lack of controlled studies. We follow the rules of the Declaration of Helsinki, and the board approved our AOU Policlinico—San Marco, Catania (Ct 138843). We also followed the Prisma flow diagram of the literature selection and review process. Fig. 1 is a flow chart of the reviewed literature.

## 3. Results

We considered 40 cases of pediatric BBE, analyzing the clinical symptoms and signs of the disease. The median of patients was 8 years; the youngest patient was 7 months [13]; the oldest was 18 years [14]. Sex was specified in all cases, of which 30 were male, and 10 were female (3:1 male to female ratio). 22 patients reported an acute (main duration 3.05 days ranging from 2 to 8 days), self-solving, illness preceding the onset of neurologic symptoms; in the others 18 cases, previous symptoms are not reported. Of these 22 patients, 8 reported an upper respiratory tract infection (URI), 6 reported gastroenteritis with diarrhea and emesis (in some cases, the culture was positive for *Campylobacter jejuni*), 4 patients had pneumonia (two with mycoplasma infection); 3 experienced a flu-like illness, and one patient had suffered

from acute bronchitis and enteritis three weeks before admission and had laboratory evidence of recent infection with Epstein-Barr virus (EBV). In most cases, these symptoms had occurred a week earlier and had resolved before presentation, in addition to the characteristic triad of altered status, ophthalmoplegia, and ataxia (Fig. 2). The most commonly reported finding was altered reflexes with 24 cases of hyperreflexia (60%), 8 cases of areflexia (20%) and 7 cases of hyporeflexia (18%), only in 1 case deep tendon reflexes remained normal (2%) [15]. Babinski reflex was present in 5 patients. Visual deficit including diplopia, esotropia, decreasing of visual acuity were reported in 65% of cases (in one case was reported anisocoria [16]). In one case, the patient had a reoccurrence of diplopia one month after his presentation [15]. Facial/bulbar weakness was reported in 16 cases (40%), limbs weakness in 14 cases (35%), no apparent weakness in 7 patients (17%), global weakness in 3 patients (8%). Neuropathy or paresthesias in 3 patients (8%) (in one case with complete loss of sensation in lower extremities) [14]. 5 patients developed dyspnea (13%); intubation for mechanical ventilation was required in 3 patients (8%). In one of these cases, although the mechanical ventilation and the intensive care, BBE was recurrent with the fulminant course, and the patient expired due to cardiac failure [17]. In one case, the patient was polyuric, which was later attributed to concomitant central diabetes insipidus [17].

There are cases with overlapping BBE/GBS—BBE/MFS. In the first [13], the patient had disturbance of consciousness, ataxia and ophthalmoplegia followed by a rapidly ascending paralysis of all four limbs. In addition, he developed respiratory failure requiring mechanical ventilation. In another [18], a 14-year-old girl developed diplopia and ataxic gait with impaired consciousness and tetraplegia. Several other case reports, where the authors described the case of a 4-year-old child with Miller Fisher Syndrome: ophthalmoplegia, ataxia and loss of tendon reflex, who had cerebral lesions evident on magnetic resonance imaging, suggesting a Miller-Bickerstaff spectrum [19–21]. The main differences between BBE, GBS and MFS are shown in Table 1.

Our group recently [22] published a review on all aspects of Bickerstaff’s brainstem encephalitis; here, we focus our attention on the clinical aspect of this disease.

## 4. Conclusions

In this review, we focus our attention on the clinical symptoms of Bickerstaff encephalitis. For us probably, these conditions have been under-diagnosed until now.

The BBE usually has a rapid and acute onset within 2–4 weeks, characterized by a typical picture of ophthalmoplegia and cerebellar symptoms such as ataxia. It usually begins with cranial nerve involvement progressing to various consciousness alterations, in some rare cases leading to coma [23]. Ocular disturbances start with diplopia and progressive ophthalmoplegia, usually symmetric, followed by gait disturbance within 4 weeks from the previous infection. However,

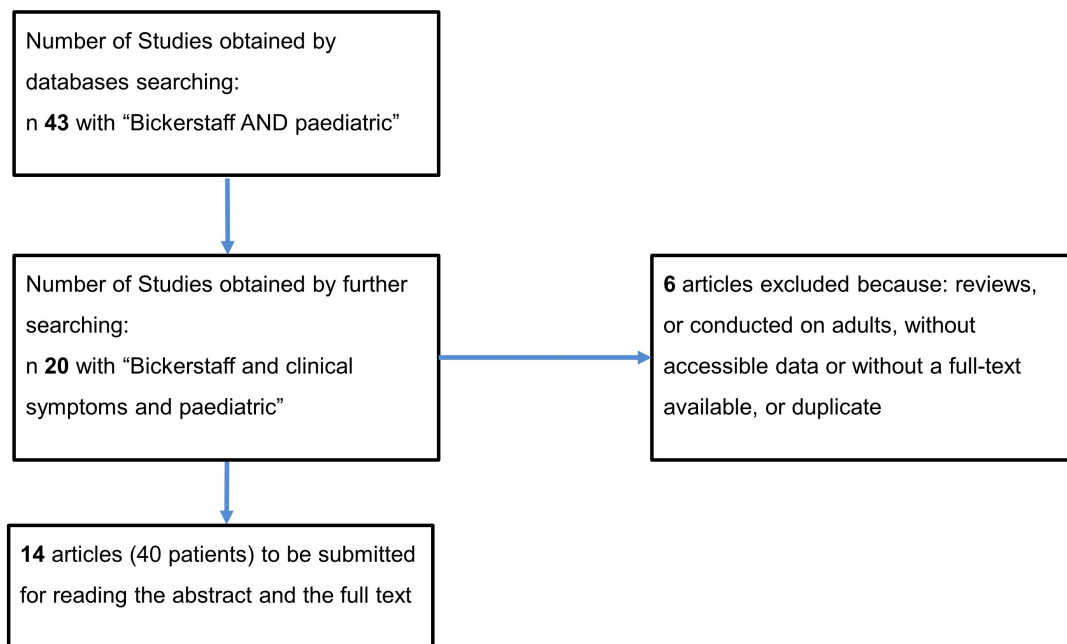


Fig. 1. Flow diagram of literature selection and review process.

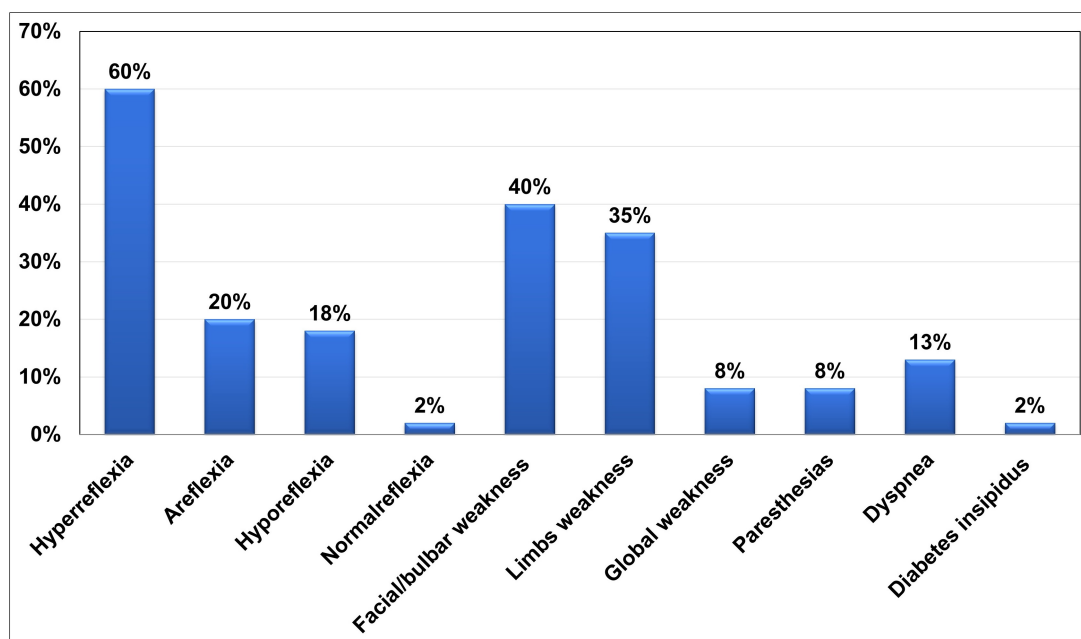


Fig. 2. Clinical symptoms and signs in addition to the characteristic triad (altered status, ophthalmoplegia and ataxia).

ophthalmoplegia is familiar to BBE and MFS [24]. The subsequent manifestations of hyperreflexia or consciousness disturbances as drowsiness, sleepiness, or coma are more suggestive for central involvement, leading to a more probable clinical diagnosis of BBE. Several other symptoms or signs are commonly but not constantly reported, in common with GBS as weakness of the limbs (till to real flaccid symmetrical tetraparesis), superficial or deep sensory disturbances, facial weakness or palsy and oculomotor impairment as blepharoptosis,

internal ophthalmoplegia, bulbar palsy, nystagmus, mydriasis or abnormalities of pupils. Other disorders recently associated with this condition are psychosis disturbances [25]. Nagamine and colleagues described a patient with atypical Bickerstaff brainstem encephalitis and psychosis [25]. Wada *et al.* [26] described two patients with BBE and delirium.

Although precise pathophysiology is unclear, BBE is associated with anti-GQ1b antibodies, indicative of autoimmune encephalitis, one of the most common causes of non-

**Table 1. Main differences between BBE, GBS and MFS.**

	BBE	MSF	GBS
Featured characteristics	Ophthalmoplegia	Ophthalmoplegia	Acute ascending symmetrical limb
	Ataxia	Ataxia	Areflexia
	Areflexia/Hyperreflexia	Areflexia	Symmetrical weakness
	Impaired consciousness	Symmetrical weakness	Dysautonomia
Laboratory finding	Anti GQ1b antibody in serum*	Anti GQ1b Antibody in serum*	Anti GQ1b Antibody in serum*
	CSF pleocytosis	CSF pleocytosis	CSF pleocytosis
	CSF Albumino-cytological dissociation	CSF Albumino-cytological dissociation	CSF Albumino-cytological dissociation
MRI findings	High T2 signal with little if any enhancement in the brainstem and basal ganglia	Typically, MRI Brain findings are unremarkable given the peripheral predilection	Anterior nerve root thickening and enhancement surrounding the medullary cone extending along the cauda equine
Supportive evidence	EEG: abnormal slow-wave activity		EMG: demyelination or axonal damage in peripheral nerves and spinal roots

infectious encephalitis. There are various clinical manifestations among autoimmune encephalitis patients, including behavioral and psychiatric symptoms, autonomic disturbances, movement disorders, and seizures [27]. In addition, some patients may present psychotic symptoms before neurological features, resulting in the first visit to a psychiatric hospital. Among BBE patients, however, psychosis is a rare condition.

Recovery in pediatric age is faster than in adulthood, resolving in most cases within 2 months depending on the severity of the clinical symptoms presented. However, BBE may be a “random” disease with so far little data on disease incidence.

### Author contributions

PP, RF and GM conceived and designed the manuscript; MGP and PS performed the data search; FG, SS and AS analyzed the data; AF and CFO contributed reagents and materials; PP and RF wrote the paper; GM, SS, AF, FG, CFO, MGP, AS, PS, PP and RF prepare the final draft and the revision of the paper.

### Ethics approval and consent to participate

The institutional review board of the AOU Policlinico—San Marco, Catania approved 15-02-2016, code Ct 138843.

### Acknowledgment

The authors would like to thank AME for the English language review. Certificate Verification Key: 744-574-569-832-441.

### Funding

This research received no external funding.

### Conflict of interest

The authors declare no conflict of interest.

### References

- [1] Koga M, Kusunoki S, Kaida K, Uehara R, Nakamura Y, Kohriyama T, *et al.* Nationwide survey of patients in Japan with Bickerstaff brainstem encephalitis: epidemiological and clinical characteristics. *Journal of Neurology, Neurosurgery & Psychiatry.* 2012; 83: 1210–1215.
- [2] Hughes RAC, Cornblath DR. Guillain-Barré syndrome. *Lancet.* 2005; 366: 1653–1666.
- [3] Gologorsky RC, Barakos JA, Sahebkar F. Rhomb- and Bickerstaff encephalitis: two clinical phenotypes? *Pediatric Neurology.* 2013; 48: 244–248.
- [4] Steer AC, Starr M, Kornberg AJ. Bickerstaff brainstem encephalitis associated with Mycoplasma pneumonia infection. *Journal of Child Neurology.* 2006; 21: 533–534.
- [5] Bickerstaff ER, Cloake PCP. Mesencephalitis and Rhombencephalitis. *British Medical Journal.* 1951; 2: 77–81.
- [6] Ito M, Kuwabara S, Odaka M, Misawa S, Koga M, Hirata K, *et al.* Bickerstaff's brainstem encephalitis and Fisher syndrome form a continuous spectrum: clinical analysis of 581 cases. *Journal of Neurology.* 2008; 255: 674–682.
- [7] Yuki N. Fisher syndrome and Bickerstaff brainstem encephalitis (Fisher–Bickerstaff syndrome). *Journal of Neuroimmunology.* 2009; 215: 1–9.
- [8] Odaka M, Yuki N, Yamada M, Koga M, Takemi T, Hirata K, *et al.* Bickerstaff's brainstem encephalitis: clinical features of 62 cases and a subgroup associated with Guillain-Barré syndrome. *Brain.* 2003; 126: 2279–2290.
- [9] Pavone P, Le Pira A, Greco F, Vitaliti G, Smilari PL, Parano E, *et al.* Bickerstaff's brainstem encephalitis (BBE) in childhood: rapid resolution after intravenous immunoglobulins treatment. *European Review for Medical and Pharmacological Sciences.* 2014; 18: 2496–2499.
- [10] Sugiyama N, Hamano S, Koga M. High-dose intravenous immunoglobulin therapy in a child case of Bickerstaff's brainstem encephalitis. *Brain and Development.* 2003; 35: 327–330. (In Japanese)
- [11] Kikuchi M, Tagawa Y, Iwamoto H, Hoshino H, Yuki N. Bickerstaff's brainstem encephalitis associated with IgG anti-GQ1b antibody subsequent to Mycoplasma pneumonia infection: favorable response to immunoadsorption therapy. *Journal of Child Neurology.* 1997; 12: 403–405.
- [12] Ding Y, Yu L, Zhou S, Zhang L. Clinical characteristic analysis of seven children with Bickerstaff brainstem encephalitis in China. *Frontiers in Neurology.* 2020; 11: 557.
- [13] Fong CY, Aung HWW, Khairani A, Gan CS, Shahrizaila N, Goh KJ. Bickerstaff's brainstem encephalitis with overlapping Guillain-Barré syndrome: usefulness of sequential nerve conduction studies. *Brain and Development.* 2018; 40: 507–511.
- [14] Santoro JD. Long-term sequelae of pediatric Bickerstaff brainstem encephalitis includes autonomic and sleep dysregulation. *Journal of Child Neurology.* 2019; 34: 153–160.

- [15] McLeod SA, Wee W, Jacob FD, Chapados I, Bolduc FV. Recurrent diplopia in a pediatric patient with Bickerstaff brainstem encephalitis. *Case Reports in Neurological Medicine*. 2016; 2016: 5240274.
- [16] Matsuo M, Odaka M, Koga M, Tsuchiya K, Hamasaki Y, Yuki N. Bickerstaff's brainstem encephalitis associated with IgM antibodies to GM1b and GalNAc-GD1a. *Journal of the Neurological Sciences*. 2004; 217: 225–228.
- [17] Chamsi Basha A, Kolko N, Santoro JD, Alomani H. A probable case of recurrent Bickerstaff brainstem encephalitis with fulminant course in a pediatric patient. *Neurologist*. 2020; 25: 14–16.
- [18] Kitazawa K, Yuki N. Guillain-Barré syndrome associated with external ophthalmoplegia, consciousness disturbance, and extensor plantar responses: an overlap between Guillain-Barré syndrome and Bickerstaff's brainstem encephalitis. *Clinical Neurology*. 1995; 35: 626–632. (In Japanese)
- [19] Tsapis M, Laugel V, Koob M, de Saint Martin A, Fischbach M. A pediatric case of Fisher-Bickerstaff spectrum. *Pediatric Neurology*. 2010; 42: 147–150.
- [20] Shahrizaila N, Yuki N. Bickerstaff brainstem encephalitis and Fisher syndrome: anti-GQ1b antibody syndrome. *Journal of Neurology, Neurosurgery & Psychiatry*. 2013; 84: 576–583.
- [21] Matsumoto H, Kobayashi O, Tamura K, Ohkawa T, Sekine I. Miller Fisher syndrome with transient coma: comparison with Bickerstaff brainstem encephalitis. *Brain & Development*. 2002; 24: 98–101.
- [22] Marino S, Marino L, Greco F, Venti V, Fontana A, Timpanaro T, *et al.* Bickerstaff's brainstem encephalitis in childhood: a literature overview. *European Review for Medical and Pharmacological Sciences*. 2020; 24: 12802–12807.
- [23] Bickerstaff ER. Brain-stem encephalitis: further observations on a grave syndrome with benign prognosis. *British Medical Journal*. 1957; 1: 1384–1387.
- [24] Mori M, Kuwabara S, Fukutake T, Yuki N, Hattori T. Clinical features and prognosis of Miller Fisher syndrome. *Neurology*. 2001; 56: 1104–1106.
- [25] Nagamine T. Acute psychosis secondary to atypical Bickerstaff brainstem encephalitis. *Asian Journal of Psychiatry*. 2019; 46: 49–50.
- [26] Wada Y, Yanagihara C, Nishimura Y, Funakoshi K, Odaka M. Delirium in two patients with Bickerstaff's brainstem encephalitis. *Journal of the Neurological Sciences*. 2008; 269: 184–186.
- [27] Hao Q, Wang D, Guo L, Zhang B. Clinical characterization of autoimmune encephalitis and psychosis. *Comprehensive Psychiatry*. 2017; 74: 9–14.