

Original Research

Abnormal fractional amplitude of low-frequency fluctuations in MOG-IgG optic neuritis patients: a resting-state functional MRI study

Hong-Wu Yang^{1,2,†}, Qian-Hui Xu^{2,†}, Qiu-Yu Li², Li-Juan Zhang², Hui-Ye Shu²,
Rong-Bin Liang², Yi-Cong Pan², Yi Shao^{2,*}

¹Department of Neurology, The Fourth Affiliated Hospital of Nanchang University, 330006 Nanchang, Jiangxi, China

²Department of Ophthalmology and Geriatric Medicine, The First Affiliated Hospital of Nanchang University, Jiangxi Center of Natural Ocular Disease Clinical Research Center, 330006 Nanchang, Jiangxi, China

*Correspondence: freebee99@163.com (Yi Shao)

†These authors contributed equally.

Academic Editor: Soh Hidaka

Submitted: 15 March 2021 Revised: 31 March 2021 Accepted: 28 May 2021 Published: 23 March 2022

Abstract

Optic neuritis (ON) is a general term for inflammation of any part of the optic nerve resulting from demyelination or infection. The number of patients with MOG-IgG antibody-related optic neuritis is increasing recently. Our study uses the fractional amplitude of low-frequency fluctuation (fALFF) method to compare the activity of specific brain regions in MOG-IgG ON patients and healthy controls (HCs). We selected a total of 21 MOG-IgG ON patients and 21 HCs were included in the study. All subjects underwent resting-state functional magnetic resonance imaging (rs-fMRI). The independent-samples *t*-test was used to compare demographic data and average fALFF values between groups. The specificity and sensitivity of fALFF values for distinguishing between MOG-IgG ON patients and HCs were evaluated by receiver operating characteristic (ROC) curve analysis. Pearson's correlation analysis was used to analyze the relationship between fALFF values and clinical characteristics in MOG-IgG ON patients. Our results showed that fALFF values of the right cerebellum and left middle cingulum were lower whereas those of bilateral inferior temporal lobes, right gyrus rectus, and the left superior and right middle frontal lobes of MOG-IgG ON patients were higher than those of HCs ($P < 0.05$). The average fALFF value of the left superior frontal lobe in MOG-IgG ON patients was positively correlated with Hospital Anxiety and Depression Scale score (HADS) ($r = 0.6004$; $P < 0.05$) and duration of MOG-IgG ON ($r = 0.6487$; $P < 0.05$). Thus, patients with MOG-IgG ON have abnormal activity in the brain regions related to vision. Changes in fALFF value can reflect functional sequelae of MOG-IgG ON, including abnormal anxiety or depressive emotional changes.


Keywords: MOG-IgG; Optic neuritis; Fractional amplitude of low-frequency fluctuation; Brain regions; Clinical diagnosis

1. Introduction

Optic neuritis (ON) is a general term for inflammation of any part of the optic nerve resulting from demyelination or infection and causes visual impairment in young and middle-aged patients, affecting 115 out of every 100,000 individuals [1]. ON can be classified as papillitis with optic disc edema or retrobulbar ON without optic disc edema according to the affected location, and can be further categorized as idiopathic demyelinating ON—which is closely related to multiple sclerosis—or inflammatory or infectious ON. The most common optic neuritis is idiopathic optic neuritis, which is divided into (1) idiopathic demyelinating optic neuritis (IDON); (2) neuromyelitis optica related optic neuritis (NMO-ON); (3) other central optic neuritis associated with demyelinating diseases of the nervous system. The optic nerve leads to signal transmission barriers and affects vision under certain circumstances [2,3], and can cause other complications related to brain activity [4]. For example, autistic patients with chronic ON exhibit nerve atrophy [5] and impairments in vision and cerebellar function [6] that suggest damage to specific brain areas. Recently,

it was discovered that myelin oligodendrocyte glycoprotein (MOG) antibody was positive in the serum of AQP-4 antibody-negative ON patients. Therefore, we selected MOG-IgG positive ON patients for research to explore the changes in brain activity and possible abnormal pathological manifestations.

Functional magnetic resonance imaging (fMRI) is used to investigate brain activity and metabolism [6] and is commonly employed for the diagnosis of ON. fMRI can provide information on brain function in blind patients [7] such as changes in activity in the visual cortex [8]. Resting-state (rs)-fMRI measures spontaneous fluctuations in BOLD-fMRI signal intensity (measured as fractional amplitude of low-frequency fluctuation (fALFF) corresponding to neural activity, which can reveal changes in the functional connectivity of the brain in disease states [9–12]. Analysis with the fALFF method excludes nonspecific signals in rs-fMRI for increased detection sensitivity and specificity [13,14] and has been applied to the investigation of neurologic disorders [15,16] as well as ophthalmic diseases such as Monocular Blindness [17], glaucoma [18],



diabetic retinopathy [19]. However, the effect of ON on neural activity in specific brain regions is not fully known. As fMRI can reflect the functional status of the visual cortex and visual pathway in real time, we used fALFF method to evaluate changes in brain area associated with ON. Patients with MOG-IgG ON often have a series of central nervous system diseases in the later stages of the disease. Therefore, we believe that this may also be one of the reasons for the abnormal activity of the brain, and the changes in the function of different brain regions can cause visual defects other than visual impairment. Various complications, such as the aforementioned anxiety and depression, and changes in cognitive function. Because the course of MOG-IgG ON develops rapidly, the prevention of complications and sequelae after clinical diagnosis is also very necessary. Combined with fALFF imaging examination, abnormal activities in the brain area of the patient can be effectively found, which contributes to the next diagnosis and treatment.

2. Materials and methods

2.1 Subjects

From the Department of Ophthalmology, the First Affiliated Hospital of Nanchang University, 21 patients with MOG-IgG ON were included, including 8 males and 13 females. All subjects met the following criteria: (1) with or without acute vision loss; (2) nervous-related visual impairment; (3) patients with abnormal pupil conduction or abnormal visual evoked potential; (4) no retinal disease; (5) no treatment with any drugs before resting-state functional MRI scanning; and (6) no obvious abnormality in the brain parenchyma on head MRI; (7) no drug, alcohol, or tobacco addictions; (8) no organ transplantation; (9) all patients were positive serum MOG-IgG ON; (10) exclude other types of optic neuropathy, such as compression, infiltration, trauma, toxic and nutritional metabolism, hereditary optic neuropathy; and (11) exclude optic neuritis caused by autoimmune diseases, such as systemic lupus erythematosus.

We also recruited 21 healthy controls (HCs) including 8 men and 13 women. The inclusion criteria for NCs were as follows: (1) normal brain function; (2) no disease that affects vision (VA) >1.0; (3) no neuropsychiatric disease; (4) ability to go through an MRI scan.

All subjects (or their guardians for subjects under the age of 18 years) provided written, informed consent before participation in the study. The study was approved by the Research Ethics Committee of the First Affiliated Hospital of Nanchang University (CDYFY-LL-2015-29), and the research protocol was in compliance with the Declaration of Helsinki.

2.2 MRI parameters

MRI scanning was performed using a 3-Tesla MR scanner (Trio; Siemens, Munich, Germany). All subjects' eyes are closed obtaining fMRI data. Functional data were

obtained using a 3-dimensional metamorphic gradient echo pulse sequence. The scanning parameters were as follows: repetition time = 2000 ms, echo time = 40 ms, flip angle = 90°, slice thickness/gap = 4.0/1 mm, field of view = 240 × 240 mm, and plane resolution = 64 × 64 pixels. A total of 30 axial slices covering the brain were recorded and 240 functional images were obtained for each subject.

2.3 fMRI data analysis

We used MRIcro software (REST; <http://www.MRIcro.com>) to classify functional data and remove incomplete data. SPM8 software (<http://www.fil.ion.ucl.ac.uk/spm/>) was used to preprocess the fMRI image according to the following steps. The first 10 time points were discarded to obtain a steady signal, and slice timing and correction of head motion (≤ 2 mm, with rotation $\leq 1.5^\circ$) were performed. The data were spatially homogenized into the standard Montreal Neurological Institute echo-planar imaging template and re-sampled into a 3 × 3 × 3-mm cube. Covariates used for regression analysis included 6 head motion parameters, average frame displacement, overall brain signal, and average white matter and cerebrospinal fluid signals. The passivation trend was eliminated and filtered (0.01–0.08 Hz).

2.4 fALFF analysis

fALFF values were calculated based on data trends using REST software (<https://www.nitrc.org/projects/rest/>); fALFF values were obtained as the ratio of each frequency in the low-frequency range (0.01–0.08 Hz) to the power in the entire frequency range (0–0.25 Hz). Bandpass filtering at 0.01–0.08 Hz was performed to eliminate the influence of low-frequency drift and high-frequency physiologic noise.

2.5 Statistical analysis

Data were analyzed using SPSS v21.0 software (IBM, Armonk, NY, USA). Differences in clinical characteristics between groups were evaluated with the independent-samples *t*-test. Receiver operating characteristic (ROC) curve analysis was carried out in order to assess the clinical utility of fALFF values in distinguishing between MOG-IgG ON patients and HCs.

3. Results

3.1 Demographic and clinical characteristics data

No statistically significant differences between MOG-IgG ON patients and HC subjects in terms of weight, height, body mass index, age, and handedness (Table 1). The mean duration of ON was 4.67 ± 3.26 days. Best-corrected visual acuity of both right and left eyes was significantly lower in ON patients than in HC subjects ($P < 0.001$). The retinal nerve fiber layer thickness (RNFLT) of MOG-IgG ON patients were obviously thinner than HCs ($P < 0.05$) (Table 1). Ophthalmoscopy and the fluorescein fundus angiography indicated clinical manifestations of optic neuritis (Fig. 1).

Table 1. Clinical characteristics of patients between ON and HC groups.

Characteristics	ON	HCS	T-value	P-values
Male/female	8/13	8/13	NA	NA
Age (years)	44.83 ± 10.71	45.83 ± 11.38	-0.222	0.821
Weight (kg)	57.08 ± 7.30	58.85 ± 5.85	-0.463	0.652
Height (cm)	160.81 ± 9.31	161.38 ± 6.28	-0.485	0.634
The side of impaired eye (left/right/both)	2/3/16	NA	NA	NA
BMI (kg/m ²)	21.13 ± 1.62	21.17 ± 1.27	-0.056	0.963
Handedness (left/right)	1/20	0/21	0.348	0.736
Duration of ON (days)	4.67 ± 3.26	NA	NA	NA
Duration from onset of ON to rs-fMRI scan (days)	5.42 ± 2.94	NA	NA	NA
Treatment	Azathioprine	NA	NA	NA
Best-corrected VA, right	0.25 ± 0.32*	1.30 ± 0.31	-8.138	<0.001
Best-corrected VA, left	0.85 ± 0.52*	1.28 ± 0.32	-2.481	<0.001
RNFLT-right (μm)	102.98 ± 6.54*	128.52 ± 8.36	1.643	0.024
RNFLT-left (μm)	106.16 ± 7.61*	130.56 ± 8.55	1.154	0.031

Notes: Independent *t*-tests comparing the two groups (**P* < 0.05) represented statistically significant differences.

Abbreviation: ON, optic neuritis; HCs, healthy controls; NA, not applicable; BMI, body mass index; rs-fMRI, resting-state functional magnetic resonance; VA, visual acuity; RNFLT, retinal nerve fiber layer thickness.

Table 2. Brain areas with significantly different fALFF values between on and HCs groups.

Brain areas	MNI coordinates			BA	Peak voxels	T value
	X	Y	Z			
HC > ON						
Right Cerebellum	3	-60	-12		121	4.62
Cingulum_Mid_L	0	-9	33	24	170	4.67
HC < ON						
Temporal_Inf_L	-42	-24	-39	20	220	-4.65
Temporal_Inf_R	57	-18	-27	20	168	-4.58
Rectus_R	9	54	-15	11	175	-3.94
Frontal_Sup_L	-15	69	-9	10	116	-3.12
Frontal_Mid_R	30	36	12	10	102	-4.31

Abbreviation: ON, optic neuritis; HCs, healthy controls; fALFF, fractional amplitude of low-frequency fluctuation; Inf, Inferior; Sup, Superior; Mid, Middle; L, left; R, right.

3.2 Differences in fALFF between MOG-IgG ON patients and HCs

ON patients had higher fALFF values for bilateral inferior temporal lobes, right rectus, and left superior and right middle frontal lobes and lower fALFF values for the right cerebellum and left middle cingulum than HC subjects (Fig. 1 and Table 2). The average fALFF value was significantly lower in MOG-IgG ON patients than in HCs (*P* < 0.001) (Table 3).

3.3 ROC curve analysis

The utility of fALFF values of the abovementioned brain regions for distinguishing between MOG-IgG ON patients and HCs was evaluated by ROC curve analysis. The

Table 3. Two sample *t*-tests between mean fALFF values between ON patients and HCs related brain regions.

	ON	HCS	t	P
Right Cerebellum	-0.813	-0.186	4.622	<0.001
Cingulum_Mid_L	-0.025	1.020	4.668	<0.001
Temporal_Inf_L	-0.633	-1.150	-4.647	<0.001
Temporal_Inf_R	0.338	-0.398	-4.581	<0.001
Rectus_R	0.955	0.016	-3.948	<0.001
Frontal_Sup_L	-0.167	-0.765	-3.123	0.003
Frontal_Mid_R	-0.335	-0.901	-4.309	<0.001

Abbreviation: ON, optic neuritis; HCs, healthy controls; Inf, Inferior; Sup, Superior; Mid, Middle; L, left; R, right.

areas under the ROC curves (AUCs) were as follows: right cerebellum (0.175); left middle cingulum (0.152) (Fig. 2A); left inferior temporal lobe (0.859), right inferior temporal lobe (0.839), right rectus (0.814); left superior frontal lobe (0.766), and right middle frontal lobe (0.816) (Fig. 2B).

3.4 Correlation analysis

The fALFF value of the left superior frontal lobe of MOG-IgG ON patients was positively correlated with Hospital Anxiety and Depression Scale (HADS) score (*r* = 0.6004; *P* < 0.05) and time from the onset of ON to the rs-fMRI scan—i.e., ON duration (*r* = 0.6487; *P* < 0.05) (Fig. 3).

4. Discussion

ON is diagnosed based on medical history and clinical manifestations, which may not appear until the disease has progressed. Early diagnosis is critical for successful clinical

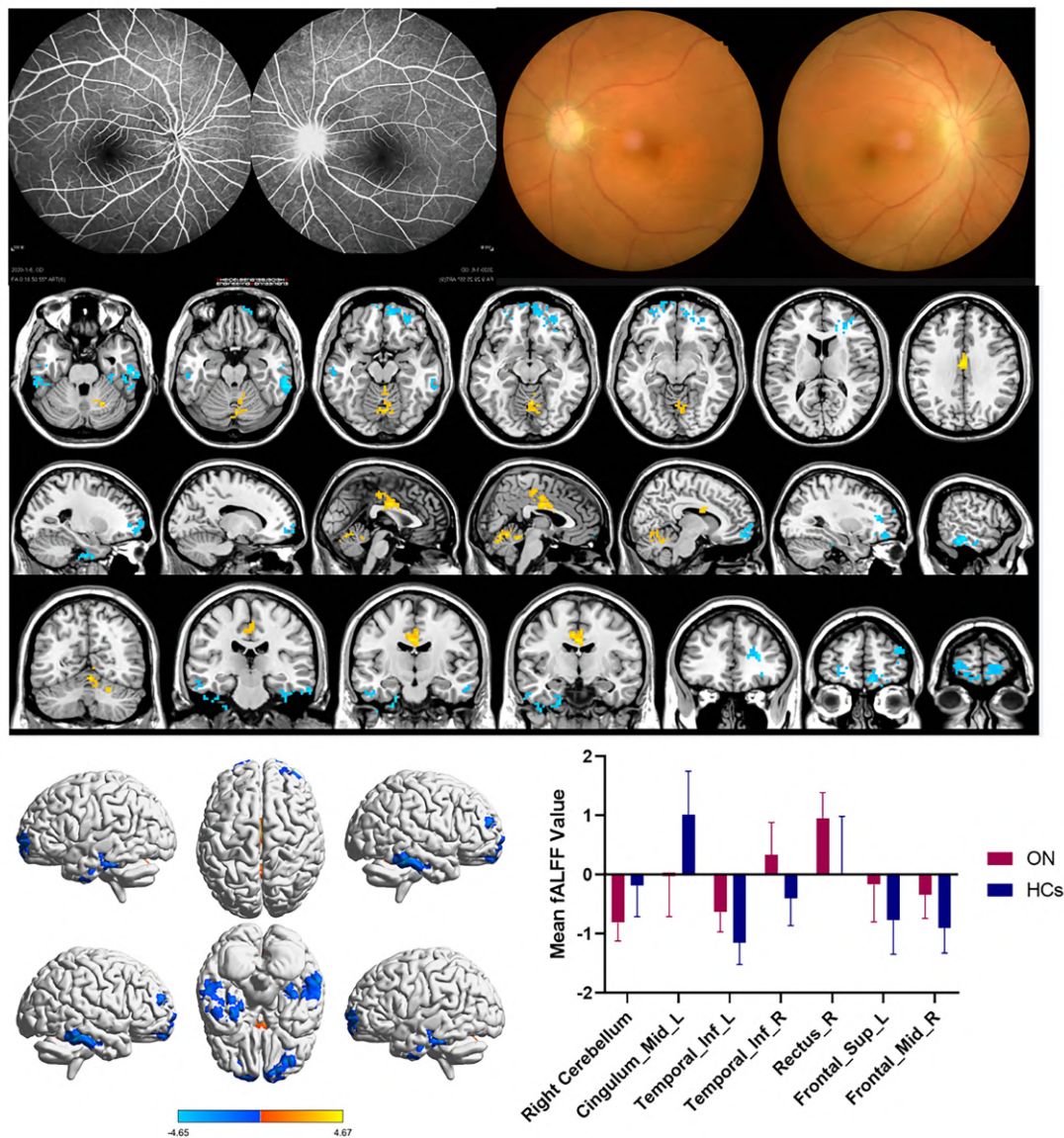


Fig. 1. Ophthalmoscopy and fluorescein fundus angiography of ON patients and spontaneous cerebral activity in ON patients and HCs. Notes: Significant brain activity differences were observed among ON patients. The red or yellow denotes increased fALFF values, and the blue areas indicate decreased fALFF values, respectively. Ophthalmoscopy and the fluorescein fundus angiography indicates clinical manifestations of typical optic neuritis. Abbreviation: ON, optic neuritis; HCs, healthy controls; fALFF, fractional amplitude of low-frequency fluctuation; Inf, Inferior; Sup, Superior; Mid, Middle; L, left; R, right.

cal outcome. fMRI can be used for early diagnosis of ON, and recent studies of ON have demonstrated abnormal activation in the insular cortex, temporal lobe, posterior parietal cortex, and thalamus [20–22]. In addition, it was found that patients with ON had abnormal brain activity [23]. ON-related demyelination and axonal damage in craniocerebral trauma can lead impaired brain function [24]. An increase in the ALFF value of the left parahippocampal gyrus may be related to ON severity [25]. Patients with recurrent ON show reduced activation of different brain areas, which is associated with visual information processing, suggesting that ON leads to brain dysfunction and potentially reflect-

ing the pathologic mechanism of ON.

Abnormal vision caused by ON, which can elicit compensatory activation in the contralateral brain area (Table 4). In addition, previous studies have confirmed the abnormal activation of brain regions in patients with ON [26]. Compared with IDON, which has mostly monocular attacks and recovers well, MOG-IgG ON is more disabling. The MOG antibody specifically binds to the MOG on the cell surface, resulting in a change in the configuration of MOG, so that oligodendrocytes lose their function of maintaining myelination and supporting neurons, forming MOG-mediated pathological changes. MOG antibody-related central ner-

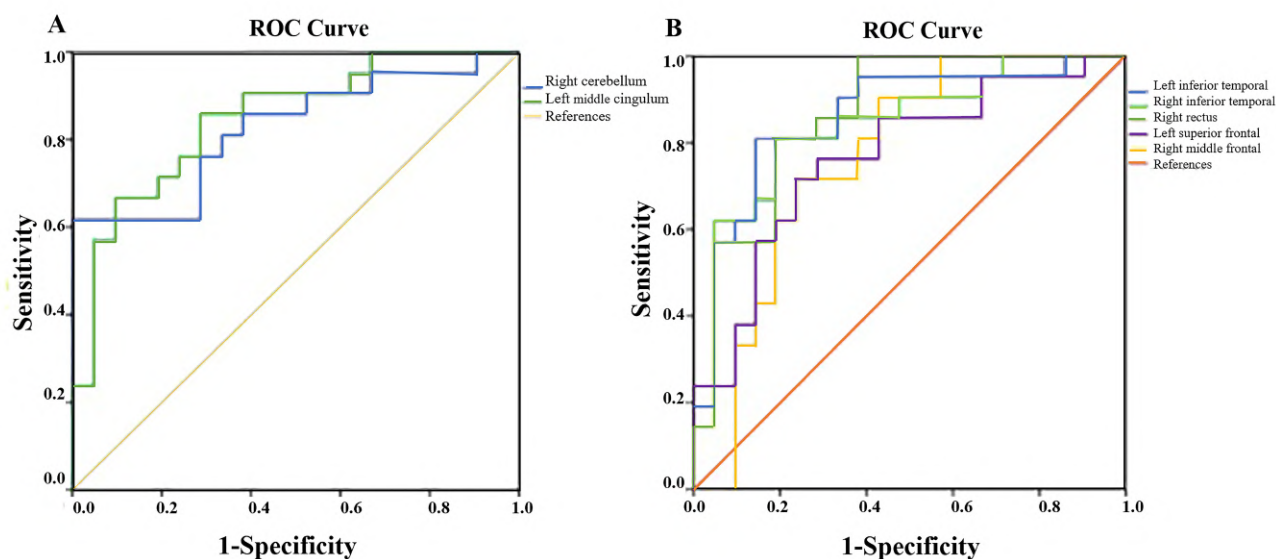


Fig. 2. ROC curve analysis of the mean fALFF values for changed areas. Notes: The AUCs of fALFF values were as follows: Right Cerebellum (0.875); Cingulum_Mid_L (0.852) (A); Temporal_Inf_L (0.859), Temporal_Inf_R (0.839), Rectus_R (0.814); Frontal_Sup_L (0.766) and Frontal_Mid_R (0.816) (B). Abbreviation: ON, optic neuritis; ROC, receiver operating characteristic; AUC, area under the curve; fALFF, fractional amplitude of low-frequency fluctuation; HCs, healthy controls; Inf, Inferior; Sup, Superior; L, left; R, right; Mid, Middle.

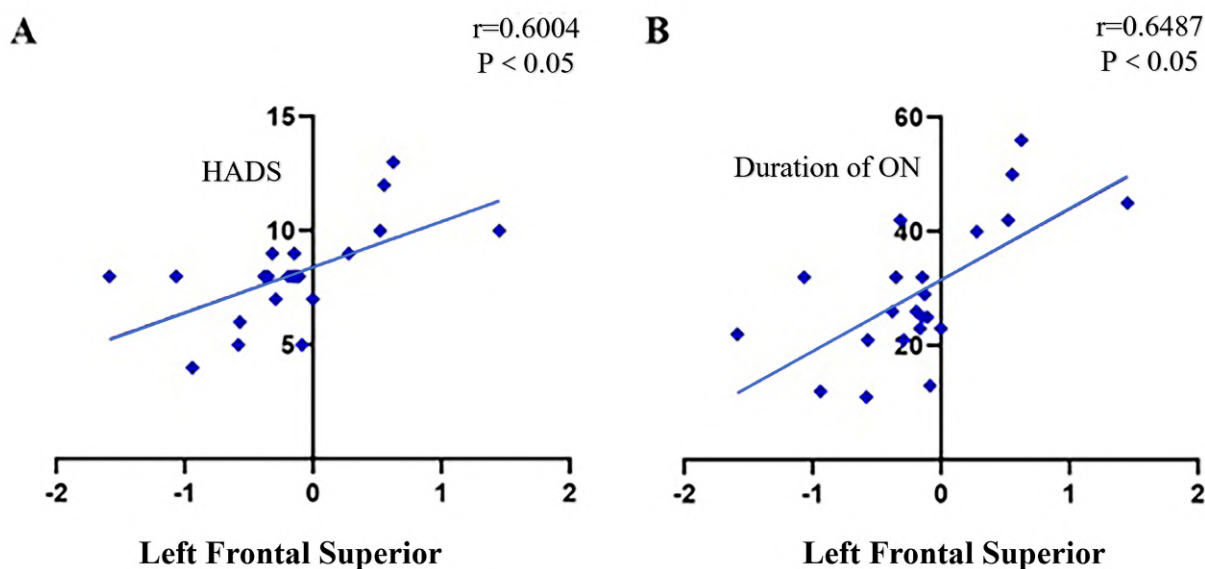


Fig. 3. Correlations between the mean fALFF signal values of the Left frontal superior and HADS and duration of ON in ON patients. Notes: The mean fALFF signal value of the Left frontal superior showed positively correlations with HADS ($r = 0.6004$, $P < 0.05$) (A). The mean fALFF signal value of the Left frontal superior showed positively correlations with duration of ON (days) (B). Abbreviation: ON, optic neuritis; HADS, Hospital Anxiety and Depression Scale.

vous system demyelinating disease clinical studies have found that bilateral simultaneous involvement of ON is the most common form of clinical onset. Patients with MOG-IgG ON present a different form of seizures than IDON,

with alternating eyes, repeated or simultaneous seizures in both eyes and severe visual impairment. Therefore, early clinical diagnosis and prevention are essential to reduce the occurrence of complications, which can rely on the appli-

Table 4. Brain regions alternation and its potential impact in ON patients.

Brain regions	Experimental results	Brain function	Anticipated results
Right Temporal Inferior	ONs > HCs	Associated with ocular diseases	Reflect intraocular inflammation and visual impairment
Left Temporal Inferior	ONs > HCs	Accept visual nerve information transmission	Visual system abnormalities
Right Rectus	ONs > HCs	Control oculomotor nerve movement	Affect eye movement
Left Frontal Superior	ONs > HCs	emotional and cognitive processing	Abnormal changes in mental activity
Right Frontal Mid	ONs > HCs	Sensory nerve impulse conduction	symptom in perception system
Right Cerebellum	ONs < HCs	Balance, muscle tone and voluntary movement	Unsteady gait
Left Cingulum Middle	ONs < HCs	Receive nerve impulse output from the amygdala, orbitofrontal gyrus and medial frontal gyrus	Depression symptoms

Abbreviation: ON, optic neuritis; HCs, healthy controls.

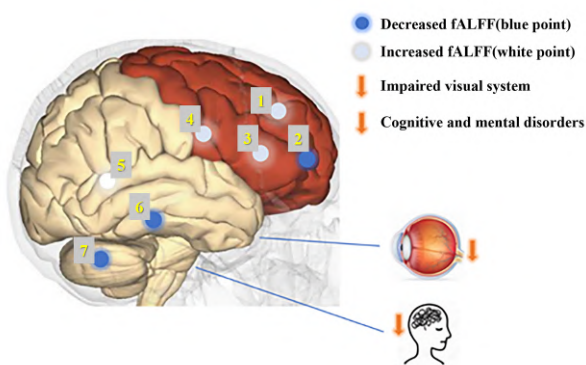


Fig. 4. The fALFF results of brain activity in the ON patients. Notes: Compared with the HCs, the fALFF of the following regions were increased to various extents: Temporal_Inf_L, Temporal_Inf_R, Rectus_R, Frontal_Sup_L and Frontal_Mid_R. and decreased fALFF values in the Right Cerebellum and Cingulum_Mid_L. Abbreviation: ON, optic neuritis; ROC, receiver operating characteristic; AUC, area under the curve; fALFF, fractional amplitude of low-frequency fluctuation; HCs, healthy controls; Inf, Inferior; Sup, Superior; L, left; R, right; Mid, Middle.

Table 5. fALFF method applied in other diseases.

Author	Year	Disease
Lai CH, <i>et al.</i> [28]	2015	Pure major depressive disorder
Wang JJ, <i>et al.</i> [29]	2016	Migraine
Fang JW, <i>et al.</i> [30]	2020	monocular blindness
Shu Y, <i>et al.</i> [31]	2020	Young depressed patients
Zhou F, <i>et al.</i> [32]	2020	diffuse axonal injury

ance of fALFF in the near future. We found that fALFF value in bilateral inferior temporal lobes, right rectus, and left superior and right middle frontal lobes were increased in MOG-IgG ON patients compared to HCs, indicating that visual information processing was affected. On the other hand, fALFF in the right cerebellum and were decreased in MOG-IgG ON patients compared to HCs. The ROC curve

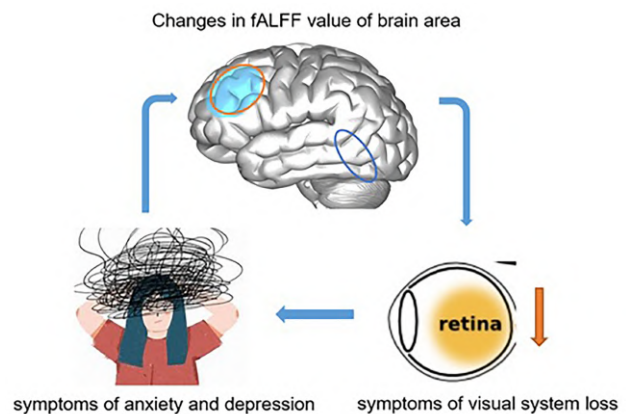


Fig. 5. Correlations between mean fALFF signal values and behavioral performance. Notes: The fALFF value of brain areas change in patients with ON indicates a series of symptoms of anxiety and depression, symptoms of perceptual system disease and loss of visual system.

analysis showed that the average fALFF value of these brain areas has moderate accuracy in distinguishing between the 2 groups, as demonstrated by AUC values ranging from 0.766 (left superior frontal lobe) to 0.875 (right cerebellum). The left middle cingulum is located above the sulcus of the corpus callosum on the inner side of the cerebral hemisphere below the cingulate groove. The output of the medial frontal gyrus to the anterior cingulate gyrus and striatum constitutes the emotional circuit that is involved in self-evaluation. In our study we found that the fALFF value of the left superior frontal lobe of MOG-IgG ON patients was positively correlated with HADS score, highlighting the functional consequences of MOG-IgG ON. The difference in fALFF value of the right cerebellum between MOG-IgG ON patients and HCs suggests abnormalities in the processing of nerve impulses from head proprioceptors and external receptors, but recent studies have also showed that there is a link between cerebellar disorders and depression [27]. Thus, changes in fALFF in specific brain regions associated with MOG-IgG ON can not only cause visual im-

pairment, but can also have behavioral consequences such as anxiety and depression (Fig. 4). Fig. 5 is a model that summarizes the effects of MOG-IgG ON on the value of fALFF in specific brain regions. MOG-IgG ON is a type of immune-mediated central nervous system inflammatory demyelinating disease. The effect of the disease on the brain regions of patients during the progression of the disease cannot be ignored. In other diseases, fALFF method was also used to have further results (Table 5, Ref. [28–32]). We use the method of fALFF to study the brain activity of patients with MOG-IgG ON Change, so as to achieve early detection of related complications and sequelae brain area abnormal fALFF signal prompts, to achieve timely detection and treatment, which is essential to improve quality of patients' daily life.

5. Conclusions

Results of our study demonstrate that MOG-IgG ON is associated with alterations in fALFFs in brain areas related to vision, perception, and emotion. Although the detailed neuropathologic mechanisms remain to be determined and optic neuritis may be caused by various pathological conditions, but we performed fMRI and fALFF analysis on patients with MOG-IgG ON and compared the results with HCs and found abnormal changes in brain activity, which inferred that patients with MOG-IgG ON may face complications and related sequelae because of the abnormal brain activities. Therefore, we believe that the value of fALFF can be considered as one of the auxiliary methods of clinical diagnosis, and can contribute to clinical prevention and early intervention.

Author contributions

HWY, QHX and YS designed the current study. QYL, LJZ and RBL collected data. YCP and HYS analyzed the data. QHX wrote the manuscript. All the authors read and approved the final manuscript.

Ethics approval and consent to participate

All research methods were approved by the committee of the medical ethics of the First Affiliated Hospital of Nanchang University (CDYFY-LL-2015-29) and were in accordance with the 1964 Helsinki declaration and its later amendments or comparable ethical standards. All subjects were explained the purpose, method, potential risks and signed an informed consent form.

Acknowledgment

Not applicable.

Funding

This study was supported by grants from the Key Research Foundation of Jiangxi Province (No: 20203BBG73059, 20181BBG70004); Excellent

Talents Development Project of Jiangxi Province (20192BCBL23020); Natural Science Foundation of Jiangxi Province (20181BAB205034); Grassroots Health Appropriate Technology “Spark Promotion Plan” Project of Jiangxi Province (No: 20188003); Health Development Planning Commission Science Foundation of Jiangxi Province (No: 20201032); Health Development Planning Commission Science TCM Foundation of Jiangxi Province (No: 2018A060).

Conflict of interest

The authors declare no conflict of interest.

References

- [1] Wilhelm H, Schabet M. The diagnosis and treatment of optic neuritis. *Deutsches Ärzteblatt international*. 2015; 112: 616–625.
- [2] Wei SH, Zhao Y. The role of myelin oligodendrocyte glycoprotein antibodies for detection of demyelinating optic neuritis. *Zhonghua Yan Ke Za Zhi*. 2017; 53: 874–877. (In Chinese)
- [3] Wicki CA, Manogaran P, Simic T, Hanson JVM, Schippling S. Bilateral retinal pathology following a first-ever clinical episode of autoimmune optic neuritis. *Neurology - Neuroimmunology Neuroinflammation*. 2020; 7: e671.
- [4] Shao Y, Cai F, Zhong Y, Huang X, Zhang Y, Hu P, *et al*. Altered intrinsic regional spontaneous brain activity in patients with optic neuritis: a resting-state functional magnetic resonance imaging study. *Neuropsychiatric Disease and Treatment*. 2015; 11: 3065–3073.
- [5] Cantó LN, Boscá SC, Vicente CA, Gil-Perontín S, Pérez-Miralles F, Villalba JC, *et al*. Brain atrophy in relapsing optic neuritis is associated with crion phenotype. *Frontiers in Neurology*. 2019; 10: 1157.
- [6] Chen JE, Glover GH. Functional Magnetic Resonance Imaging Methods. *Neuropsychology Review*. 2015; 25: 289–313.
- [7] Dormal G, Pelland M, Rezk M, Yakobov E, Lepore F, Collignon O. Functional Preference for Object Sounds and Voices in the Brain of Early Blind and Sighted Individuals. *Journal of Cognitive Neuroscience*. 2018; 30: 86–106.
- [8] Chan KC, Murphy MC, Bang JW, Sims J, Kashkoush J, Nau AC. Functional MRI of Sensory Substitution in the Blind. *Conference Proceedings - IEEE Engineering in Medicine and Biology Society*. 2018; 2018: 5519–5522.
- [9] Maknojia S, Churchill NW, Schweizer TA, Graham SJ. Resting State fMRI: Going through the Motions. *Frontiers in Neuroscience*. 2019; 13: 825.
- [10] Lee MH, Miller-Thomas MM, Benzinger TL, Marcus DS, Hacker CD, Leuthardt EC, *et al*. Clinical Resting-state fMRI in the Preoperative Setting: are we Ready for Prime Time? *Topics in Magnetic Resonance Imaging*. 2016; 25: 11–18.
- [11] Zou Q, Zhu C, Yang Y, Zuo X, Long X, Cao Q, *et al*. An improved approach to detection of amplitude of low-frequency fluctuation (ALFF) for resting-state fMRI: fractional ALFF. *Journal of Neuroscience Methods*. 2008; 172: 137–141.
- [12] Huang X, Zhong Y, Zeng X, Zhou F, Liu X, Hu P, *et al*. Disturbed spontaneous brain activity pattern in patients with primary angle-closure glaucoma using amplitude of low-frequency fluctuation: a fMRI study. *Neuropsychiatric Disease and Treatment*. 2015; 11: 1877–1883.
- [13] Krell D, Said Battistino F, Benafif S, Ganegoda L, Hall M, Rustin GJS. Audit of CA125 Follow-up after first-Line Therapy for Ovarian Cancer. *International Journal of Gynecological Cancer*. 2017; 27: 1118–1122.

- [14] Zou Q, Zhu C, Yang Y, Zuo X, Long X, Cao Q, *et al.* An improved approach to detection of amplitude of low-frequency fluctuation (ALFF) for resting-state fMRI: fractional ALFF. *Journal of Neuroscience Methods*. 2008; 172: 137–141.
- [15] Xiang J, Jia X, Li H, Qin J, Liang P, Li K. Altered Spontaneous Brain Activity in Cortical and Subcortical Regions in Parkinson's Disease. *Parkinson's Disease*. 2016; 2016: 5246021.
- [16] Turner JA, Damaraju E, van Erp TGM, Mathalon DH, Ford JM, Voyvodic J, *et al.* A multi-site resting state fMRI study on the amplitude of low frequency fluctuations in schizophrenia. *Frontiers in Neuroscience*. 2013; 7: 137.
- [17] Li Q, Huang X, Ye L, Wei R, Zhang Y, Zhong YL, *et al.* Altered spontaneous brain activity pattern in patients with late monocular blindness in middle-age using amplitude of low-frequency fluctuation: A resting-state functional MRI study. *Clinical Interventions in Aging*. 2016; 11: 1773–1780.
- [18] Liu Z, Tian J. Amplitude of low frequency fluctuation in primary open angle glaucoma: a resting state fMRI study. *Conference Proceedings - IEEE Engineering in Medicine and Biology Society*. 2014; 2014: 6706–6709.
- [19] Wang Z, Zou L, Lu Z, Xie X, Jia Z, Pan C, *et al.* Abnormal spontaneous brain activity in type 2 diabetic retinopathy revealed by amplitude of low-frequency fluctuations: a resting-state fMRI study. *Clinical Radiology*. 2017; 72: 340.e1–340.e7.
- [20] Steffen H, Tabibian D. Optic neuritis: Diagnosis, treatment and clinical implications. *Revue Médicale Suisse*. 2015; 11: 2388, 2390–2384. (In French)
- [21] Werring DJ, Bullmore ET, Toosy AT, Miller DH, Barker GJ, MacManus DG, *et al.* Recovery from optic neuritis is associated with a change in the distribution of cerebral response to visual stimulation: a functional magnetic resonance imaging study. *Journal of Neurology, Neurosurgery, and Psychiatry*. 2000; 68: 441–449.
- [22] Toosy AT, Werring DJ, Bullmore ET, Plant GT, Barker GJ, Miller DH, *et al.* Functional humans optic neuritis magnetic resonance imaging of the cortical response to photic stimulation in recovery following. *Neuroscience Letters*. 2002; 330: 255–259.
- [23] Audoin B, Fernando KTM, Swanton JK, Thompson AJ, Plant GT, Miller DH. Selective magnetization transfer ratio decrease in the visual cortex following optic neuritis. *Brain*. 2006; 129: 1031–1039.
- [24] De Vico Fallani F, Richiardi J, Chavez M, Achard S. Graph analysis of functional brain networks: practical issues in translational neuroscience. *Philosophical Transactions of the Royal Society of London. Series B, Biological Sciences*. 2014; 369: 20130521.
- [25] Zalesky A, Fornito A, Bullmore ET. Network-based statistic: identifying differences in brain networks. *NeuroImage*. 2010; 53: 1197–1207.
- [26] Toosy AT, Werring DJ, Bullmore ET, Plant GT, Barker GJ, Miller DH, *et al.* Functional magnetic resonance imaging of the cortical response to photic stimulation in humans following optic neuritis recovery. *Neuroscience Letters*. 2002; 330: 255–259.
- [27] Clausi S, Lupo M, Olivito G, Siciliano L, Contento MP, Aloise F, *et al.* Depression disorder in patients with cerebellar damage: Awareness of the mood state. *Journal of Affective Disorders*. 2019; 245: 386–393.
- [28] Lai C, Wu Y. The patterns of fractional amplitude of low-frequency fluctuations in depression patients: the dissociation between temporal regions and fronto-parietal regions. *Journal of Affective Disorders*. 2015; 175: 441–445.
- [29] Wang J, Chen X, Sah SK, Zeng C, Li Y, Li N, *et al.* Amplitude of low-frequency fluctuation (ALFF) and fractional ALFF in migraine patients: a resting-state functional MRI study. *Clinical Radiology*. 2016; 71: 558–564.
- [30] Fang JW, Yu YJ, Tang LY, Chen SY, Zhang MY, Sun T, *et al.* Abnormal Fractional Amplitude of Low-Frequency Fluctuation Changes in Patients with Monocular Blindness: A Functional Magnetic Resonance Imaging (MRI) Study. *Medical Science Monitor*. 2020; 26: e926224.
- [31] Shu Y, Kuang L, Huang Q, He L. Fractional amplitude of low-frequency fluctuation (fALFF) alterations in young depressed patients with suicide attempts after cognitive behavioral therapy and antidepressant medication cotherapy: a resting-state fMRI study. *Journal of Affective Disorders*. 2020; 276: 822–828.
- [32] Zhou F, Zhan J, Gong T, Xu W, Kuang H, Li J, *et al.* Characterizing Static and Dynamic Fractional Amplitude of Low-Frequency Fluctuation and its Prediction of Clinical Dysfunction in Patients with Diffuse Axonal Injury. *Academic Radiology*. 2020; 28: e63–e70.