

Original Research

Proposal of a Novel Procedure for C2-4 Cervical Spinal Cord Stimulator Implantation to Improve Complete Midline Coverage via Electrode Array in Patients with Disorders of Consciousness: A Retrospective Single-Center Study

Yuanyuan Dang^{1,2}, Xiaoyu Xia³, Yi Yang⁴, Ruijing Huang³, Jianghong He^{4,*},
Jianning Zhang^{1,2,*}¹Medical School of Chinese PLA, 100853 Beijing, China²Department of Neurosurgery, The First Medical Centre, Chinese PLA General Hospital, 100853 Beijing, China³Department of Neurosurgery, The Seventh Medical Centre, Chinese PLA General Hospital, 100700 Beijing, China⁴Department of Neurosurgery, Beijing Tiantan Hospital, Capital Medical University, 100070 Beijing, China*Correspondence: he_jianghong@sina.cn (Jianghong He); jnzhang_2022@163.com (Jianning Zhang)

Academic Editor: Sergio Bagnato

Submitted: 20 April 2022 Revised: 29 May 2022 Accepted: 31 May 2022 Published: 4 January 2023

Abstract

Background: Deviation of electrode array from the midline of spinal cords affects the therapeutic outcomes of C2-4 cervical spinal cord stimulation (SCS) in patients with disorders of consciousness (DOC). This study proposed the implementation of a novel C2-3 dural exposure procedure and investigated its efficacy compared to conventional surgery. **Methods:** Surgical and postoperative imaging data from 69 patients with DOC who underwent SCS in the lateral decubitus position were retrospectively assessed. The C2-3 dural exposure procedure was performed in 16 patients while the rest underwent conventional surgery. The incidence of electrode deviation was compared, and factors associated with the deviation were investigated. **Results:** The rate of complete midline coverage by the electrodes in the C2-3 dural exposure group was significantly higher than the conventional group (93.8% vs. 54.7%, $p = 0.004$). Exposure of the dura between C2-3 was a significant favorable factor for complete midline coverage by the electrode array (odds ratio [OR]: 0.091; 95% confidence interval [CI]: 0.011–0.757; $p = 0.027$). Electrode positioned ≥ 5 cm above the lower edge of the C2 vertebra was a significant risk factor for incomplete midline coverage (OR: 1.126; 95% CI: 1.016–1.248; $p = 0.023$). No difference in operation time, intraoperative bleeding, or surgical site infection was observed between the 2 groups. **Conclusions:** The C2-3 dural exposure procedure, performed in the lateral decubitus position, was safe and had higher complete midline coverage than conventional surgery.

Keywords: disorders of consciousness; spinal cord stimulation; C2-4; cervical spine; midline

1. Introduction

High cervical spinal cord stimulation (SCS) is used in the management of disorders of consciousness (DOC) [1–3], especially in patients in a minimally conscious state. It has been shown to have an important role in modulating the complexity of neural activities and promoting functional recovery [4,5]. Its target stimulus area is the dorsal columns of the C2-4 vertebrae. Traditionally, C5 laminectomy has been performed in the prone position to advance the electrode array cranially to the target zone, where a pulse generator is implanted in the lateral abdominal region [6]. However, one limitation of this procedure we observed in clinics is the challenge of ensuring that the electrode has completely covered the midline of the spine.

When high cervical stimulation is used in pain management, its most common indication, the clinical determination of the electrode position is accomplished under local anesthesia. However, intraoperative sensory tests cannot be performed in patients with DOC as they cannot effectively respond to stimuli. Thus, to increase the effectiveness of therapy, accurate implantation of electrodes at

predetermined locations is a prerequisite. However, literature on the technical aspects of cervical SCS implantation is scarce, and few studies have documented the accuracy of DOC-SCS implantation.

In this study, we report our findings on an improved paddle-type C2-4 spinal cord stimulator implantation technique in patients with DOC operated in the lateral decubitus position. A C2-3 dural exposure procedure was adopted to overcome the limitation of previous surgical methods, such as the inability to ensure complete midline coverage. Then, we compared the rate of complete midline coverage by the electrode array in patients with DOC who underwent conventional surgery with those who received the proposed C2-3 dural exposure procedure and further investigated the determinants of complete midline coverage by the electrode array.

2. Material and Methods

2.1 Patients

In this retrospective single-center study, the data of adult (≥ 18 years) patients with DOC who underwent spinal



cord stimulator implantation from April 2017 to April 2019 at the Seventh Medical Center of the PLA General Hospital (Beijing, China) were retrieved. A vegetative state (VS) or minimally conscious state (MCS) was diagnosed based on the JFK Coma Recovery Scale-Revised (CRS-R) [7]. Cases were excluded if they had: (1) brain damage within 3 months of study registration; (2) significant improvement or deterioration of consciousness within 4 weeks of study registration; (3) level of consciousness reaching emerged minimally conscious state (eMCS); (4) severe cervical spinal canal deformity, stenosis, or cervical spinal injury. All patients' surrogates provided informed consent for the treatments. The study protocol was approved by the Ethics Committee of the Seventh Medical Center of the PLA General Hospital (approval number: 2018-58). The data of all patients were anonymized, and no additional patient consent was required due to the retrospective nature of the study.

2.2 Surgical Technique

The surgeries were performed under general anesthesia and intubation by the same team of surgeons with more than six years of experience. For patients with cuffed tracheostomy cannula, the cannula was fixed on the neck with medical polyurethane and was used for interoperative care and ventilation. The pulse generator was placed in front of the pectoralis major fascia under the left or right clavicle. Sides with a ventriculoperitoneal shunt were avoided. The patients were then placed in the left or right decubitus position during the operation, with the pulse generator opposite to the side that was in contact with the table. The standard 90° lateral decubitus positioning was adopted to facilitate manipulation of both the nape of the neck and the chest wall, with the neck flexed without any axial rotation. For patients with cervical extensor spasms, their head was fixed with a Mayfield head holder. Under fluoroscopy, the C5 spinous process was marked using methylene blue. After the neck and chest regions were disinfected, a midline incision was made from the C3 to C5 spinous process. C5 laminotomy was performed as previously described [6]. In patients who underwent conventional surgery ($n = 53$), a 16-electrode array (Specify 2×8 ; Medtronic, Dublin, Ireland) was slid into the epidural space and advanced craniad to the C2-4 levels. In those who underwent the proposed C2-3 dural exposure procedure ($n = 16$), the dura between C2-3 was exposed, and the incisions were extended upwards to cover the C2-5 spinous processes. A small incision was made in the C2-3 interspinous ligament to expose the dura and confirm that the electrode array was correctly positioned in the midline. Any epidural resistance or adhesions were resolved by extending the laminectomy or gently separating the epidural space. Lastly, the pulse generator was implanted and connected to the electrode array using a subcutaneous device.

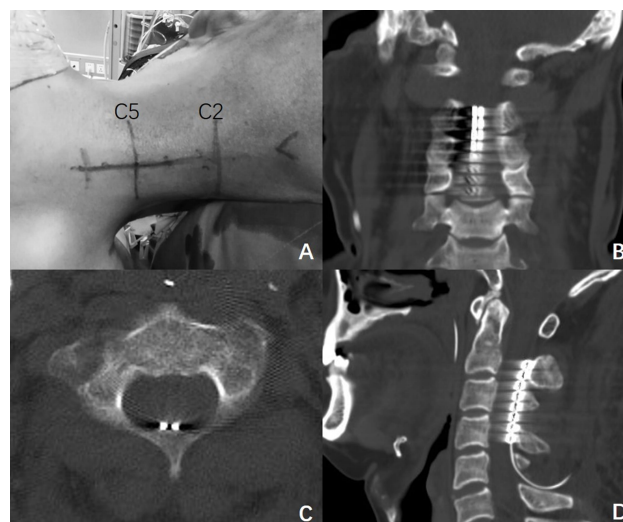


Fig. 1. Representative images of the surgical positioning and postoperative computed tomography (CT). (A) A patient in the right decubitus position, with incision markings at the C2-5 spinous processes. (B–D) Representative images of the electrode array in the coronal (B), horizontal (C) (at the most cephalic contact level), and sagittal (D) CT views.

2.3 Data Collection

The patients' medical records, imaging reports and surgical logs were obtained from the hospital's electronic records system. Data on age, sex, laterality of decubitus position, Glasgow Coma Scale score, CRS-R score, operative time and estimated blood loss were collected and analyzed. Operative time was calculated as the time from entering to leaving the operating room. The estimated blood loss was calculated by weighting the intraoperative surgical gauzes and measuring the volume of the suction fluid. Computed Tomography (CT) was performed using a 64-slice CT scanner (Discovery CT750 HD; GE Healthcare, Chicago, IL, USA) within 1 week after surgery. Three-dimensional (3D) CT reconstruction of the cervical spine was also performed. The sagittal diameter of the spinal canal at the lower edge of the C2 vertebra was measured on CT. Full coverage of the midline by the electrode array was defined as the area between the lateral sides of the two contacts at each level covering the dorsal midline of the spine, which was the primary study outcome. It was determined based on the axial scan of the cephalic-to-caudal contact pairs. The deviation direction was also recorded (Fig. 1). The height of the electrode was obtained by measuring the height of most cephalic contacts above the lower edge of C2.

Electromyography was used during device programming approximately two weeks after surgery in some studied patients ($n = 45$). Contact of interest (COI) was selected as a contact or contact pair on the midline at the cephalic level. The stimulus paradigm was set to a frequency of 70 Hz and a pulse width of 210 μ s. The voltage started at 0.5 volts and was stepped up to a maximum of 10 volts until

Table 1. Demographic and baseline characteristics of the eligible patients.

Characteristics	Conventional surgery (n = 53)	C2-3 dural exposure (n = 16)	t/χ^2	p
Male sex, n (%)	41 (77.4)	11 (68.9)	0.136	0.712
Age, years				
Mean \pm SD	42.6 \pm 12.7	46.7 \pm 15.4	1.086	0.282
Range	18–65	23–69		
Duration of DOC, months				
Median (range)	4.0 (3–41)	5.5 (3–156)		
DOC types, n (%)				
Vegetative state	41 (77.4)	12 (75.0)		
Minimally conscious state	12 (22.6)	4 (25.0)		
Etiologies, n (%)				
Traumatic	15 (28.3)	6 (38.5)		
Anoxic	16 (30.2)	0 (0)		
Vascular	22 (42.5)	10 (62.5)		

Abbreviations: DOC, disorders of consciousness.

EMG of deltoid or trapezius muscle was concurrently monitored. Lateralization was defined as the compound muscle action potential (CMAP) amplitudes at one side being at least double those of the other side.

Prognosis of consciousness was assessed in all the patients. The CRS-R score was recorded 1 month after surgery during hospitalization or doctor's home visits. The Extended Glasgow Outcome Scale (GOSE) score was recorded during follow-up via telephone or re-examination by an experienced neurologist 1 year after surgery.

2.4 Statistical Analysis

Statistical analyses were performed using the SPSS software (version 24.0; IBM, Armonk, NY, USA). The data were expressed as mean (\pm standard deviation [SD]) or median and range. Categorical variables were expressed as numbers (percentages) and analyzed using the chi-squared test or Fisher's exact test. The Student's t -test was used to analyze quantitative variables. Logistic regression was used to analyze risk factors for electrode array deviation. All statistical tests were two-sided. Statistical significance was set at $p \leq 0.05$.

3. Results

3.1 Patient Demographics and Baseline Characteristics

The study flowchart of patient data collection is shown in Fig. 2. Initially, the records of 98 patients diagnosed with DOC were screened. Of them, 76 patients underwent SCS. Four cases were excluded because other types of electrode arrays were used, or the patients were placed in a prone position. Two cases were excluded due to the lack of postoperative imaging. One case was excluded because the age did not match the study criteria. Finally, 69 cases were eligible for this study, of whom 53 underwent conventional surgery, and 16 received the C2-3 dural exposure procedure. Their mean age was 43.5 ± 13.4 (range, 18–69) years, and 75.4% of them were male. The median duration of DOC was 5.0

(range, 3–156) months. Sixteen (23.2%) patients were diagnosed with MCS based on the CRS-R score. The etiologies were divided into traumatic (30.4%), anoxic (23.2%) and vascular (46.4%). There was no significant difference between the 2 treatment groups in terms of demographics or baseline characteristics (Table 1).

3.2 Surgical and Prognosis Characteristics of the Study Population

Electrodes and pulse generators were implanted in one stage in all patients of both treatment groups. No adjustments of electrodes were performed for serious adverse reactions to stimulation or other causes. The mean operative time was 170.9 ± 8.8 min, while the median estimated blood loss was 50 (range, 10–200) mL. No surgical site infection was observed based on the 1-month post-surgical follow-up. The mean sagittal diameter of the spinal canal was 15.1 ± 1.6 mm. The median electrode height was 4.6 (range, –11.2–18.2) mm. CT follow-up showed that the midline was covered by the caudal contacts of the electrode arrays in all patients, while the cephalic contacts deviated from the midline in 25 cases. Differences were observed in the full coverage of midline between the 2 treatment groups. The complete coverage rate was 54.7% in the conventional surgery group and 93.8% in the C2-3 dural exposure group ($p = 0.004$). The deviation direction of the electrode array was toward the operating table in 16 (64%) of the 25 cases.

At the time of device programming, two weeks after surgery, 45 patients underwent EMG testing. CT scans showed that in 30 patients, the contacts at all levels fully covered the midline, 1 (3.3%) patient had EMG lateralization, while 15 patients had cephalic contacts deviated from the midline, of which all were lateralization. The average voltage at which laterality was detected was 4.5 V.

At 1 month after surgery, 23 (27.5%) patients had improved CRS-R scores, including 13 who underwent conventional surgery and 6 who underwent the C2-3 dural ex-

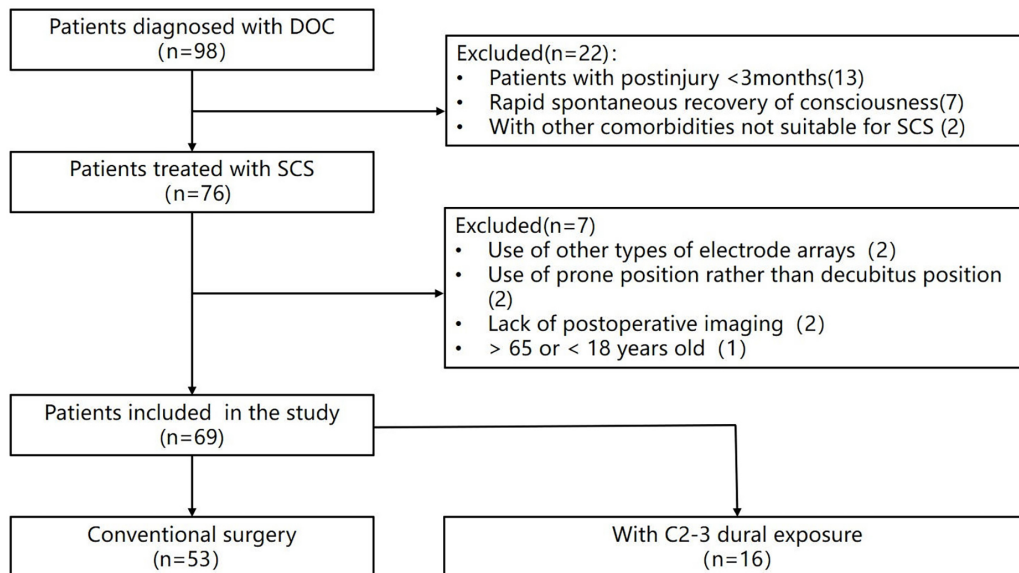


Fig. 2. The study flowchart. Abbreviations: DOC, disorders of consciousness; SCS, spinal cord stimulation.

posure procedure. One year after surgery, the GOSE scores were 4 points in 1 patient, 3 points in 14 patients, 2 points in 52 patients, and 1 point in 2 patients. No significant difference in scores was observed between the two treatment methods (Table 2).

3.3 Logistic Regression Analysis

In this study, we observed a trend towards a greater chance of deflection at higher electrode positioning. In addition, electrodes placed in vertebrae of smaller diameter seemed to be displaced due to potential resistance exerted on them. Therefore, electrode positioning, spinal diameter and surgical method were selected as regression variables. Logistic regression analysis revealed that exposure of dura between C2-3 was a significant favorable factor for complete midline coverage by the electrode array (odds ratio [OR]: 0.091; 95% confidence interval [CI]: 0.011–0.757; $p = 0.027$) (Table 3). Meanwhile, electrodes positioned ≥ 5 cm above the lower edge of the C2 vertebra was a significant risk factor for incomplete midline coverage (OR: 1.126; 95% CI: 1.016–1.248; $p = 0.023$). Other variables such as decubitus side and spinal canal sagittal diameter were not significant determinants of complete midline coverage.

4. Discussion

In this study, we proposed a C2-3 dural exposure procedure and compared its efficacy with conventional surgery. Our findings showed that although the caudal side of the electrode could be fixed in the midline, the electrode tip would still be skewed to one side in some patients, as viewed on early postoperative CT scans. These contacts that deviated from the midline would often produce a jolting stimulation corresponding to dorsal root involvement, re-

sulting in patients' discomfort and limiting the selection of program control parameters [8]. Specifically, according to the overlapping percentage of the contacts, complete midline coverage could be divided into two cases: (1) the contacts pair is either symmetrically distributed on both sides of the midline or (2) only one contact in a pair covers the midline (Fig. 3). Symmetrical stimulation is easier to achieve with the former, while the latter requires unilateral contact stimulation to ensure bilateral effects.

The proposed C2-3 dural exposure procedure was associated with a significant reduction in cephalic contact deviation (Fig. 3) and solved difficulties in programming. Compared with the traditional method of C5 laminotomy and intraoperative adjuncts, including fluoroscopy, the C2-3 dural exposure procedure has the following advantages: (1) the electrode array can be implanted under direct vision, thereby avoiding parallax and visual alignment errors during photography; (2) it is easier to separate the epidural space at the C2-3 level to adjust the electrode array if the surgeon is not satisfied with the initial placement site. Such adjustment is difficult when using the traditional method because the first attempt often forms a misguided channel within the epidural ligaments, and; (3) potential dural laceration could be avoided by dissecting the dorsal meningovertebral ligaments under direct vision.

A correlation between electrode height and complete midline coverage by the electrode array was observed in this study. The height of the electrode was calculated from the lower edge of C2 because a force of lateral slippage would often be experienced as the electrode array passes below the C2 spinous process. In the prone position, the same obstacle can be encountered. This is not attributable to pathological spinal stenosis but to the complexity of high cervical SCS [9], which can often lead to complications and

Table 2. Surgical and prognostic characteristics of the study population.

Characteristics	Conventional surgery (n = 53)	C2-3 dural exposure (n = 16)	t/ χ^2	p
Spinal canal sagittal diameter, mm				
Mean \pm SD	15.1 \pm 1.5	14.9 \pm 1.8	0.539	0.592
Range	11.1–18.8	12.7–19.3		
Electrode height, mm				
Median (range)	5.9 (–11.2 to 18.2)	2.3 (–6.5 to 10.8)	0.94	0.351
Midline complete coverage (%)	29 (54.7)	15 (93.8)	8.104	0.004*
Operating room time, min				
Mean \pm SD	170.4 \pm 8.0	172.8 \pm 11.1	0.970	0.336
Range	160–190	155–195		
Estimated blood loss, mL				
Median (range)	50 (10–200)	50 (50–150)	1.113	0.270
Surgical site infection, n				
	0	0		
1-month CRS-R improvement (%)	13 (24.5)	6 (37.5)	0.488	0.485
1-year GOSE score				
1 (%)	1 (1.9)	1 (6.2)		
2 (%)	43 (81.1)	9 (56.2)		
3 (%)	8 (15.1)	6 (37.5)		
4 (%)	1 (1.9)	0 (0)		
5–8 (%)	0 (0)	0 (0)		
GOSE score \geq 3 (%)	9 (17.0)	6 (37.5)	1.955	0.162

Abbreviations: *, statistical significance ($p < 0.05$); SD, standard deviation; CRS-R, JFK Coma Recovery Scale-Revised; GOSE, Extended Glasgow Outcome Scale.

Nine patients had a second cervical CT scan between 6 months and 2 years postoperatively, with 3 patients underwent conventional surgery and 6 patients underwent surgery with C2-3 dural exposure. No displacement, migration or breakage of the electrodes was found.

Table 3. Logistic regression analysis of risk factors for electrode array deviation from the midline.

Variables	OR (95% CI)	p
Electrode position (\geq 5 cm vs. $<$ 5 cm)	1.126 (1.016, 1.248)	0.023*
C2-3 dural exposure vs. no exposure	0.091 (0.011, 0.757)	0.027*
Spinal canal sagittal diameter (\geq 15 cm vs. $<$ 15 cm)	1.058 (0.740, 1.514)	0.756

*Indicates statistical significance ($p < 0.05$); OR, odds ratio; CI, confidence interval.

revisions of electrode placements. As upper cervical segments contribute substantially to the rotational movements of the neck, the epidural space contains intricate connections that merge and blend together [10]. Meningovertebral ligaments connecting the posterior dural sac to the ligamentum flavum or the lamina are strong and maintain the integrity of this region. Cadaver studies showed that the ligaments were high in collagenous tissues [10] and were thickest at the C1 and C2 vertebrae [11]. Our observation concurs with these findings. The issues related to epidural resistance at the C2 level could be largely resolved by implementing the C2-3 dural exposure procedure.

Our findings also showed that surgical exposure adjustments did not significantly prolong the operation time nor increase the amount of bleeding. Also, no surgical site infection was observed between the 2 treatment groups. Epidural resistance was encountered around C2, but this was physiologic rather than scarring. With the C2-3 dural exposure technique, blind exploration of the epidural can be avoided, thereby increasing safety. Despite extend-

ing the wound cephalically, there were no wound healing problems, and no significant difference was found in postoperative incision pain. Compared to techniques that require additional laminectomies in the presence of epidural resistance or adhesions [12], the proposed C2-3 dural exposure procedure was associated with less damage to bony structures and retained most muscle attachment points, especially at the C2 spinous process. This can help maintain neck stability and reduce the impact of surgery on muscle tone. Interestingly, considering that a significant proportion of patients with DOC often suffer from spasm problems, in this study, we observed a short-term relief of neck or upper limb spasms in both surgery groups. Only one patient who underwent conventional surgery developed a prolonged weakness in neck extension. The symptoms improved a lot during the subsequent six months of rehabilitation therapy.

As the patients spent more time in bed, stimulator displacement in the upright position was not of concern in this study. Hence, we preferred placing the pulse generator into

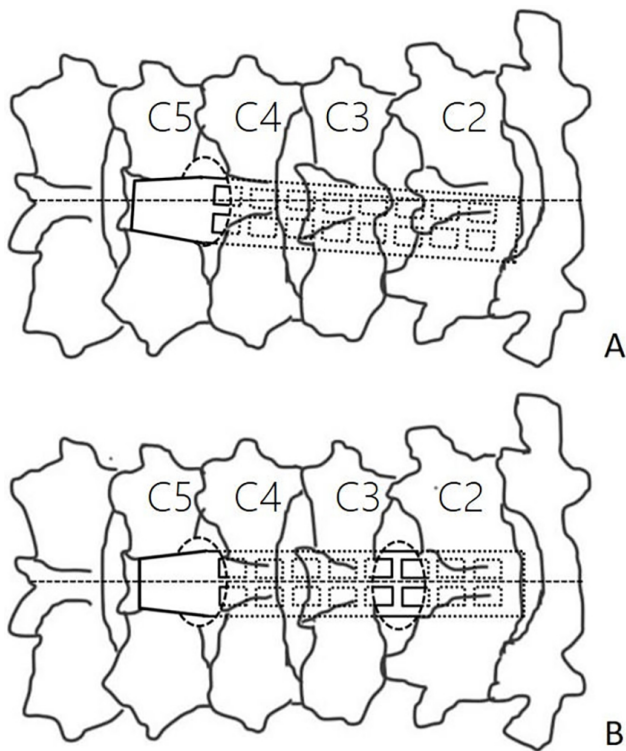


Fig. 3. Diagrammatic coronal view depicting the electrode array placement. (A) The electrode array enters the epidural space through the laminectomy level, while the cephalic contacts deviate from the midline. (B) Dural exposure between C2-3 ensures full coverage of the midline by the electrode array.

the chest wall rather than the flank or upper buttock area to reduce the length of the extension wire and potential injuries during passive turning over movements.

The lateral decubitus position was adopted in this study. This position allows a one-time skin disinfection followed by electrode implantation in the neck and pulse generator implantation in the chest wall, which can ultimately reduce the operation time and risk of infections. Another reason for choosing the lateral decubitus was to facilitate the anesthesiologist to check the tracheotomy cannula, which is not readily visible in the prone position. The neck position and operator's perspective could make the electrode deviate to the decubitus side. We, therefore, emphasize that the incision should be perpendicular to the dermatoglyph of the neck to avoid lateral flexion and torsion of the neck, and the bed should be adjusted before the operation to ensure that it is at the surgeon's eye level for incision. Thus, most deviation from the midline could be corrected with the proposed C2-3 dural exposure.

Compared to the single-column paddle, a multi-column paddle increases the coverage area and the flexibility of program control. In our previous attempts, we noted that the Medtronic Specify 2×8 was more suitable because the wider 5-6-5 paddle would encounter more resistance when passing through the epidural space at C2 and

was likely to cover the nerve roots. After electrode implantation, conventional anchoring was adopted at the end of the electrode. Some studies have proposed a non-anchored method [13]. In our cases, no postoperative displacement or electrode revision was needed, which could be associated with the lower frequency and amplitude of neck rotation in most patients with DOC.

In addition to direct observation, there are two methods for evaluating the location of the electrode array during general anesthesia. One is intraoperative imaging. Fluoroscopy is widely used to locate the spinal segment and plan the skin incision. It also allows for some minimal access to spinal technologies that can be used when the patient is conscious [12,14]. However, this requires an experienced surgeon to accurately determine intraoperative midline implants because parallax and visual alignment errors during photography cannot truly reflect the spatial relationships between the electrodes, and the spinal canal of patients with brain damage frequently has cervical lateral flexion and torsion [15]. Therefore, intraoperative CT is the preferred imaging modality. It can also accurately measure the implantation location of the electrodes.

For patients with a deviation of the spinal cord from the midline of the canal, a more desirable method of verification would be neurophysiological monitoring. This includes electromyography and somatosensory-evoked potential collision studies (SSEP-CS), which have recently been used in patients with chronic pain [16–18]. Electromyography is more sensitive and helps guide device programming [16–18]. SSEP-CS is safe for the intraoperative monitoring of midline placement of C1-2 paddle leads [19]. The common unilateral brain insufficiency in the patients of this study cohort required caution if SSEP-CS was to be used as an indicator of laterality. Thus, electromyography was preferred for intraoperative monitoring and device programming. C2-3 dural exposure facilitated the adjustment of electrodes according to neurophysiological monitoring. Two weeks after surgery, EMG was used to assess the efficacy of midline coverage, as determined by CT. The electrophysiological results matched with the imaging results, showing no obvious electrode displacement during this time interval.

GOSE was used to assess the long-term recovery of consciousness in this study. Under this scoring system, a score greater than 3 refers to full recovery of consciousness, while a score greater than 4 refers to partial recovery of self-care. Although there was a significant difference in midline coverage between the 2 treatment groups, no significant difference in conscious outcome was observed. There are many prognostic factors for consciousness disorder, including etiology, preoperative consciousness level and others. Long-term prognosis is closely related to the nursing level after discharge. Larger sample sizes may yield more reliable results. Thus, there are ample reasons to necessitate improved midline coverage based on current outcomes.

One limitation of this study is that electromyography was performed on only 45 patients at the device programming stage. Therefore, we could not demonstrate the advantages of the C2-3 exposure procedure in terms of electrophysiological monitoring. Another limitation is that the lack of a sufficient number of long-term CT reviews of the electrodes to understand the incidence of long-term electrode displacement, which warrants further research in the future.

5. Conclusions

This study showed that the proposed C2-4 spinal cord stimulator implantation in patients with DOC under general anesthesia could achieve high midline coverage by: (1) using the lateral decubitus position, (2) exposing the dura between C2-3 to ensure that the electrode array proceeds upwards along the midline, and (3) ensuring that the electrode tip is not too far above the C2 level. These enabled the proposed C2-3 exposure procedure to have lower rates of midline deviation. We hypothesize that this could contribute to easy device programming and reliable efficacy evaluation.

Author Contributions

YD, JH and JZ contributed to the study conception and design. YD, XX, YY, RH, JH, JZ collected the data and performed the data analysis. All authors contributed to the interpretation of the data and the completion of figures and tables. All authors contributed to the drafting of the article and final approval of the submitted version.

Ethics Approval and Consent to Participate

The study protocol was approved by the Ethics Committee of the Seventh Medical Center of the PLA General Hospital (approval number: 2018-58). The data of all patients were anonymized, and no additional patient consent was required due to the retrospective nature of the study.

Acknowledgment

Not applicable.

Funding

This research received no external funding.

Conflict of Interest

The authors declare no conflict of interest.

References

- [1] Georgiopoulos M, Katsakiori P, Kefalopoulou Z, Ellul J, Chroni E, Constantoyannis C. Vegetative state and minimally conscious state: a review of the therapeutic interventions. *Stereotactic and Functional Neurosurgery*. 2010; 88: 199–207.
- [2] Della Pepa GM, Fukaya C, La Rocca G, Zhong J, Visocchi M. Neuromodulation of vegetative state through spinal cord stimulation: where are we now and where are we going? *Stereotactic and Functional Neurosurgery*. 2013; 91: 275–287.
- [3] Guerra A, Costantini EM, Maatta S, Ponzo D, Ferreri F. Disorders of consciousness and electrophysiological treatment strategies: a review of the literature and new perspectives. *Current Pharmaceutical Design*. 2014; 20: 4248–4267.
- [4] Yamamoto T, Katayama Y, Obuchi T, Kobayashi K, Oshima H, Fukaya C. Deep brain stimulation and spinal cord stimulation for vegetative state and minimally conscious state. *World Neurosurgery*. 2013; 80: S30.e1–S30.e9.
- [5] Wang Y, Bai Y, Xia X, Yang Y, He J, Li X. Spinal cord stimulation modulates complexity of neural activities in patients with disorders of consciousness. *The International Journal of Neuroscience*. 2020; 130: 662–670.
- [6] Kanno T, Morita I, Yamaguchi S, Yokoyama T, Kamei Y, Anil SM, *et al.* Dorsal column stimulation in persistent vegetative state. *Neuromodulation: Journal of the International Neuromodulation Society*. 2009; 12: 33–38.
- [7] Giacino JT. The vegetative and minimally conscious states: consensus-based criteria for establishing diagnosis and prognosis. *NeuroRehabilitation*. 2004; 19: 293–298.
- [8] Delmotte A, Jacques L, Kumar K, Poon K, Monlezun O, Roulaud M, *et al.* The Franco-Canadian multicolumn spinal cord stimulation prospective study: a subgroup analysis focusing on the decisive role of lead positioning. *Neuro-Chirurgie*. 2015; 61: S83–S89.
- [9] Penn DL, Zussman BM, Wu C, Sharan AD. Anterograde revision of cervical spinal cord stimulator paddle electrode: a case report. *Neuromodulation: Journal of the International Neuromodulation Society*. 2012; 15: 581–585.
- [10] Sillevs R, Hogg R. Anatomy and clinical relevance of sub occipital soft tissue connections with the dura mater in the upper cervical spine. *PeerJ*. 2020; 8: e9716.
- [11] Shi B, Zheng X, Min S, Zhou Z, Ding Z, Jin A. The morphology and clinical significance of the dorsal meningovertebra ligaments in the cervical epidural space. *The Spine Journal: Official Journal of the North American Spine Society*. 2014; 14: 2733–2739.
- [12] Pabaney AH, Robin AM, Schwalb JM. New technique for open placement of paddle-type spinal cord stimulator electrode in presence of epidural scar tissue. *Neuromodulation: Journal of the International Neuromodulation Society*. 2014; 17: 759–762.
- [13] Pahapill PA. A Novel Nonanchoring Technique for Implantation of Paddle Leads in the Cervical Spine Under Conscious Sedation. *Neuromodulation: Journal of the International Neuromodulation Society*. 2015; 18: 472–6; discussion 476–7.
- [14] Rigoard P, Luong AT, Delmotte A, Raaholt M, Roulaud M, Monlezun O, *et al.* Multicolumn spinal cord stimulation lead implantation using an optic transligamentar minimally invasive technique. *Neurosurgery*. 2013; 73: 550–553.
- [15] Shils JL, Arle JE. Neuromonitoring for Spinal Cord Stimulation Lead Placement Under General Anesthesia. *Journal of Clinical Neurology (Seoul, Korea)*. 2018; 14: 444–453.
- [16] Roth SG, Lange S, Haller J, De La Cruz P, Kumar V, Willock M, *et al.* A Prospective Study of the Intra- and Postoperative Efficacy of Intraoperative Neuromonitoring in Spinal Cord Stimulation. *Stereotactic and Functional Neurosurgery*. 2015; 93: 348–354.
- [17] Collison C, Prusik J, Panicioli S, Briotte M, Grey R, Feustel P, *et al.* Prospective Study of the Use of Intraoperative Neuromonitoring in Determining Post-Operative Energy Requirements and Physiologic Midline in Spinal Cord Stimulation. *Neuromodulation: Journal of the International Neuromodulation Society*. 2017; 20: 575–581.
- [18] Schoen N, Chieng LO, Madhavan K, Jermakowicz WJ, Vanni S. The Use of Intraoperative Electromyogram During Spinal Cord Stimulator Placement Surgery: A Case Series. *World Neurosurgery*. 2017; 100: 74–84.
- [19] Muncie LM, Ellens NR, Tolod-Kemp E, Feler CA, Winestone JS. Intraoperative electrophysiological monitoring for C1-2 spinal cord stimulation. *Journal of Neurosurgery: Spine*. 2017; 26: 183–189.